



Repeat single-fraction stereotactic radiosurgery for recurrent vestibular schwannoma

Cooper T. Rapp¹, Robert J. Amdur¹, Frank J. Bova², Kelly D. Foote², William A. Friedman²

¹Department of Radiation Oncology, University of Florida College of Medicine, Gainesville, FL, United States

²Department of Neurosurgery, University of Florida College of Medicine, Gainesville, FL, United States

ABSTRACT

Background: Data are scarce on the efficacy of a second radiosurgery (SRS) treatment of vestibular schwannoma that has progressed following initial treatment with SRS. We sought to report the outcome of our repeat SRS series with long-term imaging follow-up.

Materials and methods: We retrospectively analyzed 6 patients who met the following criteria: Repeat SRS at our institution between 1995 and 2018; solitary unilateral tumor; no evidence of neurofibromatosis; and magnetic resonance (MR) planning for both SRS treatments. All treatments were delivered with a linear accelerator-based system using head frame immobilization. The prescribed dose to the periphery of the tumor was 12.5 Gy in all initial and repeat SRS treatments, except for one repeat treatment to 10 Gy.

Results: Follow-up with MR scan following the second SRS treatment was a median 8.4 years. The tumor control rate (lack of progression) following the second SRS treatment was 83% (5/6). Actuarial 10-year outcomes following repeat SRS were: tumor control, 80%; absolute survival, 80%; and cause-specific survival, 100%. Of the patients with at least minimal hearing retention before initial SRS, none had ipsilateral hearing preservation after initial radiation treatment. Improvement in any pretreatment cranial nerve deficits was not seen. The only permanent grade ≥ 3 toxicity from repeat SRS was a case of infra-orbital nerve deficit. No patient developed a stroke, malignant transformation, induced second tumor, or facial nerve deficit.

Conclusion: There was excellent overall survival, tumor control, and low morbidity in our series for recurrent vestibular schwannoma submitted to repeat single-fraction SRS, supporting additional studies of this treatment strategy.

Key words: vestibular schwannoma; radiosurgery; recurrence

Rep Pract Oncol Radiother 2022;27(4):655–658

Introduction

Many series report excellent results treating vestibular schwannomas with single-treatment stereotactic radiotherapy (SRS) [1]. In the 5–10% of cases in which the tumor progresses in the years following SRS, the main treatment options are

surgical resection, fractionated radiotherapy, or repeat SRS. Data on the efficacy of repeat SRS are limited by small patient numbers, suboptimal follow-up, and heterogeneous treatment techniques. Our program has now treated a select group of recurrent vestibular schwannoma cases with a second SRS treatment using a standard-

Address for correspondence: Robert J. Amdur, MD; Department of Radiation Oncology, University of Florida College of Medicine; 2000 SW Archer Road, PO Box 100385, Gainesville, FL 32610-0385, tel: (352) 265-0287, fax: (352) 265-7045; e-mail: amdurr@shands.ufl.edu

This article is available in open access under Creative Common Attribution-Non-Commercial-No Derivatives 4.0 International (CC BY-NC-ND 4.0) license, allowing to download articles and share them with others as long as they credit the authors and the publisher, but without permission to change them in any way or use them commercially

ized treatment technique and dose prescription. We have multi-year follow-up with magnetic resonance (MR) imaging on all cases. The purpose of this paper is to contribute to the literature by reporting tumor outcome and major complications in our repeat SRS series.

Materials and methods

Patient characteristics

This retrospective outcome analysis was approved by our institution's institutional review board (IRB201903112). We identified 6 patients treated between 1995 and 2018 who met the following inclusion criteria: radiographic or histologic diagnosis of unilateral vestibular schwannoma; initial treatment with single-fraction SRS at our institution; progressive enlargement following initial SRS treatment of the primary tumor on multiple sequential MR scans leading to the unanimous conclusion by all members of our treatment team that the patient had recurrent tumor; treatment for progressing tumor with repeat single-fraction SRS at our institution; and MR-based treatment planning for both SRS treatments. We excluded patients with bilateral disease at presentation, and those who had been diagnosed with neurofibromatosis type 2. We did not exclude patients who had undergone subtotal surgical resection prior to receiving their first SRS treatment. No patient underwent resection between the first and second SRS treatments. Table 1 summarizes the main characteristics of our study population.

Dosimetry

In our program, brain SRS is delivered with a linear accelerator-based system, as described previously [2]. Treatment planning begins with clinical evaluation and MR scanning the day before SRS is delivered. A head ring is placed on the patient while under local anesthesia, and a planning computed tomography (CT) scan is obtained. The previously obtained MR scan is fused with this CT scan, and dosimetry planning is performed. The dose is prescribed to the 70% or 80% isodose line with a sphere-packing technique. Table 2 summarizes major characteristics related to the tumors and dosimetry.

Table 1. Patient and treatment characteristics (n = 6)

Characteristic	No. of patients or other value
Sex, female	6 (100%)
Age at first SRS, median years (range)	63 (51 to 70)
Surgery prior to first SRS	
No	4 (67%)
Subtotal resection	1 (17%)
Gross total resection	1 (17%)
Indication for first SRS	
Patient preference	5 (83%)
Medical risk of surgery	1 (17%)
Time to second SRS, median years (range)	4.2 (2.2 to 8.7)
Surgery prior to second SRS	
No	6 (100%)
Subtotal resection	0
Gross total resection	0
Indication for second SRS treatment	
Patient preference	5 (83%)
Medical risk of surgery	1 (17%)
Salvage surgery after second SRS	
No	5 (83%)
Gross total resection	1 (17%)

SRS — stereotactic radiosurgery

Outcome evaluation

Follow-up consisted of clinical evaluation and MR scan. Tumor control was defined as no size increase on serial MR scans. Toxicity was graded with version 5.0 of the Common Terminology Criteria for Adverse Events (CTCAE v5). We did not attempt to record all grade 1-2 toxicities due to the retrospective nature of our analysis. The toxicity outcome in this study is toxicity from the second SRS treatment. We were unable to evaluate hearing loss related to the second SRS treatment because we did not perform audiometry after SRS and because almost all patients had poor hearing in the ipsilateral ear prior to the second SRS treatment.

JMP software was utilized for statistical analyses (SAS Institute, Cary, NC). The Kaplan-Meier product limit method provided actuarial outcome estimates. Endpoints for the actuarial plots were as follows: Tumor progression for the tumor control plot; death from any cause for the overall survival plot; and death from vestibular schwannoma or from SRS for the cause-specific survival plot.

Table 2. Tumor characteristics and dosimetry details (n = 6)

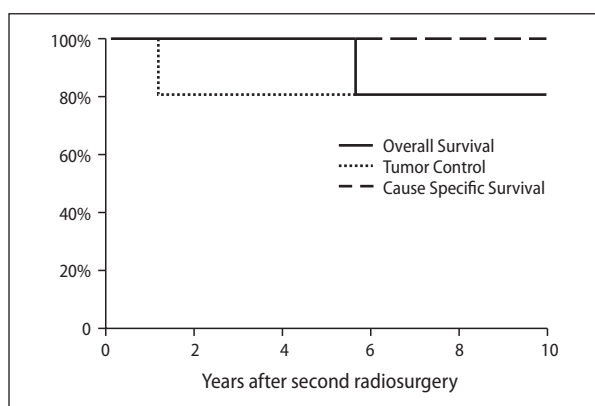
Characteristics	First SRS	Second SRS
Tumor volume, median (range)	1.9 cm ³ (0.8–3.9 cm ³)	3.8 cm ³ (2.2–8.0 cm ³)
Tumor volume in CPA, median (range)	1.6 cm ³ (0.3–3.4 cm ³)	3.5 cm ³ (1.5–7.3 cm ³)
Brain stem touching distance, median (range)	6.7 mm (0–11 mm)	15 mm (8–25 mm)
Brain stem compression	0.3 mm (0–2 mm)	2.8 mm (0–6 mm)
Koos grade		
I	0	0
II	1	0
III	4	2
IV	1	4
Target doses		
Prescribed dose	12.5 Gy	12.5 Gy in 5 pts and 10.0 Gy in 1 pt
% of tumor receiving the prescription dose, median (range)	91% (84–95%)	89% (80–99%)
Normal structure doses		
Brainstem 0.03 cm ³ maximum, median (range)	11.4 Gy (6.0–13.4 Gy)	12.6 Gy (11.5–13.8 Gy)
Cochlea mean dose, median (range)	7.5 Gy (0.2–13.7 Gy)	7.0 Gy (0.3–11.8 Gy)
Vestibular mean dose, median (range)	4.9 Gy (0.2–7.9 Gy)	6.0 Gy (0.3–10.2 Gy)

CPA — cerebellopontine angle; pt — patient

Results

Tumor control and survival

Figure 1 shows actuarial plots of outcome. The median follow-up since completion of the second SRS is 8.4 years (range, 1.7–10.8 years). No patients were lost to follow-up. Only one patient demonstrated progression after the second SRS treatment. This patient progressed 1.1 years following second SRS and survived an additional 9.7 years after salvage surgery without a tumor recurrence. All but 1 patient was alive at last follow-up.

**Figure 1.** Survival outcomes at 10 years

The deceased patient died of medical problems unrelated to vestibular schwannoma or SRS 5.4 years after repeat SRS.

Toxicity related to the second SRS treatment

Following repeat SRS, 1 patient developed a permanent deficit of V-2 (CTCAE v5 grade 2) and another required a ventriculoperitoneal shunt (CTCAE v5 grade 4). No patient developed a cranial nerve VII deficit, symptomatic temporal bone necrosis, malignant transformation of their vestibular schwannoma, a second tumor related to SRS, or stroke related to SRS.

Discussion

Tables S1 and S2 (Supplementary File) summarize published series that report outcomes after repeat SRS for vestibular schwannoma [3–7]. Our series is the smallest but has the most uniform study population, most standardized treatment technique, and the most reliable follow-up. These series support the conclusion that repeat SRS is highly effective at stopping tumor growth and that the serious complication rate is low. It is not possible to make persuasive comparisons be-

tween studies due to heterogeneity in study populations and the details of SRS.

There are major limitations to all reported series, including our own. The main limitation is small patient numbers, and longer follow-up is always desirable. It is important to emphasize that none of the patients in our series had new mass effect symptoms from progression of tumor between SRS treatments.

Conclusion

There was excellent overall survival, tumor control, and low morbidity in our series for recurrent vestibular schwannoma submitted to repeat single-fraction SRS, supporting additional studies of this treatment strategy.

Conflict of interest

The authors have no conflicts of interest to declare.

Funding

This research did not receive any specific grant from funding agencies in the public, commercial, or not-for-profit sectors.

Statement of ethics

All subjects gave their written informed consent and this study protocol was approved by the University of Florida's Institutional Review Board (IRB 201903112).

Author contributions

C.T.R. — formal analysis; investigation, data curation, writing — original draft; writing — review

and editing; R.J.A. — conceptualization; methodology; validation, writing — original draft; writing — review and editing; supervision; F.J.B. — investigation; resources, writing — review and editing; K.D.F. — investigation; resources; writing — review and editing; W.A.F. — investigation; resources; writing — review and editing

References

1. Johnson S, Kano H, Faramand A, et al. Long term results of primary radiosurgery for vestibular schwannomas. *J Neurooncol.* 2019; 145(2): 247–255, doi: [10.1007/s11060-019-03290-0](https://doi.org/10.1007/s11060-019-03290-0), indexed in Pubmed: [31535315](https://pubmed.ncbi.nlm.nih.gov/31535315/).
2. Friedman WA, Bova FJ. The University of Florida radiosurgery system. *Surg Neurol.* 1989; 32(5): 334–342, doi: [10.1016/0090-3019\(89\)90135-3](https://doi.org/10.1016/0090-3019(89)90135-3), indexed in Pubmed: [2683164](https://pubmed.ncbi.nlm.nih.gov/2683164/).
3. Dewan S, Norén G. Retreatment of vestibular schwannomas with Gamma Knife surgery. *J Neurosurg.* 2008; 109 Suppl: 144–148, doi: [10.3171/JNS/2008/109/12/S22](https://doi.org/10.3171/JNS/2008/109/12/S22), indexed in Pubmed: [19123901](https://pubmed.ncbi.nlm.nih.gov/19123901/).
4. Yomo S, Arkha Y, Delsanti C, et al. Repeat gamma knife surgery for regrowth of vestibular schwannomas. *Neurosurgery.* 2009; 64(1): 48–54; discussion 54, doi: [10.1227/01.NEU.0000327692.74477.D5](https://doi.org/10.1227/01.NEU.0000327692.74477.D5), indexed in Pubmed: [19050660](https://pubmed.ncbi.nlm.nih.gov/19050660/).
5. Lonneville S, Delbrouck C, Renier C, et al. Repeat Gamma Knife surgery for vestibular schwannomas. *Surg Neurol Int.* 2015; 6: 153, doi: [10.4103/2152-7806.166173](https://doi.org/10.4103/2152-7806.166173), indexed in Pubmed: [26500799](https://pubmed.ncbi.nlm.nih.gov/26500799/).
6. Fu VX, Verheul JB, Beute GN, et al. Retreatment of vestibular schwannoma with Gamma Knife radiosurgery: clinical outcome, tumor control, and review of literature. *J Neurosurg.* 2018; 129(1): 137–145, doi: [10.3171/2017.3.JNS162033](https://doi.org/10.3171/2017.3.JNS162033), indexed in Pubmed: [28984523](https://pubmed.ncbi.nlm.nih.gov/28984523/).
7. Iorio-Morin C, Liscak R, Vladyka V, et al. Repeat Stereotactic Radiosurgery for Progressive or Recurrent Vestibular Schwannomas. *Neurosurgery.* 2019; 85(4): 535–542, doi: [10.1093/neuros/nyy416](https://doi.org/10.1093/neuros/nyy416), indexed in Pubmed: [30189018](https://pubmed.ncbi.nlm.nih.gov/30189018/).