



# The effect of fractionated gamma knife radiosurgery on visual acuity in patients with optic nerve tumor

Farid Kazemi<sup>1,2</sup>, Mazyar Azar<sup>1,2</sup>, Foad Kazemi<sup>1</sup>, Tahereh Hadisinia<sup>3</sup>, Javad Teymori<sup>2</sup>, Ghazale Geraily<sup>2,3</sup>

<sup>1</sup>Skull Base Research Center, Neurosurgery Department, Iran University of Medical Science, Tehran, Iran

<sup>2</sup>Iran Gamma Knife Center, Tehran, Iran

<sup>3</sup>Medical Physics Department, Tehran University of Medical Sciences, Tehran, Iran

## ABSTRACT

**Background:** Stereotactic radiosurgery (SRS) method has been considered the first-line treatment option to treat patients involved with pre-optic nerve tumors. However, studies have shown that using fractionated SRS, normal tissue sparing and tumor dose can be strongly increased simultaneously. Our main goal was to illustrate the effects of fractionated SRS approach in optic nerve tumor treatment and its adjacent sensitive structures.

**Materials and methods:** 19 patients involved in optic nerve tumor with clinical symptoms of vision loss were treated with Gamma Knife radiosurgery in three sessions with 12 hours intervals between them. The prescribed dose was about  $6.0 \pm 1.2$  Gy. Patient-related parameters including pre-treatment and after-treatment tumor size, visual acuity and visual field were evaluated using the Snell chart and MRI imaging. Patients were followed for about 14 months.

**Result:** The overall result showed vision improvement for patients with low and moderate visual loss. However, there was no significant improvement in patients with severe visual loss. Relative improvement was observed in blind patients, although poorly. There was no evidence of growth, recurrence, or new tumor after treatment in patients.

**Conclusion:** Fractionated gamma knife radiosurgery offers a safe and effective alternative for benign lesions adjacent to the optic nerve.

**Key words:** fractionation; gamma knife radiosurgery; optic nerve tumors; stereotactic techniques

*Rep Pract Oncol Radiother 2021;26(6):915–919*

## Introduction

Several studies have shown that despite the benignity of the peri-optic nerve tumors, they can be problematic if placed near sensitive structures such as the cranial nerves. The current methods for these tumors include observation, surgery, and radiation therapy techniques. Although complete surgical resection is the best option in most patients, it may bring a high degree of risk of morbidity or mortality [1, 2].

When patients cannot undergo surgery, radiation therapy or stereotactic radiosurgery (SRS) can be considered as an alternative for primary treatment modality. SRS, which can be performed using Linac, Cyberknife, and gamma knife (GK), is preferred for small lesions and is usually performed in a single session compared to conventional radiation therapy. An excellent tumor control rate and significant treatment efficacy have been reported for many intracranial tumors treated by radiosurgery [1–3]. Gamma knife radiosurgery (GKRS) is superi-

**Address for correspondence:** Ghazale Geraily, Medical physics Department, Tehran University of Medical Science, Tehran, Iran, Iran Gamma Knife Center, Tehran, Iran, tel: +989124308726; e-mail: gh-geraily@sina.tums.ac.ir

This article is available in open access under Creative Common Attribution-Non-Commercial-No Derivatives 4.0 International (CC BY-NC-ND 4.0) license, allowing to download articles and share them with others as long as they credit the authors and the publisher, but without permission to change them in any way or use them commercially

or to other SRS methods in steep dose gradients and high-dose conformity, which is essential for excellent target coverage and vital structure sparing [4].

For years, GKRS has been considered a single session treatment but delivered dose to the more extensive lesions can be limited mainly for tumors adjacent to sensitive structures such as optic nerve tumors. Furthermore, the marginal dose needs to be reduced while treating large volume lesions to reduce complications to the surrounding brain parenchyma. To overcome this problem, fractionated GKRS was proposed in which the benefits of GKRS are combined with fractionation. Fractionated SRS has been infrequently described with Cyberknife and linac but not with GKRS [4–6].

Some indications for treatment with fractionated GKRS include benign peri-optic nerve tumors, tumors 10 cc in volume, and re-irradiation of tumors previously treated with SRS [7, 8]. Using fractionated GKRS, the therapeutic benefit was increased, and complications were reduced; simultaneously [1, 3]. On the other hand, in GKRS dose inhomogeneity can be obtained so that the received dose to the central portion of the tumor is twice as high as that of the periphery of the tumor. This intrinsic property and the sensitive structures sparing that exist in the fractionated GKRS improve the quality of the treatment outcomes [7, 9].

In this study, we reported our experience for fractionated GKRS with equal dose sessions and patients with peri-optic nerve benign tumor concerning significant improvement in vision and considerable reduction in complications of single fractionated GKS

## Materials and methods

The examined group consisted of 19 patients with optic nerve tumor who underwent radiosurgery treatment with a Leksell Gamma knife model 4C (Elekta Instruments, Stockholm, Sweden) during the period from the beginning of the year 2011 to the end of the year 2013.

For all patients, the size and anatomical location of the tumor, primary diagnosis, and pre-treatment visual acuity and visual field were evaluated using MRI imaging. Patient characteristics are summarized in Table 1. The patients' consent was obtained for all patients. Pre-GKRS complete ophthalmic examinations using the standard Snellen chart in

**Table 1.** Patient characteristics

No. of patients	19
Age, mean (range)	48.5 (36–60)
<b>Sex, n (%)</b>	
Male	2 (10.52)
Female	17 (89.48)
<b>Tumor, n (%)</b>	
Benign	19 (100)
Malignant	0 (0)
<b>Tumor histology, n (%)</b>	
Meningioma	17(89.5)
Glioma	1 (5.3)
Chordoma	1 (5.3)
<b>Dose/fraction, benign tumor, n (%)</b>	
First session	5.7 ± 0.99
Second session	5.8 ± 1.1
Third session	6.0 ± 1.2

18 patients showed decreased visual acuity in comparison with healthy patients due to the tumor so that six patients had decreased visual acuity in the right eye (31%), eight patients had decreased visual acuity in the left eye (42%). In 4 patients, visual acuity was decreased in both eyes (21%).

Before treatment, under local anesthesia, the stereotactic G-frame was placed on the patient's head and used as a reference frame for all treatment procedures. The frame remained on the patient's head until the end of the irradiation sessions. Then T1-weighted MR imaging was performed with gadolinium enhancement and fiducial BOX markers mounted on the frame [10].

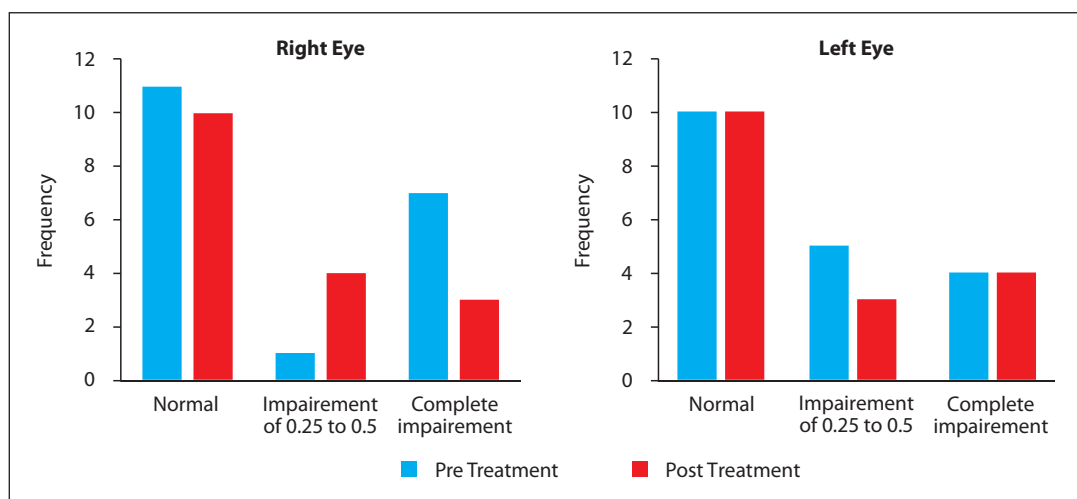
The tumor contouring was estimated using the MRI obtained images, and the radiation dose required for each patient was delivered to the tumor during three sessions with 12-hour intervals between sessions. The average amount of radiation emitted to patients was about  $6.0 \pm 1.2$  Gy. The isodose values, the percentage of tumor coverage, and the minimum and maximum integral dose of patients are presented in Table 2. The  $\chi^2$  test was used to analyze and determine the relationship between the dose rate of the radiation used and the type of tumor. Also, the significance level in this study was considered as 0.05.

## Results

Patients with a mean time of  $14.8 \pm 8.7$  months (6 to 32 months) were followed up. At the end of

**Table 2.** Details of delivered dose to the patients for each treatment sessions

	Minimum [Gy]	Maximum [Gy]	Mean [Gy]	Standard deviation
Integral dose	12	27	17.6	3.2
Isodose in first session	50%	70%	59%	7.7
Isodose in second session	50%	72%	60.8%	7.6
Isodose in third session	50%	72%	60.6%	7.5
Percentage tumor coverage in first session	95	100	98.9	0.7
Percentage tumor coverage in second session	97	100	99.0	0.7
Percentage tumor coverage in third session	97	100	99.1	0.7



**Figure 1.** Patients' visual field for left and right eye before and after treatment with gamma knife

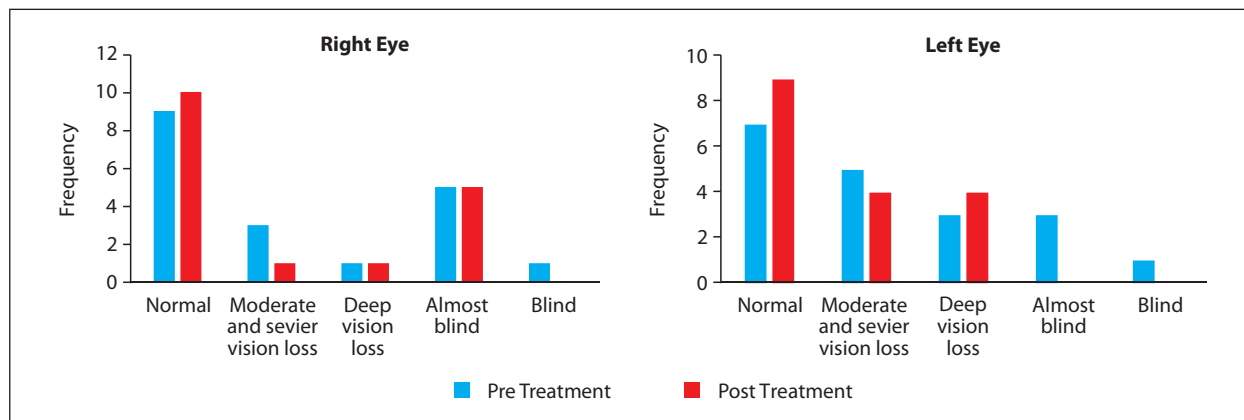
the follow-up period, the patient's visual acuity and visual field were measured again using the Snell chart for the left and right eye separately. Because the results of the Snell Schedule examination contain qualitative and quantitative information, for the sake of simplicity, in statistical computations, the visual acuity of patients was compared with the standard vision data of American drivers provided by the American Association of Ophthalmologists. The results are presented in Figures 1 and 2.

Because two patients were not available for after-treatment tests, post-treatment information was reported just for 17 patients. In all patients, the reduction in tumor size was seen after the gamma-knife based on MRI findings (Fig. 3). There was no evidence of growth, recurrence, or new tumor after treatment in patients and all were alive during the follow-up time.

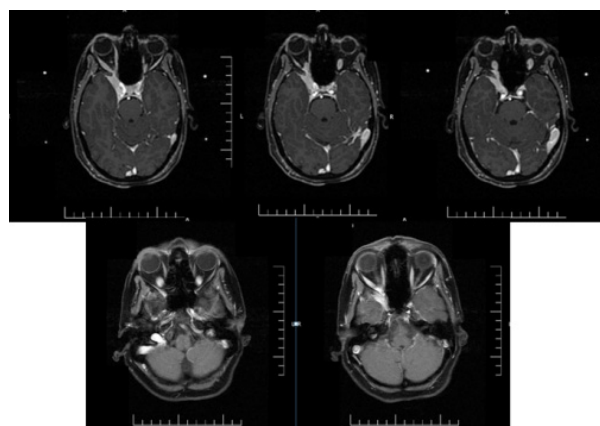
## Discussion

Skull base meningiomas are often adjacent to neurological and sensitive vascular structures. For this reason, complete resection of these tumors is not possible or at least very difficult. Advancement in treatment technology and the early detection of tumors enable diagnosis of patients with early clinical symptoms. GKSR can be helpful, but a high delivered dose in just one session can be problematic due to the risk of damaging the optic nerve. This issue becomes more critical when it is related to the patient's vision. So, using fractionated SRS, we have the advantages of conventional fractionated radiotherapy and single-session radiosurgery simultaneously.

The statistical study of our data showed a correlation between post-treatment visual acuity of the right eye with the integral dose of patients



**Figure 2.** Patients' visual acuity for left and right eye before and after treatment with gamma knife



**Figure 3.** A 35-year-old woman with progressive left eye loss of vision due to meningeoma before (upper images) and after fractionated GKSR treatment (lower images)

(p-value = 0.011) and between total visual acuity changes with integral dose (p-value = 0.004). However, despite increasing visual acuity of the left eye of the patients after treatment, there was no significant correlation between integral dose with the visual field of the patients and the visual acuity of the left eye. This lack of correlation can be due to the small size of the statistical population or the greater involvement of the right eye in the studied population.

According to previous studies performed by Shihan et al. 2012, the integral dose is one of the practical factors of the treatment outcome. Therefore, this fact was investigated using an independent t-test that showed the correlation between integral dose and visual acuity of each eye after treatment. This correlation illustrated that the higher the integral dose, the greater the visual acuity after treatment,

which indicates the importance of the delivered dose in the treatment [11].

In the fractionated GKRS using average doses delivered to the tumor, the total received dose of the tumor increases as compared to conventional methods and single GKRS without increased normal tissue toxicity. According to the results, increased tumor dose directly affects the improvement of visual acuity.

Fractionated GKRS has been used to treat some other tumors, including brain metastases, but there are limited studies concerning optic nerve tumors. In 2014, Tae Keun Jee et al. had studied fractionated GKSR for benign peri-optic tumors in four sessions with the same fractions and a median cumulative dose of 20 Gy [1]. Gokhan Kurt et al. in 2010 performed the fractionation GKSR with three sessions with the same dose and a 24-hour interval. The total delivered dose was about 18.6 Gy [7]. However, in our work, treatment was done in three sessions (12 h interval) with less received dose to the sensitive structures.

According to the observations, there is no evidence of neurological complications associated with treatment in follow-up intervals. Therefore, it can be concluded that this method leads to increased tumor dose (up to 18 Gy) as compared with the single GKRS (12–15 Gy) method and helps maintain vision. Our study is in good agreement with the mentioned studies in terms of improved vision and local tumor control. Although some studies have confirmed that less than 8 Gy dose to the optic nerve and chiasm is safe, the exact safe dose to the optic nerve is still unknown [7]. So, the optimal dose determination for fractions remains uncertain and requires further studies with

a larger statistical population and longer follow-up for other normal tissue side effect reduction using unequal dose per session technique.

## Conclusion

Fractionated GKRS is feasible for peri-optic nerve tumors with acceptable toxicity to the normal tissue. Our study showed that there is a correlation between integral dose and after-treatment visual acuity. So, fractionated GKRS increases the total received dose of the tumor as compared to conventional methods and single GKRS without increased normal tissue toxicity, which leads to more effective treatment outputs. The outcome at three years is promising. The long-term outcome of these patients will require further follow-up.

## Conflict of interest

None declared.

## Funding

None declared

## References

- Jee TK, Seol HoJ, Im YS, et al. Fractionated gamma knife radiosurgery for benign perioptic tumors: outcomes of 38 patients in a single institute. *Brain Tumor Res Treat.* 2014; 2(2): 56–61, doi: [10.14791/btrt.2014.2.2.56](https://doi.org/10.14791/btrt.2014.2.2.56), indexed in Pubmed: [25408926](https://pubmed.ncbi.nlm.nih.gov/25408926/).
- Eldebawy E, Mousa A, Reda W, et al. Stereotactic radiosurgery and radiotherapy in benign intracranial meningioma. *J Egypt Natl Canc Inst.* 2011; 23(3): 89–93, doi: [10.1016/j.jnci.2011.09.006](https://doi.org/10.1016/j.jnci.2011.09.006), indexed in Pubmed: [22776812](https://pubmed.ncbi.nlm.nih.gov/22776812/).
- Mukherjee KK, Kumar N, Tripathi M, et al. Dose fractionated gamma knife radiosurgery for large arteriovenous malformations on daily or alternate day schedule outside the linear quadratic model: Proof of concept and early results. A substitute to volume fractionation. *Neurol India.* 2017; 65(4): 826–835, doi: [10.4103/neuroindia.NI\\_220\\_17](https://doi.org/10.4103/neuroindia.NI_220_17), indexed in Pubmed: [28681759](https://pubmed.ncbi.nlm.nih.gov/28681759/).
- McTyre E, Helis CA, Farris M, et al. Emerging Indications for Fractionated Gamma Knife Radiosurgery. *Neurosurgery.* 2017; 80(2): 210–216, doi: [10.1227/NEU.0000000000001227](https://doi.org/10.1227/NEU.0000000000001227), indexed in Pubmed: [28536486](https://pubmed.ncbi.nlm.nih.gov/28536486/).
- Young RF. The role of the gamma knife in the treatment of malignant primary and metastatic brain tumors. *CA Cancer J Clin.* 1998; 48(3): 177–188, doi: [10.3322/canjclin.48.3.177](https://doi.org/10.3322/canjclin.48.3.177), indexed in Pubmed: [9594920](https://pubmed.ncbi.nlm.nih.gov/9594920/).
- Kim JW, Park HR, Lee JM, et al. Fractionated Stereotactic Gamma Knife Radiosurgery for Large Brain Metastases: A Retrospective, Single Center Study. *PLoS One.* 2016; 11(9): e0163304, doi: [10.1371/journal.pone.0163304](https://doi.org/10.1371/journal.pone.0163304), indexed in Pubmed: [27661613](https://pubmed.ncbi.nlm.nih.gov/27661613/).
- Kurt G, Tonge M, Börcek AO, et al. Fractionated gamma knife radiosurgery for optic nerve tumors: a technical report. *Turk Neurosurg.* 2010; 20(2): 241–246, doi: [10.5137/1019-5149.JTN.1681-09.3](https://doi.org/10.5137/1019-5149.JTN.1681-09.3), indexed in Pubmed: [20401852](https://pubmed.ncbi.nlm.nih.gov/20401852/).
- Bisht R, Kale S, Nathanasabapathi G. Preliminary experience of fractionated stereotactic radiosurgery with extend system of Gamma Knife. *Int J Cancer Ther Oncol.* 2016; 4(1): 4114, doi: [10.14319/ijcto.41.14](https://doi.org/10.14319/ijcto.41.14).
- Liu L, Bassano DA, Prasad SC, et al. The linear-quadratic model and fractionated stereotactic radiotherapy. *Int J Radiat Oncol Biol Phys.* 2003; 57(3): 827–832, doi: [10.1016/s0360-3016\(03\)00634-5](https://doi.org/10.1016/s0360-3016(03)00634-5), indexed in Pubmed: [14529790](https://pubmed.ncbi.nlm.nih.gov/14529790/).
- Azar M, Kazemi F, Jahanbakhshi A, et al. Gamma Knife Radiosurgery for Cavernous Sinus Meningiomas: Analysis of Outcome in 166 Patients. *Stereotact Funct Neurosurg.* 2017; 95(4): 259–267, doi: [10.1159/000478024](https://doi.org/10.1159/000478024), indexed in Pubmed: [28797005](https://pubmed.ncbi.nlm.nih.gov/28797005/).
- Starke RM, Williams BJ, Hiles V, et al. Gamma knife surgery for skull base meningiomas. *J Neurosurgery.* 2012; 116(3): 588–597, doi: [10.3171/2011.11.JNS11530](https://doi.org/10.3171/2011.11.JNS11530), indexed in Pubmed: [22175723](https://pubmed.ncbi.nlm.nih.gov/22175723/).