



# Upper limit of radiation treatment portals in rectal cancer: is it wise to keep using bony landmarks in the present era of 3D conformal treatment?

Surya Prakash Vankina, Surekha Goyal, Geeta S Narayanan

Department of Radiation Oncology, Vydehi Institute of Medical Sciences and Research Centre, Bangalore, India

## ABSTRACT

**Background:** This study aimed to compare the levels of L5-S1 interspace and the bifurcation of common iliac vessels on simulation images of rectal cancer patients to evaluate the adequacy of superior borders in conventional 2D planning for covering internal iliac vessels.

**Materials and methods:** Simulation images of 236 rectal cancer patients who received neoadjuvant chemoradiation and surgery were analyzed. The images were retrieved from the radiation treatment database and included delineations of L5-S1 interspace and common iliac vessel bifurcation. Distances between these landmarks were measured.

**Results:** Among the 236 patients, the majority had the common iliac artery bifurcation positioned above the L5-S1 interspace. Specifically, 78.3% of patients had the right common iliac bifurcation above L5-S1 interspace, with an average distance of 2.02 cm. For the left common iliac artery, 77.11% of patients had the bifurcation above L5-S1 interspace, with an average distance of 1.99 cm. Notably, there were cases where the bifurcations were not at the same level.

**Conclusion:** Using the L5-S1 junction as the upper border of the treatment portal may result in missing proximal nodes at risk of metastases. However, further research is needed to determine the significance of failures above the L5-S1 interspace for justifying the inclusion of the common iliac artery bifurcation in the treatment portal.

**Key words:** rectal cancer; external beam radiation therapy; upper limit

*Rep Pract Oncol Radiother 2023;28(4):565-569*

## Introduction

Rectal cancer is a common malignancy worldwide [1], and neoadjuvant chemo-radiation followed by surgery is the recommended treatment approach [2]. Adequate coverage of draining lymph nodes in the radiation treatment fields is crucial for reducing local recurrence [3]. The use of bony landmarks for treatment planning in previous studies has raised concerns about their ad-

equacy in accurately covering the at-risk lymph nodes, particularly in light of the current era of CT-based contouring guidelines [4-5]. The extent to which these landmarks can effectively encompass the lymph nodes of interest remains uncertain and requires further investigation.

This study aimed to compare the levels of L5-S1 interspace (a bony landmark) and the bifurcation of the common iliac vessels on simulation images of rectal cancer patients. The goal was to assess

**Address for correspondence:** Surya Prakash Vankina, Vydehi Institute of Medical Sciences and Research Centre, Radiation Oncology, #82, Nallurhalli, Whitefield, Bengaluru, 560066 Bangalore, India; e-mail: prakash.vankina@gmail.com

This article is available in open access under Creative Common Attribution-Non-Commercial-No Derivatives 4.0 International (CC BY-NC-ND 4.0) license, allowing to download articles and share them with others as long as they credit the authors and the publisher, but without permission to change them in any way or use them commercially

whether the superior borders of conventional 2D planning adequately covered the internal iliac vessels.

## Materials and methods

The study analyzed simulation images of rectal cancer patients (n = 236) who underwent neoadjuvant chemoradiation followed by surgery between 2007 and 2020. These images were retrieved from the radiation treatment database and encompassed delineations of the L5-S1 interspace and the bifurcation of the common iliac vessels. The L5-S1 interspace was identified as the upper boundary of the inter-vertebral space. Measurements were taken to determine the distances between these landmarks in each image set.

## Results

Among the 236 patients analyzed, the majority exhibited the common iliac artery bifurcation positioned above the L5-S1 interspace. Specifically, 185 patients (78.3%) had the right common iliac bifurcation above the L5-S1 interspace, with an average distance of 2.02 cm. In 25 patients (10.5%), the right common iliac bifurcation occurred at the level of L5-S1, while in 26 patients (11.01%), it was located below this level, with an average distance of 0.94 cm. Regarding the left common iliac artery, 182 patients (77.11%) had the bifurcation above the L5-S1 interspace, with an average distance of 1.99 cm. In 22 patients (9.32%), the left common iliac bifurcation occurred at the level of L5-S1, and in 32 patients (13.55%), it was below this level, with an average distance of 1 cm. No-

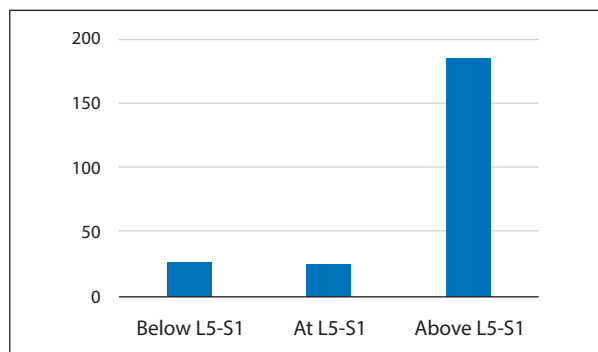
tably, there were 37 patients in whom the right and left common iliac artery bifurcations were not at the same level.

## Discussion

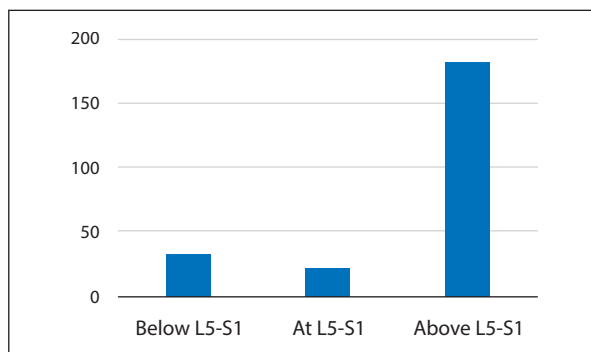
Until the early 2000s, radiotherapy planning for rectal cancers relied on bony landmarks, but there was no agreement on the optimal superior border for the pelvic field, leading to various approaches in different trials.

Pahlman and Glimelius conducted a study comparing pre- or post-operative radiotherapy in rectal cancer and set the superior border of the radiation portal at L4 [6]. In the Swedish multicenter trial [7], the upper border of the radiation portal corresponded to the top of the L5 vertebra. Goldberg et al. administered radiation to patients using parallel opposed portals from the lumbosacral junction to the perineum [8]. In the Stockholm I trial [9], operable rectal cancer patients were given pre-operative radiation with parallel opposed portals covering the anus, perineum, and regional lymph nodes up to the level of the second lumbar vertebra.

The Stockholm II trial, published in 2001, included the primary tumor and nodes up to the upper border of the L5 vertebra in the target volume [10]. For lower rectal tumors in the EORTC 22921 trial, the upper border of the radiation portal was set at the S2-S3 junction, while for upper rectal tumors, it was placed 3cm above the gross tumor [11]. In the 2009 MRC trial comparing preoperative and post-operative radiotherapy, the superior border of the radiation field was positioned at the sacral promontory [12]. The Stockholm III trial set the upper limit of the radiation field at



**Figure 1.** Distance of right common iliac bifurcation (Rt CIAB) from L5-S1



**Figure 2.** Distance of left common iliac bifurcation (Lt CIAB) from L5-S1

**Table 1.** Superior border of radiation field portals in various trials

Sl. no.	Trial Name	Superior border
1	Pahlman and Glimelius	L4
2	Swedish multicenter trial	upper border of L5 vertebra
3	Goldberg et al	lumbosacral junction
4	Stockholm I trial	L2
5	Stockholm II trial	upper border of L5 vertebra
6	EORTC 22921	S2-S3 junction
7	MRC trial	sacral promontory
8	Stockholm III trial	mid-L5, or 1-1.5cm above the promontory

**Table 2.** Clinical target volumes (CTV) in recent trials

Sl. no.	Trial Name	CTV
1	German CAO/ARO/AIO-94 phase III randomized trial	Primary tumor, meso-rectal, presacral and internal iliac lymph nodes
2	Trans-Tasman study	Primary rectal lesion, peri-rectal and internal iliac lymph nodes, meso-rectum, pelvic side walls and pre-sacral space up to the level of sacral promontory
3	RAPIDO trial	Primary lesion, and presacral, meso-rectal and internal iliac lymph nodes

the mid-L5 level or 1–1.5 cm above the promontory [13].

In contrast, recent trials have adopted CT-based planning and delineated nodal stations on CT scans. In the German CAO/ARO/AIO-94 phase III randomized trial, the target volume encompassed the primary tumor, mesorectal, presacral, and internal iliac lymph nodes [14]. Similarly, in the Trans-Tasman study [15], the radiation target volume included the primary rectal lesion, peri-rectal and internal iliac lymph nodes, mesorectum, pelvic side walls, and pre-sacral space up to the level of the sacral promontory. The RAPIDO trial [16], which examined short-course radiotherapy followed by neoadjuvant chemotherapy in locally advanced rectal cancer, employed CT-based 3D conformal treatment planning, with the target volume comprising the primary lesion and the pre-sacral, mesorectal, and internal iliac lymph nodes.

Our analysis showed that using bony landmarks, specifically the L5-S1 interspace, as the superior border for treatment fields would result in the omission of internal iliac lymph nodes in a significant number of patients. On both the left and right sides, 71.6% of patients would have missed internal iliac lymph nodes, with 78.3% on the right side and 77.11% on the left side. This finding aligns with a study conducted by Wier et al. [17] in 2014,

which examined 60 patients and demonstrated that the use of L5-S1 as the superior border of radiation therapy fields in rectal cancer would lead to a 94% omission of internal iliac nodes. Similarly, Sanjee et al. [18] compared 2-dimensional and 3-dimensional plans in 86 patients with rectal malignancies and found that 32 out of 86 patients experienced a geographical miss of internal iliac nodes when L5-S1 was used as the superior border.



**Figure 3.** Comparison of upper border based on bony landmarks and the nodal stations on computed tomography (CT) scan. Red — L5-S1 junction, yellow — common iliac vessels, mustard — internal and external iliac vessels, orange — obturator vessels

Leibold et al. [19] evaluated the location of metastatic lymph nodes relative to the borders of radiation treatment fields and found that lymph nodes in the apical, mid, and peri-colonic stations, situated along the inferior mesenteric artery, were positioned proximal to the L5-S1 junction. These nodal regions accounted for approximately 18% of nodal metastases and were located outside the treatment portal.

Tse-Kuan Yu and his research team [20] conducted a study involving 554 patients who received surgery and pre- or post-operative radiotherapy with concurrent chemotherapy between 1989 and 2001. They observed that out of the 46 patients who experienced loco-regional recurrence, 65% were in-field, 16% were marginal, and 19% were out of the treatment field. Among the in-field recurrences, 56% occurred in the low pelvis, 22% in the presacral area, 15% in the mid-pelvic area, and 7% in the high pelvic area. Based on these findings, they concluded that 78% of in-field recurrences were concentrated in the low pelvic and presacral regions. Another study by Kusters et al. [21] in the Dutch TME trial also supported the notion that presacral recurrences were the most frequent site of failure.

## Conclusion

This study highlights the potential limitations of relying solely on the L5-S1 junction as the upper border of the treatment portal in rectal cancer patients, as it may lead to a significant omission of proximal nodes at risk of metastases. By taking into account the average height of the L4 vertebral body, which is approximately 30 mm, using the upper edge of the L4-L5 interspace as the superior border of the radiation portal can ensure sufficient coverage of the nodal target volume while accounting for potential setup error and beam penumbra.

However, it is important to note that there is currently insufficient robust data on the extent of failures above the L5-S1 interspace to justify including the excess volume in the treatment portal. Further research, including a meta-analysis comparing failure patterns between cohorts using 2D and 3D treatment planning, would provide valuable insights for optimizing treatment portals in non-metastatic rectal cancer patients receiving neoadjuvant radiation therapy.

## Limitations

All patients in this cohort had been planned with 3-dimensional radiation therapy (3DCRT), with the clinical target volume outlined as per the contouring guidelines [4, 5] and hence it was not possible to assess the nodal failure patterns with 2-dimensional planning fields.

## Ethical statement

This retrospective audit was conducted with clearance from the Institutional Ethical Committee, and the Institutional Review Board. Prior consent had been obtained from all patients for the use of the scientific data for research purposes.

## Conflict of interests

The authors declare no conflicts of interest.

## Funding

The study did not receive any institutional or external funding.

## References

1. Siegel RL, Miller KD, Jemal A. Cancer statistics, 2018. *CA Cancer J Clin.* 2018; 68(1): 7–30, doi: [10.3322/caac.21442](https://doi.org/10.3322/caac.21442), indexed in Pubmed: [29313949](https://pubmed.ncbi.nlm.nih.gov/29313949/).
2. Benson AIB, Venook AP, Al-Hawary MM, et al. NCCN Guidelines Insights: Rectal Cancer, Version 6.2020. *J Natl Compr Canc Netw.* 2020; 18(7): 806–815, doi: [10.6004/jnccn.2020.0032](https://doi.org/10.6004/jnccn.2020.0032), indexed in Pubmed: [32634771](https://pubmed.ncbi.nlm.nih.gov/32634771/).
3. McCall JL, Cox MR, Wattoo DA. Analysis of local recurrence rates after surgery alone for rectal cancer. *Int J Colorectal Dis.* 1995; 10(3): 126–132, doi: [10.1007/BF00298532](https://doi.org/10.1007/BF00298532), indexed in Pubmed: [7561427](https://pubmed.ncbi.nlm.nih.gov/7561427/).
4. Valentini V, Gambacorta MA, Barbaro B, et al. International consensus guidelines on Clinical Target Volume delineation in rectal cancer. *Radiother Oncol.* 2016; 120(2): 195–201, doi: [10.1016/j.radonc.2016.07.017](https://doi.org/10.1016/j.radonc.2016.07.017), indexed in Pubmed: [27528121](https://pubmed.ncbi.nlm.nih.gov/27528121/).
5. Myerson RJ, Garofalo MC, El Naqa I, et al. Elective clinical target volumes for conformal therapy in anorectal cancer: a radiation therapy oncology group consensus panel contouring atlas. *Int J Radiat Oncol Biol Phys.* 2009; 74(3): 824–830, doi: [10.1016/j.ijrobp.2008.08.070](https://doi.org/10.1016/j.ijrobp.2008.08.070), indexed in Pubmed: [19117696](https://pubmed.ncbi.nlm.nih.gov/19117696/).
6. Pahlman L, Glimelius B. Pre- or postoperative radiotherapy in rectal and rectosigmoid carcinoma. Report from a randomized multicenter trial. *Ann Surg.* 1990; 211(2): 187–195, doi: [10.1097/0000658-199002000-00011](https://doi.org/10.1097/0000658-199002000-00011), indexed in Pubmed: [2405793](https://pubmed.ncbi.nlm.nih.gov/2405793/).
7. Initial report from a Swedish multicentre study examining the role of preoperative irradiation in the treatment of patients with resectable rectal carcinoma. *Swedish Rectal Cancer Trial. Br J Surg.* 1993; 80(10): 1333–1336, doi: [10.1002/bjs.1800801040](https://doi.org/10.1002/bjs.1800801040), indexed in Pubmed: [8242317](https://pubmed.ncbi.nlm.nih.gov/8242317/).

8. Goldberg PA, Nicholls RJ, Porter NH, et al. Long-term results of a randomised trial of short-course low-dose adjuvant pre-operative radiotherapy for rectal cancer: reduction in local treatment failure. *Eur J Cancer*. 1994; 30A(11): 1602–1606, doi: [10.1016/0959-8049\(94\)00312-s](https://doi.org/10.1016/0959-8049(94)00312-s), indexed in Pubmed: [7530469](https://pubmed.ncbi.nlm.nih.gov/7530469/).
9. Stockholm Rectal Cancer Study Group. Preoperative short-term radiation therapy in operable rectal carcinoma: A prospective randomized trial. *Cancer*. 1990; 66(1): 49–55, doi: [10.1002/1097-0142\(19900701\)66:1<49::aid-cn-cr2820660111>3.0.co;2-1](https://doi.org/10.1002/1097-0142(19900701)66:1<49::aid-cn-cr2820660111>3.0.co;2-1), indexed in Pubmed: [2191763](https://pubmed.ncbi.nlm.nih.gov/2191763/).
10. Martling A, Holm T, Johansson H, et al. The Stockholm II trial on preoperative radiotherapy in rectal carcinoma. *Cancer*. 2001; 92(4): 896–902, doi: [10.1002/1097-0142\(20010815\)92:4<896::aid-cn-cr1398>3.0.co;2-r](https://doi.org/10.1002/1097-0142(20010815)92:4<896::aid-cn-cr1398>3.0.co;2-r), indexed in Pubmed: [11550163](https://pubmed.ncbi.nlm.nih.gov/11550163/).
11. Bosset JF, Calais G, Mineur L, et al. Enhanced tumorocidal effect of chemotherapy with preoperative radiotherapy for rectal cancer: preliminary results--EORTC 22921. *J Clin Oncol*. 2005; 23(24): 5620–5627, doi: [10.1200/JCO.2005.02.113](https://doi.org/10.1200/JCO.2005.02.113), indexed in Pubmed: [16009958](https://pubmed.ncbi.nlm.nih.gov/16009958/).
12. Sebag-Montefiore D, Stephens RJ, Steele R, et al. Pre-operative radiotherapy versus selective postoperative chemoradiotherapy in patients with rectal cancer (MRC CR07 and NCIC-CTG C016): a multicentre, randomised trial. *Lancet*. 2009; 373(9666): 811–820, doi: [10.1016/S0140-6736\(09\)60484-0](https://doi.org/10.1016/S0140-6736(09)60484-0), indexed in Pubmed: [19269519](https://pubmed.ncbi.nlm.nih.gov/19269519/).
13. Pettersson D, Cedermark B, Holm T, et al. Interim analysis of the Stockholm III trial of preoperative radiotherapy regimens for rectal cancer. *Br J Surg*. 2010; 97(4): 580–587, doi: [10.1002/bjs.6914](https://doi.org/10.1002/bjs.6914), indexed in Pubmed: [20155787](https://pubmed.ncbi.nlm.nih.gov/20155787/).
14. Sauer R, Liersch T, Merkel S, et al. Preoperative versus postoperative chemoradiotherapy for locally advanced rectal cancer: results of the German CAO/ARO/AIO-94 randomized phase III trial after a median follow-up of 11 years. *J Clin Oncol*. 2012; 30(16): 1926–1933, doi: [10.1200/JCO.2011.40.1836](https://doi.org/10.1200/JCO.2011.40.1836), indexed in Pubmed: [22529255](https://pubmed.ncbi.nlm.nih.gov/22529255/).
15. Ngan SY, Burmeister B, Fisher RJ, et al. Randomized trial of short-course radiotherapy versus long-course chemoradiation comparing rates of local recurrence in patients with T3 rectal cancer: Trans-Tasman Radiation Oncology Group trial 01.04. *J Clin Oncol*. 2012; 30(31): 3827–3833, doi: [10.1200/JCO.2012.42.9597](https://doi.org/10.1200/JCO.2012.42.9597), indexed in Pubmed: [23008301](https://pubmed.ncbi.nlm.nih.gov/23008301/).
16. Nilsson PJ, van Etten B, Hospers GAP, et al. Short-course radiotherapy followed by neo-adjuvant chemotherapy in locally advanced rectal cancer--the RAPIDO trial. *BMC Cancer*. 2013; 13: 279, doi: [10.1186/1471-2407-13-279](https://doi.org/10.1186/1471-2407-13-279), indexed in Pubmed: [23742033](https://pubmed.ncbi.nlm.nih.gov/23742033/).
17. Weir RA, Bhirud AR, Bennion NR, et al. L5/S1 as the Superior Border of Radiation Therapy Fields in Rectal Cancer Misses Internal Iliac Lymph Nodes. *Int J Radiat Oncol Biol Phys*. 2014; 90(1): S390–S391, doi: [10.1016/j.ijrobp.2014.05.1251](https://doi.org/10.1016/j.ijrobp.2014.05.1251).
18. Sanjee C, Kumar P, Mayank M, et al. Is three-Dimensional CT based Conformal Radiotherapy Superior to Two-dimensional X ray-based Radiotherapy for Neoadjuvant Radiotherapy in Locally advanced Carcinoma Rectum? *Cancer Ther Oncol Int J*. 2020; 15(3), doi: [10.19080/ctoj.2020.15.555915](https://doi.org/10.19080/ctoj.2020.15.555915).
19. Leibold T, Shia J, Ruo L, et al. Prognostic implications of the distribution of lymph node metastases in rectal cancer after neoadjuvant chemoradiotherapy. *J Clin Oncol*. 2008; 26(13): 2106–2111, doi: [10.1200/JCO.2007.12.7704](https://doi.org/10.1200/JCO.2007.12.7704), indexed in Pubmed: [18362367](https://pubmed.ncbi.nlm.nih.gov/18362367/).
20. Yu TK, Bhosale PR, Crane CH, et al. Patterns of locoregional recurrence after surgery and radiotherapy or chemoradiation for rectal cancer. *Int J Radiat Oncol Biol Phys*. 2008; 71(4): 1175–1180, doi: [10.1016/j.ijrobp.2007.11.018](https://doi.org/10.1016/j.ijrobp.2007.11.018), indexed in Pubmed: [18207667](https://pubmed.ncbi.nlm.nih.gov/18207667/).
21. Kusters M, Marijnen CAM, van de Velde CJH, et al. Patterns of local recurrence in rectal cancer; a study of the Dutch TME trial. *Eur J Surg Oncol*. 2010; 36(5): 470–476, doi: [10.1016/j.ejso.2009.11.011](https://doi.org/10.1016/j.ejso.2009.11.011), indexed in Pubmed: [20096534](https://pubmed.ncbi.nlm.nih.gov/20096534/).