



# Radiotherapy combined or not with chemotherapy in adult or pediatric patients with brainstem glioma: a population-based study

Fabio Y. Moraes<sup>1,2</sup>, Andre G. Gouveia<sup>2,3</sup>, Gustavo N. Marta<sup>2,4</sup>, Gustavo A. Viani<sup>2,5</sup>

<sup>1</sup>Department of Oncology — Division of Radiation Oncology, Kingston General Hospital, Queen's University, Kingston, ON, Canada

<sup>2</sup>Latin America Cooperative Oncology Group (LACOG), Porto Alegre, Brazil

<sup>3</sup>Radiation Oncology Department, Americas Centro de Oncologia Integrado, Rio de Janeiro, RJ, Brazil

<sup>4</sup>Radiation Oncology Department, Hospital Sirio Libanês, São Paulo, Brazil

<sup>5</sup>Ribeirão Preto Medical School, Department of Medical Imaging, Hematology and Oncology of University of São Paulo (FMRP-USP), Ribeirão Preto, Brazil

## ABSTRACT

**Background:** The purpose of this study was to assess the treatment outcomes and prognostic factors of brainstem glioma (BCG) patients treated by radiotherapy (RT) or chemoradiation (CHRT) in the last 20 years in a population cohort.

**Materials and methods:** Patients diagnosed with BSG from 2000–2020 treated by RT or CHRT were identified from The Fundação Oncocentro de São Paulo database. Data on age, gender, practice setting, period of treatment, and treatment modality were extracted. The overall survival (OS) was estimated, and the subgroups were compared with the log-rank test. Cox proportional test was used in multivariate analysis.

**Results:** A total of 253 patients with a median follow-up of 12 months were included. There were 197 pediatric and 56 adult patients. For the entire cohort, the 1 and 3-year OS was 46%, and 23%, with a median OS of 11 months. In the subgroup analysis, adults had a median survival of 33 months versus 10 months in pediatric patients ( $p = 0.002$ ). No significant difference in OS between RT and CHRT was observed in pediatric or adult subgroups ( $p > 0.05$ ). The use of CHRT has significantly increased over the years. In the multivariate analysis, adult patients were the only independent prognostic factor associated with a better OS ( $p < 0.001$ ).

**Conclusions:** BSG had poor survival with no significant improvement in the treatment outcomes over the last 20 years, despite the addition of chemotherapy. Adult patients were independently associated with better survival.

**Key words:** brainstem glioma; radiotherapy; chemoradiation; survival

*Rep Pract Oncol Radiother 2023;28(2):181–188*

## Introduction

Primary brainstem glioma (BSG) is a rare tumor that affects less than 2% of adults and around 10% of pediatric patients with brain tumors [1, 2].

Currently, they are classified into diffuse (widely distributed), focal, exophytic (growing from the epithelium), and cervicomedullary, based on radiological findings and clinical presentation [3–5]. Among the subtypes, diffuse brainstem glioma

**Address for correspondence:** Gustavo Arruda Viani, Dr. Rubem Aloysio Monteiro Street 155, Zip code-1402686, tel: 55-16-34026584/fax: 55-16-34021744; e-mail: gusviani@gmail.com

This article is available in open access under Creative Common Attribution-Non-Commercial-No Derivatives 4.0 International (CC BY-NC-ND 4.0) license, allowing to download articles and share them with others as long as they credit the authors and the publisher, but without permission to change them in any way or use them commercially

mas are the most common, corresponding to 80% of all BSGs [1, 2]. They are the most aggressive subgroup, typically occurring in the pons [1, 2].

BSG is considered to be an aggressive primary central nervous system (CNS) tumor with a poor overall survival (OS) despite the treatment modality employed [1, 2]. Although many collaborative efforts have been made to improve the treatment outcomes, the OS has remained dismal in the last thirty years ranging from 10 to 12 months [1, 2].

Several interventions have been investigated, including radiotherapy (RT), surgical resection, systemic therapy, and treatment combinations [1, 2, 5–8]. However, RT is the only treatment that has consistently demonstrated clinical and radiographic improvement in BSG [1, 2, 5–8]. Conventional fractionated RT (total dose of 54 to 60 Gy delivered in 30 fractions (1.8 to 2 Gy per fraction per day) over six weeks with conformed volumes is the most common approach [1, 2, 5–8]. RT allows a neurological improvement, reduction or discontinuation of steroids, and radiographic response with low severe toxicity rates [1, 2, 5–8].

In 2005, the postoperative combination of RT and temozolomide (TMZ) was associated with better survival compared to RT alone in adult patients with glioblastoma [9]. In contrast, in diffuse brainstem gliomas, the addition of TMZ to radiotherapy did not show a consistent benefit [7, 10–12]. Moreover, other chemotherapy agents' role in treating primary or brainstem glioma is not well defined [1, 2].

Therefore, the present study aims to assess the outcomes and determine prognostic factors associated with the survival of BSG treated with RT combined or not with chemotherapy using a sizable population cohort [13].

## Materials and methods

We designed a populational cohort study investigating the Fundação Oncocentro de São Paulo (FOSP) database available online at <http://www.fosp.saude.sp.gov.br> (Accessed on March 22nd 2022) [13]. FOSP holds a prospective database of treatments performed for all hospital and oncology departments in Sao Paulo State, Brazil. At present, the FOSP database contains more than 1 million patients treated in the state of São Paulo. The database registers patient information such as

age at diagnosis, the period between the diagnostic and treatment, tumor histology, gender, medical practice (public or private insured), educational level, clinical stage, treatment, recurrence of the disease and patients' death cause. The follow-up is annually updated to follow the patient's status after treatment.

Inclusion criteria of the participants of this study were 3 years or older, patients with C71 topography primary brainstem tumor with a morphological diagnosis of glioma (93803; 93823; 94403) treated by RT or chemoradiation (CHRT) between January 2000 and April 2020. Patients who were treated by chemotherapy alone or surgery were excluded.

Patients' age was categorized into two groups: pediatric ( $\leq 21$  years) and adults ( $> 21$  years) [14]. To evaluate if the advances in the treatment influenced the outcomes over time, the treatment period was separated into four quinquennium periods: 2000–2004, 2005–2009, 2010–2014, and 2015+ (2015–2020).

The primary endpoint was OS, which was defined from the date of treatment to death due to any cause or related to the disease. The article was organized based on The Strengthening the Reporting of Observational Studies in Epidemiology (STROBE) recommendations (<https://www.equator-network.org/reporting-guidelines/strobe/>).

## Statistical analysis

The background demographic and baseline characteristics were described. Categorical variables are described as percentages and frequencies. Multivariate Cox proportional-hazards model was used to estimate hazard ratios with corresponding 95% confidence intervals for the primary endpoints in the subgroups between the treatment modalities and patient characteristics. The Kaplan-Meier (KM) curves were used to exhibit survival curves visually, and the log-rank test was used to compare the differences between the groups. A 5% level was considered statistically significant. SPSS 25.0 (IBM, Armonk, NY) and Graph Prism V9.0 were used for statistical analyses.

## Results

A total of 284 patients with BSG were registered in the FOSP database. After applying the inclusion criteria, a total of 253 patients were selected for

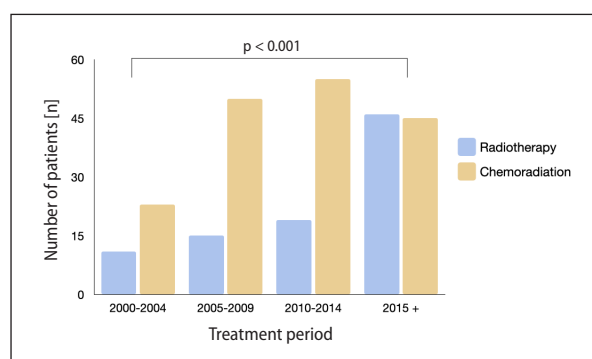
analysis. Figure 1S in the Supplementary File describes the flow of patients to be included in this cohort, and Table 1 describes the cohort characteristics. The median age of the sample was 13 years old (ranging from 3 to 60), with most patients classified as pediatric (197 = 77.9%). CHRT and RT were used in 162 (64%) and 91 (36%) patients, respectively. The number of patients treated by RT or CHRT increased over the last twenty years (Fig. 1).

The median follow-up for the entire cohort was 12 months (ranging from 0–233 months). During the follow-up period, 183 deaths were registered. For the entire cohort, the OS at 1 and 3 years was 46% [95% confidence interval (CI): 36–57%),

**Table 1.** Characteristics of brainstem gliomas treated with radiotherapy or chemoradiation

Variable	n = 253 (%)
<b>Age (year)</b>	
Median (range)	13 (1-60)
3–09	148 (58.4)
10–19	49 (19.3)
20–29	19 (7.5)
30–39	20 (7.9)
40–49	12 (4.7)
50–59	4 (1.5)
> 60	1 (0.4)
<b>Age classification</b>	
Pediatric	197 (77.9)
Adult	56 (22.1)
<b>Gender</b>	
Female	128 (50.6)
Male	125 (49.4)
<b>Treatment modality</b>	
Chemoradiation	162 (64)
Radiotherapy	91 (36)
<b>Medical practice</b>	
Public	226 (89.3)
Private	27 (10.7)
<b>Treatment period</b>	
2000–2004	34 (2.7)
2005–2009	65 (34.2)
2010–2014	63 (18.3)
2015+	91 (12.1)
<b>Follow-up</b>	
Median	10 months
Range	1–233
IQR	6–21

IQR — interquartile



**Figure 1.** The number of patients treated by radiotherapy (RT) or chemoradiation (CHRT) over the last twenty years

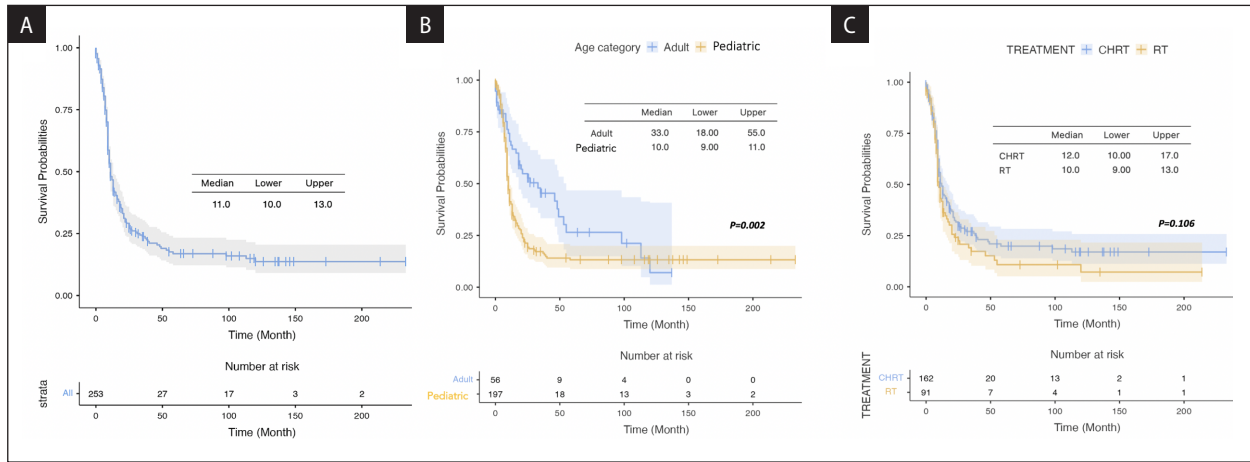
and 23% (95% CI: 16.5–33.4%), respectively, with a median OS of 11 months (95% CI: 10–13 months) (Fig. 2A).

In the univariate analysis, adult patients were associated with a better OS than pediatric (1-year OS 68% vs. 40%,  $p = 0.002$ ), with a median OS of 33 months (95% CI: 18–55) for adults and 10 months (95% CI: 9–11) for pediatrics, respectively (Fig. 2B). There was no significant difference in OS between CHRT and RT (1-year OS 49% vs. 42%,  $p = 0.102$ ) (Fig. 2C). The median OS with CHRT and RT was 12 (95% CI: 10–17) and 10 months (95% CI: 9–13).

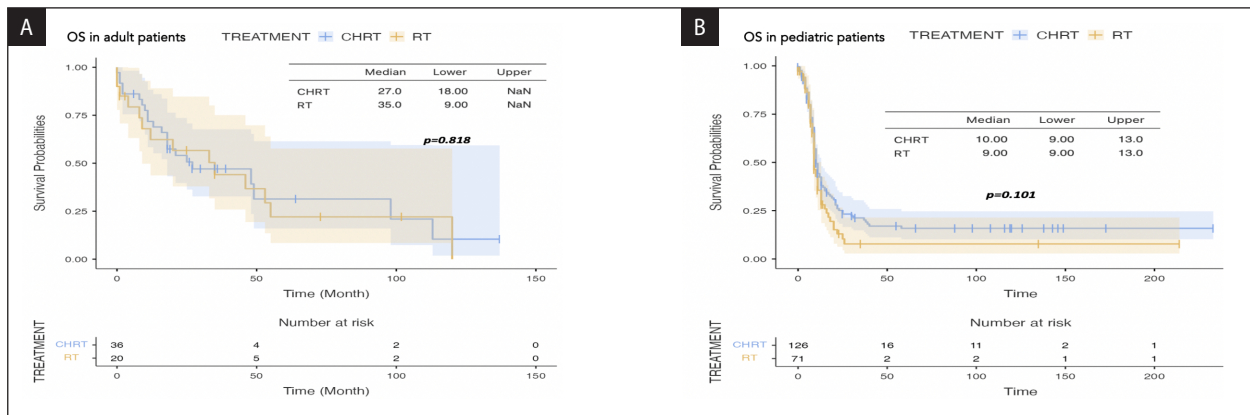
Comparing CHRT with RT in the adult subgroup, no significant difference was observed with the combined treatment (Fig. 3A). In the pediatric subgroup, RT and CHRT had no significant OS (Fig. 3B). In the multivariate Cox regression analysis, gender ( $p = 0.09$ ), treatment modality ( $p = 0.437$ ), practice setting ( $p = 0.203$ ), and treatment period ( $p > 0.05$ ) were not significantly related to survival (Fig. 4). Age category (pediatric vs. adult) was the only significant factor associated with survival in the multivariate analysis [hazard ratio (HR) = 0.35 (95% CI: 0.21–0.55,  $p < 0.001$ )] (Fig. 4).

## Discussion

The OS observed in this large real-world study was poor and agreed with other populational and prospective studies employing RT to treat BSG [7, 15–20]. Despite the significant increase in the use of CHRT over the last twenty years, the outcomes have not significantly changed, with no significant difference in OS between gender (male vs. female), practice setting (public vs. private), treat-



**Figure 2.** A. Overall survival (OS) for the entire cohort; B. OS per age category: adult or pediatric patients; C. OS per treatment type: radiotherapy (RT) or chemoradiotherapy (CHRT)



**Figure 3.** A. Overall survival (OS) in adults with radiotherapy (RT) or chemoradiotherapy (CHRT); B. OS in pediatric patients with RT or CHRT

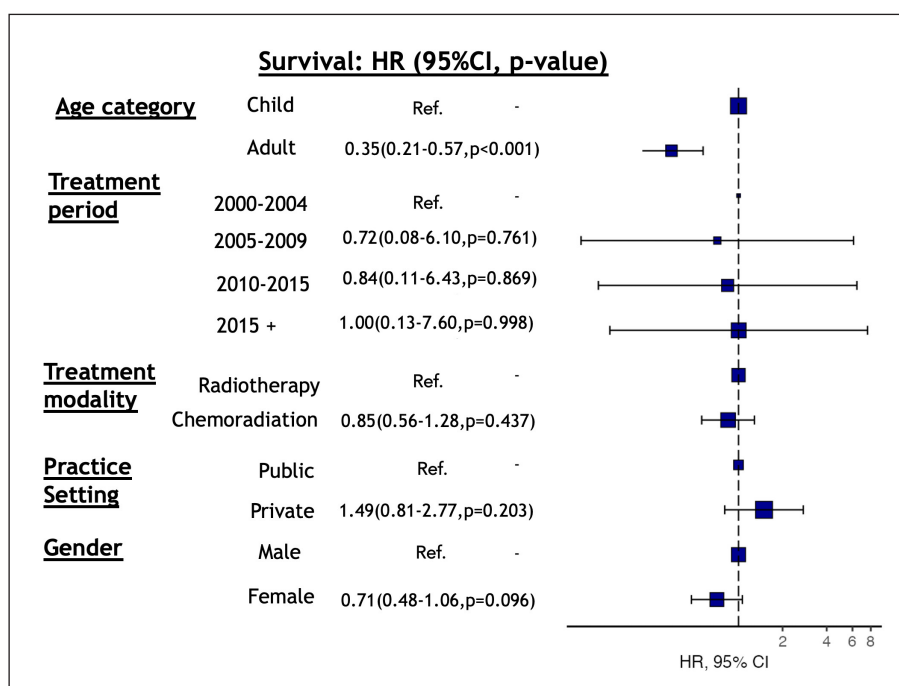
ment (CHRT vs. RT alone), and period of treatment. The only subgroup showing better OS was adults when compared to pediatric patients. CHRT was not associated with differences in OS in neither the pediatric nor adult subgroups.

In our populational cohort, BSG in pediatric patients was associated with a survival of about only 10 months, with rare cases achieving the five years OS mark. In the multivariate analysis, pediatric patients were an independent factor associated with worse survival. On the other hand, the median survival for adult BSG was 33 months. The possible reason to explain this survival divergence is related to histology differences. The tumor histology is an essential factor and possibly explains the poor prognosis of BSG in children. Reyes-Botero et al. reported that BSGs in adults represented hetero-

geneous tumor types, predominantly low-grade tumors [21]. Conversely, grade IV was the most common BSG in children, with rates varying from 50-60% [22–23].

Surgical intervention (stereotactic biopsy or resection) is essential to establish the tumor grade [21–23]. The indication for surgical intervention is controversial and should be determined carefully, considering both the safety and poor predicted prognosis. In the present cohort, we excluded patients submitted to any surgical procedure to evaluate the role of RT or CHRT and prognostic factors, limiting histological grade evaluation.

The observed short survival in children with BSG raises the question of whether a more protracted RT regimen would not be more appropriate to reduce the psychosocial and treatment



**Figure 4.** Multivariate analysis of patient and treatment factors with survival. HR — hazard ratio; CI — confidence interval

burden on children and their families as well as the potential risks of daily anesthesia. For pediatric and adult BSG, the standard of care treatment involves field radiation therapy, typically to a dose ranging between 54–60 Gy [1, 2]. Recently, several studies have tested hypofractionated to treat BSG [7, 16–19].

For example, Janssens et al. designed a 1:1 matched cohort analysis comparing two hypofractionated RT courses (39 Gy in 13 fractions or 44.8 Gy in 16 fractions,  $n = 27$ ) with the conventional (54 Gy in 30 fractions,  $n = 27$ ) RT schedule [18]. There was no significant difference in time to progression (5.0 vs. 7.6 months;  $p = 0.2$ ) and median OS (9.0 vs. 9.4 months;  $p = 0.8$ ) between hypofractionated and conventional RT, respectively [18]. The most meaningful benefit of hypofractionated RT was its shorter overall treatment time than conventional RT (3 vs. 6 weeks) [18].

Moreover, in a randomized trial, Zaghoul et al. indicated that two hypofractionated RT courses were not inferior to conventional RT [19]. However, more caution is required in using 45 Gy in 15 fractions in younger patients (2–5 years of age) due to the loss in the non-inferiority [19]. Recently Iz-zuddeen et al. showed that the combination of hypofractionated RT with TMZ increased the hematological toxicity and did not improve OS in

patients with diffuse pontine gliomas [7]. Based on the short survival observed in our sample, the hypofractionated schedule can be especially attractive for pediatric patients.

The addition of chemotherapy combined with RT remains uncertain for BSG. Our data reveal a significant increase in the use of the combined treatment after 2004 (Fig. 1), likely influenced by the favorable outcomes with CHRT from the EO-RTC trial in glioblastoma patients [9]. To date, trials for BSG have failed to identify a significant benefit with the combination of chemotherapy [1, 2, 7]. For instance, a phase 2 trial combining TMZ with RT followed by adjuvant TMZ, for BSG, resulted in a median OS of only 9.5 months [11]. A multi-institutional study also evaluated the role of TMZ in treating newly BSG in children, and the addition of chemotherapy did not affect the short survival [10].

In our population cohort, no signal of benefit for survival was observed with the addition of chemotherapy. Even when we performed a subgroup analysis, comparing CHRT vs. RT in only adult patients ( $> 21$  years). In this subgroup of 56 patients, the combined treatment produced an absolute superior survival (26.6 vs. 34.5 months,  $p = 0.818$ ). In this aspect, our results disagree with the MD Anderson retrospective

analysis [24]. Their analysis showed a significant difference in survival in adults with brainstem glioblastoma treated with the standard Stupp regimen (23.1 vs. 4.0) months [24]. However, it is essential to keep in mind that in our study, there was no information on the chemotherapy regimens employed over the years, no distinction of the tumor location, and the absence of information regarding the tumor grade, which can explain the difference between the findings.

Recently, a systematic review assessed the outcomes of chemotherapeutic agents for BSG [2]. The median OS was 11.5 vs. 9.4 months for those who received combined treatment or not, respectively. Thus, our data agree with the literature regarding the benefit of the combined treatment. The recommendation to add a chemotherapy agent to RT should be counterbalanced against the risks of toxicity. Combined treatment for BSG can potentially impair the quality of life of this fragile patient population without offering a substantial clinical benefit. The clinical heterogeneity in the BSG patients directly influences selection and treatment bias in choosing the treatment option. Thus, clinical trials are warranted to adequately justify the use or not of CHRT.

To assess if the advancements in radiation and systemic strategies impact the survival outcomes, we performed a subgroup analysis, splitting twenty years into four quinquennia. No significant difference for OS was noted in the univariate and multivariate analysis, which means that survival outcomes for BSG have not changed significantly over the past twenty years. Therefore, the pathway to enhance the outcomes would be a better molecular characterization of BSG.

The K27M mutation in H3.3 histone (K27M-H3.3 mutation) in diffuse pontine glioma in children has been recently identified [2]. Patients with the K27M mutation in histone H3.1 or H3.3 have a significantly poorer OS than those without the mutation [2]. On the other hand, the mutation could allow new therapeutic approaches for BSG in children with molecular target therapy [2]. Reyes-Botero et al. documented that the KM27-H3 mutation was also identified in adults but with a lower frequency than pediatric BSG [25]. These findings correlate and reinforce the heterogeneous histology, with a predominance of low-grade tumors in adult BSG. Future

studies should focus on determining whether adult BSGs have distinct molecular features from pediatric BSGs. This knowledge could open an avenue for using targeted therapy combined with RT. However, molecular characterization depends on obtaining adequate tissue samples for histopathologic analysis. Thus, the integration of contemporary stereotactic neurosurgical procedures could help characterize and alter their poor prognosis.

Although the outcomes presented here agree with the literature, our study has inherent limitations related to its design, such as bias selection, limited availability of patient data regarding the RT/chemotherapy dose schedule and technique, and no information on toxicity. Moreover, data concerning the radiological brainstem classification and the use of molecular classification were not available. However, despite these limitations, the present study contributes to the evidence regarding best practices in treating BSG using a large population cohort.

## Conclusion

Using a large population database here we report that survival was poor and has not improved over the last twenty years for patients with BSG. We also found that, although the use of CHRT increased over time, it has not translated into survival benefits for neither the adult nor pediatric population. Finally, BSG in the pediatric group was an independent factor associated with poorer survival, possibly related to aggressive histology.

## Conflict of interest

F.Y.M. reports previous consulting fee from Elekta and honoraria from Astra Zeneca, both outside the current work. All other authors have no competing interests.

## Funding

None declared.

## Acknowledgements

None declared.

## Data availability statement

Research data are stored and will be shared upon request to the corresponding author.

## Ethical permission

Ethical approval was not necessary for the preparation of this article.

## References

- Guillamo JS, Doz F, Delattre JY. Brain stem gliomas. *Curr Opin Neurol*. 2001; 14(6): 711–715, doi: [10.1097/00019052-200112000-00006](https://doi.org/10.1097/00019052-200112000-00006), indexed in Pubmed: [11723378](https://pubmed.ncbi.nlm.nih.gov/11723378/).
- Wummer B, Woodworth D, Flores C. Brain stem gliomas and current landscape. *J Neurooncol*. 2021; 151(1): 21–28, doi: [10.1007/s11060-020-03655-w](https://doi.org/10.1007/s11060-020-03655-w), indexed in Pubmed: [33398531](https://pubmed.ncbi.nlm.nih.gov/33398531/).
- Epstein F. A staging system for brain stem gliomas. *Cancer*. 1985; 56(7 Suppl): 1804–1806, doi: [10.1002/1097-0142\(19851001\)56:7+<1804::aid-cn-cr2820561316>3.0.co;2-5](https://doi.org/10.1002/1097-0142(19851001)56:7+<1804::aid-cn-cr2820561316>3.0.co;2-5), indexed in Pubmed: [4027915](https://pubmed.ncbi.nlm.nih.gov/4027915/).
- Barkovich AJ, Krischer J, Kun LE, et al. Brain stem gliomas: a classification system based on magnetic resonance imaging. *Pediatr Neurosurg*. 1990; 16(2): 73–83, doi: [10.1159/000120511](https://doi.org/10.1159/000120511), indexed in Pubmed: [2132928](https://pubmed.ncbi.nlm.nih.gov/2132928/).
- Epstein F, Constantini S. Practical decisions in the treatment of pediatric brain stem tumors. *Pediatr Neurosurg*. 1996; 24(1): 24–34, doi: [10.1159/000121011](https://doi.org/10.1159/000121011), indexed in Pubmed: [8817612](https://pubmed.ncbi.nlm.nih.gov/8817612/).
- Massimino M, Spreafico F, Biassoni V, et al. Diffuse pontine gliomas in children: changing strategies, changing results? A mono-institutional 20-year experience. *J Neurooncol*. 2008; 87(3): 355–361, doi: [10.1007/s11060-008-9525-5](https://doi.org/10.1007/s11060-008-9525-5), indexed in Pubmed: [18217208](https://pubmed.ncbi.nlm.nih.gov/18217208/).
- Izzuddeen Y, Gupta S, Haresh KP, et al. Hypofractionated radiotherapy with temozolomide in diffuse intrinsic pontine gliomas: a randomized controlled trial. *J Neurooncol*. 2020; 146(1): 91–95, doi: [10.1007/s11060-019-03340-7](https://doi.org/10.1007/s11060-019-03340-7), indexed in Pubmed: [31728883](https://pubmed.ncbi.nlm.nih.gov/31728883/).
- Korones DN, Fisher PG, Kretschmar C, et al. Treatment of children with diffuse intrinsic brain stem glioma with radiotherapy, vincristine and oral VP-16: a Children's Oncology Group phase II study. *Pediatr Blood Cancer*. 2008; 50(2): 227–230, doi: [10.1002/pbc.21154](https://doi.org/10.1002/pbc.21154), indexed in Pubmed: [17278121](https://pubmed.ncbi.nlm.nih.gov/17278121/).
- Stupp R, Mason WP, van den Bent MJ, et al. European Organisation for Research and Treatment of Cancer Brain Tumor and Radiotherapy Groups, National Cancer Institute of Canada Clinical Trials Group. Radiotherapy plus concomitant and adjuvant temozolomide for glioblastoma. *N Engl J Med*. 2005; 352(10): 987–996, doi: [10.1056/NEJMoa043330](https://doi.org/10.1056/NEJMoa043330), indexed in Pubmed: [15758009](https://pubmed.ncbi.nlm.nih.gov/15758009/).
- Cohen KJ, Heideman RL, Zhou T, et al. Temozolomide in the treatment of children with newly diagnosed diffuse intrinsic pontine gliomas: a report from the Children's Oncology Group. *Neuro Oncol*. 2011; 13(4): 410–416, doi: [10.1093/neuonc/noq205](https://doi.org/10.1093/neuonc/noq205), indexed in Pubmed: [21345842](https://pubmed.ncbi.nlm.nih.gov/21345842/).
- Bailey S, Howman A, Wheatley K, et al. Diffuse intrinsic pontine glioma treated with prolonged temozolomide and radiotherapy—results of a United Kingdom phase II trial (CNS 2007 04). *Eur J Cancer*. 2013; 49(18): 3856–3862, doi: [10.1016/j.ejca.2013.08.006](https://doi.org/10.1016/j.ejca.2013.08.006), indexed in Pubmed: [24011536](https://pubmed.ncbi.nlm.nih.gov/24011536/).
- Sirachainan N, Pakakasama S, Visudithbhan A, et al. Concurrent radiotherapy with temozolomide followed by adjuvant temozolomide and cis-retinoic acid in children with diffuse intrinsic pontine glioma. *Neuro Oncol*. 2008; 10(4): 577–582, doi: [10.1215/15228517-2008-025](https://doi.org/10.1215/15228517-2008-025), indexed in Pubmed: [18559468](https://pubmed.ncbi.nlm.nih.gov/18559468/).
- Fundação Oncocentro de São Paulo (FOSP), Registro Hospitalar de Câncer (RHC). Base de dados do RHC. <http://200.144.1.68/cgi-bin/dh?rhc/rhc-geral.def> (March 22, 2022).
- Williams K, Thomson D, Seto I, et al. StaR Child Health Group. Standard 6: age groups for pediatric trials. *Pediatrics*. 2012; 129 Suppl 3: S153–S160, doi: [10.1542/peds.2012-0055I](https://doi.org/10.1542/peds.2012-0055I), indexed in Pubmed: [22661762](https://pubmed.ncbi.nlm.nih.gov/22661762/).
- Maxwell R, Luksik AS, Garzon-Muvdi T, et al. Population-based Study Determining Predictors of Cancer-Specific Mortality and Survival in Pediatric High-grade Brainstem Glioma. *World Neurosurg*. 2018; 119: e1006–e1015, doi: [10.1016/j.wneu.2018.08.044](https://doi.org/10.1016/j.wneu.2018.08.044), indexed in Pubmed: [30138731](https://pubmed.ncbi.nlm.nih.gov/30138731/).
- Janssens GO, Gidding CEM, Van Lindert EJ, et al. The role of hypofractionation radiotherapy for diffuse intrinsic brainstem glioma in children: a pilot study. *Int J Radiat Oncol Biol Phys*. 2009; 73(3): 722–726, doi: [10.1016/j.ijrobp.2008.05.030](https://doi.org/10.1016/j.ijrobp.2008.05.030), indexed in Pubmed: [18990510](https://pubmed.ncbi.nlm.nih.gov/18990510/).
- Negretti L, Bouchireb K, Levy-Piedbois C, et al. Hypofractionated radiotherapy in the treatment of diffuse intrinsic pontine glioma in children: a single institution's experience. *J Neurooncol*. 2011; 104(3): 773–777, doi: [10.1007/s11060-011-0542-4](https://doi.org/10.1007/s11060-011-0542-4), indexed in Pubmed: [21327862](https://pubmed.ncbi.nlm.nih.gov/21327862/).
- Janssens GO, Jansen MH, Lauwers SJ, et al. Hypofractionation vs conventional radiation therapy for newly diagnosed diffuse intrinsic pontine glioma: a matched-cohort analysis. *Int J Radiat Oncol Biol Phys*. 2013; 85(2): 315–320, doi: [10.1016/j.ijrobp.2012.04.006](https://doi.org/10.1016/j.ijrobp.2012.04.006), indexed in Pubmed: [22682807](https://pubmed.ncbi.nlm.nih.gov/22682807/).
- Zaghloul MS, Nasr A, Tolba M, et al. Hypofractionated Radiation Therapy For Diffuse Intrinsic Pontine Glioma: A Noninferiority Randomized Study Including 253 Children. *Int J Radiat Oncol Biol Phys*. 2022; 113(2): 360–368, doi: [10.1016/j.ijrobp.2022.01.054](https://doi.org/10.1016/j.ijrobp.2022.01.054), indexed in Pubmed: [35150788](https://pubmed.ncbi.nlm.nih.gov/35150788/).
- Bailey S, Howman A, Wheatley K, et al. Diffuse intrinsic pontine glioma treated with prolonged temozolomide and radiotherapy—results of a United Kingdom phase II trial (CNS 2007 04). *Eur J Cancer*. 2013; 49(18): 3856–3862, doi: [10.1016/j.ejca.2013.08.006](https://doi.org/10.1016/j.ejca.2013.08.006), indexed in Pubmed: [24011536](https://pubmed.ncbi.nlm.nih.gov/24011536/).
- Reyes-Botero G, Mokhtari K, Martin-Duverneuil N, et al. Adult brainstem gliomas. *Oncologist*. 2012; 17(3): 388–397, doi: [10.1634/theoncologist.2011-0335](https://doi.org/10.1634/theoncologist.2011-0335), indexed in Pubmed: [22382458](https://pubmed.ncbi.nlm.nih.gov/22382458/).
- Rineer J, Schreiber D, Choi K, et al. Characterization and outcomes of infratentorial malignant glioma: a population-based study using the Surveillance Epidemiology and End-Results database. *Radiother Oncol*. 2010; 95(3): 321–326, doi: [10.1016/j.radonc.2010.04.007](https://doi.org/10.1016/j.radonc.2010.04.007), indexed in Pubmed: [20451276](https://pubmed.ncbi.nlm.nih.gov/20451276/).
- Salmaggi A, Fariselli L, Milanese I, et al. Associazione Italiana di Neuro-oncologia. Natural history and management of brainstem gliomas in adults. A retrospective Italian study. *J Neurol*. 2008; 255(2): 171–177, doi: [10.1007/s00415-008-0589-0](https://doi.org/10.1007/s00415-008-0589-0), indexed in Pubmed: [18293027](https://pubmed.ncbi.nlm.nih.gov/18293027/).

24. Theeler BJ, Ellezam B, Melguizo-Gavilanes I, et al. Adult brainstem gliomas: Correlation of clinical and molecular features. *J Neurol Sci.* 2015; 353(1-2): 92–97, doi: [10.1016/j.jns.2015.04.014](https://doi.org/10.1016/j.jns.2015.04.014), indexed in Pubmed: [25934342](https://pubmed.ncbi.nlm.nih.gov/25934342/).
25. Reyes-Botero G, Giry M, Mokhtari K, et al. Molecular analysis of diffuse intrinsic brainstem gliomas in adults. *J Neurooncol.* 2014; 116(2): 405–411, doi: [10.1007/s11060-013-1312-2](https://doi.org/10.1007/s11060-013-1312-2), indexed in Pubmed: [24242757](https://pubmed.ncbi.nlm.nih.gov/24242757/).