



Three-dimensional (3D) anatomic location, extension, and timing of severe osteoradionecrosis of the mandible

Lucas G. Sapienza¹, Justin J. Thomas¹, Weiyuan Mai^{1,2}, Alexander N. Hanaia¹, Sandeep Hunjan², Vlad C. Sandulache^{3,4}, Albert C. Chen^{1,2}

¹Department of Radiation Oncology, Dan L Duncan Comprehensive Cancer Center, Baylor College of Medicine, Houston, TX, United States

²Department of Radiation Oncology, Michael E. DeBakey Veterans Affairs Medical Center, Houston, TX, United States

³ENT Section — Operative Care Line, Michael E. DeBakey Veterans Affairs Medical Center, Houston, TX, United States

⁴Bobby R. Alford Department of Otolaryngology — Head and Neck Surgery, Baylor College of Medicine, Houston, TX, United States

ABSTRACT

Background: The purpose of this study was to describe the topography, extension (volume), and timing of severe osteoradionecrosis (ORN) that required mandible resection in patients previously treated for head and neck cancer at a high-volume Veterans Affairs Medical Center.

Materials and methods: The records from a reference hyperbaric oxygen clinic were retrospectively analyzed (n = 50, 2018–2021). Inclusion criteria were: I) severe ORN defined as progressive ORN that required resection; II) pathologic confirmation of ORN; and III) availability of pre-operative CT-imaging. Using a radiotherapy (RT) imaging software, we performed a detailed volumetric (3D) analysis of the bone involvement by ORN. Time intervals from RT to surgery for ORN and from surgery to the last follow-up were calculated.

Results: All patients that met inclusion criteria (n = 10) were male with significant smoking history (median 47.5 pack-years) and a median age of 57 years old at the time of RT. The primary tumors were: oropharynx (n = 6), oral cavity (n = 3) and nasopharynx (n = 1). The median time from RT to ORN surgery was 8 years. The most common ORN location was the posterior lateral body (molar) and six patients had associated fractures. The mean ORN volume was 3.6 cc (range: 0.6–8.3), corresponding to a mean 6.3% (range: 0.7–14) of the total mandibular volume. After a median follow-up of 13.5 months, no recurrence of ORN occurred. Three patients died of non-cancer and non-ORN-recurrence related causes (1 y OS 77.1%).

Conclusion: Severe ORN occurred after a median of 8 years from the previous RT and usually affected the posterior lateral body. Surgical resection achieved excellent ORN control.

Key words: head and neck cancer; radiotherapy; late toxicity

Rep Pract Oncol Radiother 2022;27(3):519–526

Introduction

Osteoradionecrosis (ORN) is a morbid complication of radiotherapy (RT) [1], especially when it affects the mandible. Currently, there is no consensus on how to grade the severity of this sequela, with mul-

iple classification systems available [2–5]. The majority highlight that ORN requiring an extended surgical resection [6] indicates a more advanced stage that is considered refractory to conservative treatments (e.g.: vitamin E, pentoxifylline) [7–8], hyperbaric oxygen (HBO) [9] or focal debridement [10].

Address for correspondence: Lucas G. Sapienza MD, PhD, 5925 Alameda Rd #11609, Houston, Texas, USA — 77004, tel: (346)228-0649; e-mail: Lucas.Sapienza@bcm.edu

This article is available in open access under Creative Common Attribution-Non-Commercial-No Derivatives 4.0 International (CC BY-NC-ND 4.0) license, allowing to download articles and share them with others as long as they credit the authors and the publisher, but without permission to change them in any way or use them commercially

Previous studies on ORN were limited to analyses of predisposing factors [11–14], which include patient characteristics, clinical presentation of the previous head and neck malignancy, and radiotherapy parameters. Although contributing to the risk of ORN, most of these factors are usually non-modifiable. In this setting, the knowledge of the natural history of the ORN cases that progress to late stages may provide more practical insights. These include identifying the mandible subsites most prone to severe ORN (which could guide more specific RT dose constraints), determining the necessary surveillance time frame to detect these severe cases, and assessing the effectiveness of mandibular resection.

Based on this background, the purpose of the current study is to describe the natural history, including the locations and extension of the lesions, of a retrospective series of ORN cases that required surgery from a high-volume Veterans Affairs Medical Center. In addition, we analyze the post-operative outcomes of the mandibular resection.

Materials and methods

Study design

To address the research purpose, the investigators designed and implemented a retrospective cohort study. The records from a reference hyperbaric oxygen clinic were triaged (December 2018 to February 2021). Inclusion criteria were: I) severe ORN (defined as progressive ORN that required resection); II) pathologic confirmation; and III) availability of pre-operative computed tomography (CT) imaging. Cases of osteoradionecrosis of other bones without mandibular involvement were excluded. Clinical and outcome information pertaining to these head and neck cancer patients were retrospectively extracted from the institutional electronic medical record system. The study followed the Declaration of Helsinki on medical protocol and ethics and the institutional review board (IRB) of the Michael E. DeBakey Veterans Affairs Medical Center approved this study design and the use of patient information without individual identification before study initiation.

Variables and data collection methods

The pre-operative CT scans of each patient were transferred from the radiology picture archiving

and communication system (PACS) to the radiation oncology cancer imaging software (Velocity Version 3.2.0, Varian Medical Systems, Palo Alto, CA, USA). The ORN was defined as the area of bone demineralization, without including the surrounding soft tissue alteration. The ORNs were analyzed in the cancer imaging software using the bone window (level: 250; range: -650 to 1350 Hounsfield units) by human evaluation/contouring (consensus of two radiation oncologists). The relative ORN volume was calculated by dividing the volume of the ORN measured in cubic centimeters by the total mandibular volume measured in cubic centimeters. All the ORNs were contoured and transferred to a model mandible (from a patient without ORN) to generate a topographic representation of the more frequently affected mandible subsites. For this process, rigid fusion was used instead of deformable, due to the destruction of the mandible contours caused by the ORN. The regions with 10%, 30% and 50% involvement by ORN were obtained by a series of Boolean operations. Finally, a 3-millimeter isometric margin was added to account for uncertainties of rigid image registration.

Data analysis

The date of the mandibulectomy was considered the event time for the initial severe ORN-free survival endpoint and the initial time for the other time to event endpoints (recurrent ORN-free survival, complication rate, and overall survival). Survival curves of these time-dependent endpoints were analyzed via the Kaplan-Meier method [15]. Due to normal distribution, the Student's *t*-test [16] was used to compare the means of the relative ORN volume between patients that underwent surgery before or after 6 years from the time of the initial cancer treatment. All statistical analyses were performed using IBM SPSS Statistics, Build 1.0.0.1508, Armonk, NY, USA.

Results

From the initial database ($n = 50$), ten patients met all the inclusion criteria. A detailed case selection diagram is presented in Supplementary File — Figure S1. All patients were male with current or former smoking history (median 47.5 pack-years; IQR: 19–132). The median age was 57 years (IQR: 51–64.5) at the time of RT and 70 years

(IQR: 63.5–73) at the time of ORN surgery. The primary tumor sites were oropharynx (n = 6), oral cavity (n = 3) and nasopharynx (n = 1). In relation to the initial cancer treatment, seven patients received definitive radiation doses to the primary tumor and involved nodes. One case received two courses of RT (initially definitive and after developing a recurrence two years later, adjuvant post-resection). Six cases received RT at other institutions. Table 1 describes additional patients and treatment characteristics. Details of previous RT dose or dental procedures were not available.

The mean ORN volume was 3.6 cc (range: 0.6–8.3), corresponding to a mean 6.3% (range: 0.7–14) of the total mandibular volume. The subsite of the mandible most commonly affected by the ORN was the posterior lateral body (molar region) as seen in Figure 1. Only two cases had RT plans available for analysis. These cases (I–II) are represented in Figure 2. The 70 Gy isodose line (red) involved multiple parts of the mandible (A: ramus; B: lateral posterior body; C: anterior body), but the ORN occurred only in the lateral posterior body (B). Six cases had associated fractures, which were also located in the molar region. The median time from the RT to the ORN surgery was 8.6 years (range: 1–16) (Fig. 3). The proportion of mandible involved in the cases that underwent surgery before and after 6 years from the cancer treatment were 2.8% and 8.6%, respectively (mean, $p = 0.025$). Fractures were associated with 1 of 4 early-onset cases (before 6 years) and 5 of 6 late-onset cases (after 6 years).

Regarding the mandibulectomy, segmental removal (n = 6) and bone reconstruction (5 fibular, 1 scapular) were the most common procedures performed. Total, hemi-, and marginal mandibulectomy were used in 10%, 20% and 10% of the cases, respectively. Figure 4 displays the pre-operative axial CT, post-operative axial CT, and post-operative digitally reconstructed radiography (DRR) of four cases (cases 1–4) that required segmental mandibulectomy. The images of the remaining six cases (case 5–10) are shown in Supplementary File — Figure S2.

After a median follow-up of 13.5 months, no patient had a recurrence of ORN. Three patients had complications related to the surgery: one had hardware exposed in the oral cavity, another had bilateral temporo-mandibular joint dis-

Table 1. Patient and treatment characteristics

Variable	N (%)
Sex	
Male	10 (100%)
Female	0 (0%)
Smoking history	
Current	2 (20%)
Former	8 (80%)
Never	0 (0%)
Primary H&N cancer	
Oropharynx	6 (60%)
Oral cavity	3 (30%)
Nasopharynx	1 (10%)
Laterality of tumor	
Right	6 (60%)
Left	2 (20%)
NA	2 (20%)
Tumor stage	
T2	2 (20%)
T3	2 (20%)
T4	1 (10%)
NA	5 (50%)
Nodal stage	
N0	2 (20%)
N1	0 (0%)
N2	3 (30%)
NA	5 (50%)
RT intent	
Definitive (D)	7 (70%)
Adjuvant (A)	2 (20%)
D → A (recurrence)	1 (10%)
Concurrent chemotherapy	
No	2 (20%)
Yes	6 (60%)
NA	2 (20%)
Dentition status*	
Edentulous	4 (40%)
Possessing teeth	6 (60%)
Associated fracture	
No	4 (40%)
Yes	6 (60%)
ORN surgery	
Total mandibulectomy	1 (10%)
Hemi-mandibulectomy	2 (20%)
Segmental mandibulectomy	6 (60%)
Marginal mandibulectomy	1 (10%)



Table 1. Patient and treatment characteristics

Variable	N (%)
Bone reconstruction	
No	4 (40%)
Yes	6 (60%)
Fibula	5 (50%)
Scapula tip	1 (10%)

H&N — head and neck; RT — radiotherapy; ORN — osteoradionecrosis; NA — not available; *dental status at the time of ORN resection

location requiring reduction in the operating room, and the last had a right lower limb ischemia with concomitant non-ST segment myocardial infarction (NSTEMI) four days after the ORN operation. This last patient died after 2 months in the intensive care unit. The 1y complication rate was 32.5% (Fig. 5A), with all events occurring within 6 months post-operation. Three patients died of non-cancer and non-ORN-recurrence related causes (1 y OS 77.1%, Fig. 5B).

Discussion

The risk factors for ORN [12–14, 17], such as the RT dose to the whole or to a non-anatomically defined proportion of the mandible [18–19], do not fully explain the occurrence of severe ORN events. Different mandibular topographies may range in

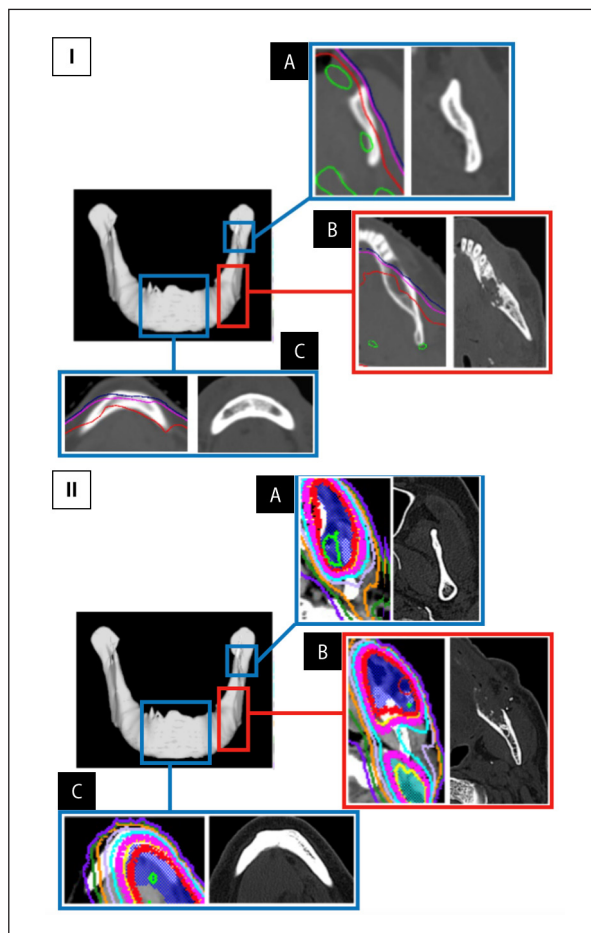


Figure 2. Radiation isodose-lines and location of the fracture in two cases (I and II). **A.** Ramus; **B.** Lateral posterior body; **C.** Anterior body. Red line: 70 Gy isodose

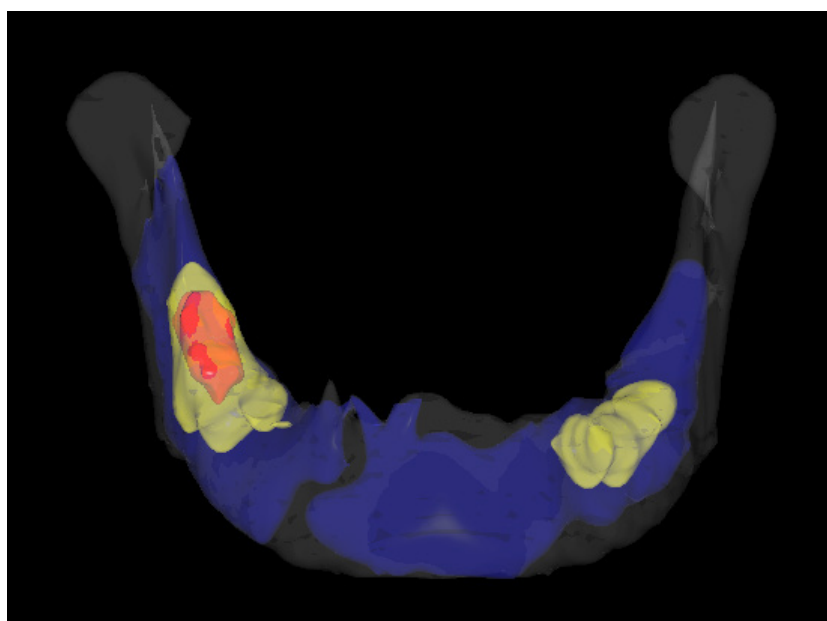


Figure 1. Topographic representation of the affected mandible subsites (iso-frequency volumes). Blue: 10% rate. Yellow: 30% rate. Red: 50% rate

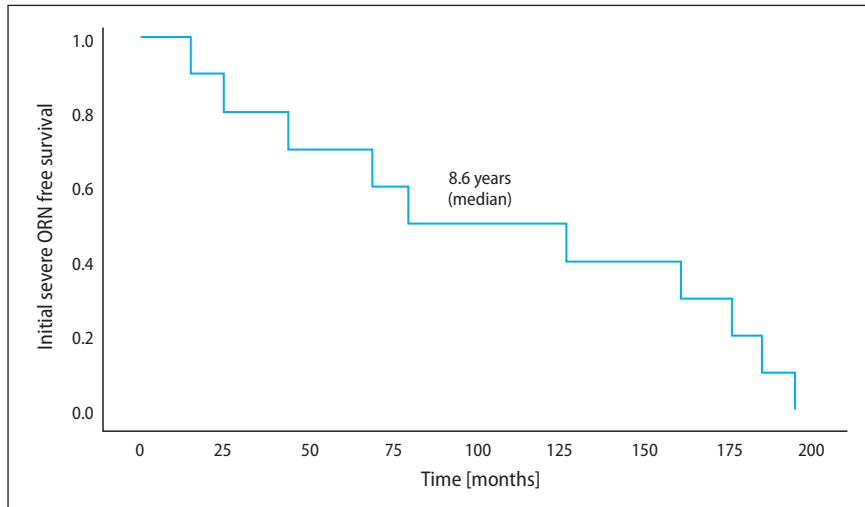


Figure 3. Initial severe osteoradionecrosis (ORN)-free-survival post-radiation therapy (T0)

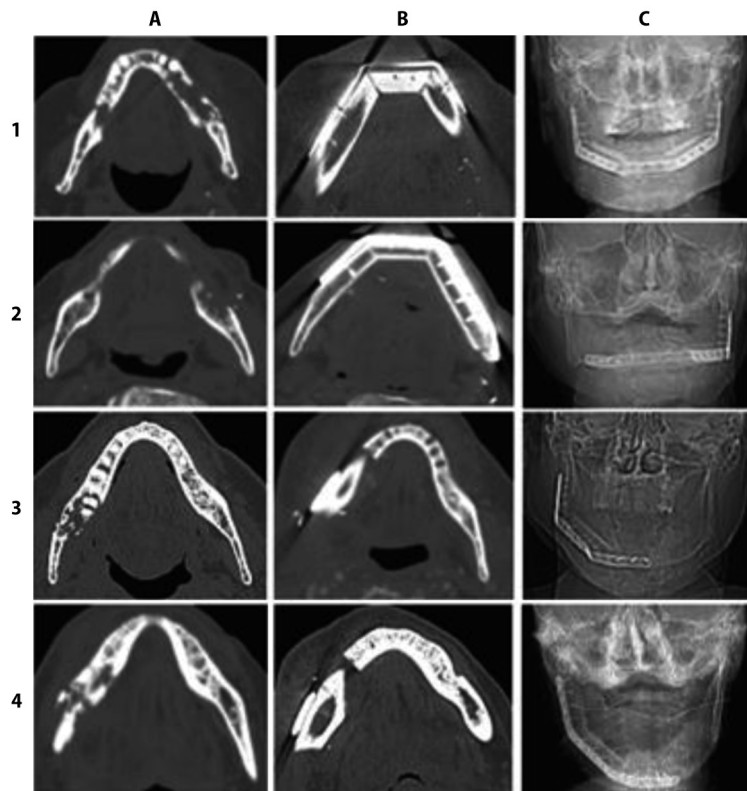


Figure 4. Four illustrative cases (1–4) with mandible resection. Images of pre-operative CT (A), post-operative CT (B), and post-operative digital reconstructed radiography (C).

Case 1 — 70-year-old* male with severe osteoradionecrosis (ORN) with fracture 15.5 years after definitive radiotherapy (RT) for oropharynx cancer (base of tongue). Treated with segmental mandibulectomy with reconstruction (fibula).

Case 2 — 75-year-old* male with severe ORN with fracture 1.3 year after adjuvant RT for oral cavity cancer (left side). Treated with segmental mandibulectomy with reconstruction (fibula).

Case 3 — 72-year-old* male with severe ORN with fracture 10.7 years after definitive RT for oropharynx cancer (right tonsil). Treated with segmental mandibulectomy with reconstruction (fibula).

Case 4 — 70-year-old* male with severe ORN with fracture 6.8 years after definitive RT for oral cavity cancer (right side). Treated with segmental mandibulectomy with reconstruction (fibula).

*At the time of mandibulectomy to treat ORN.

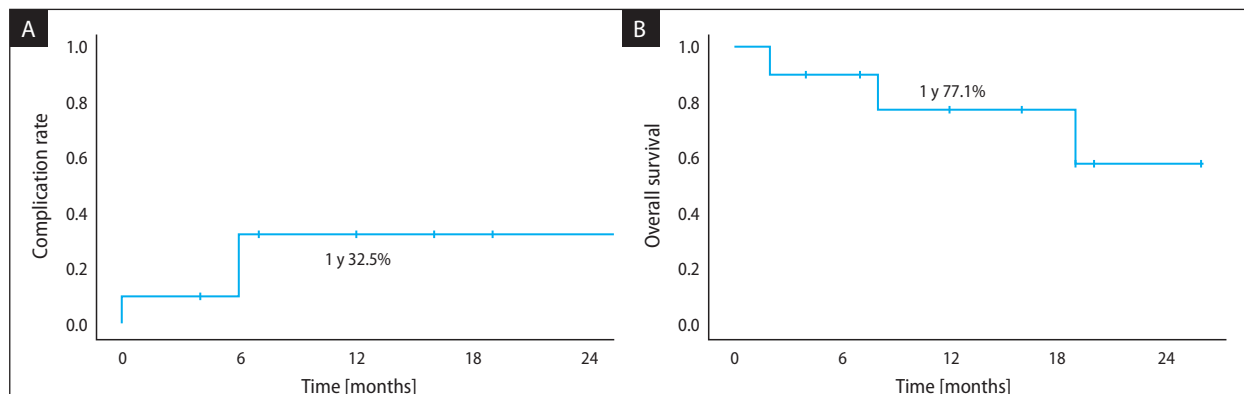


Figure 5. Kaplan Meier curves for (A) complication rate and (B) overall survival after mandible resection

their proclivity for the development of severe ORN. In this regard, our study found that the posterior lateral mandible body — the region that supports the highest-pressure forces during mastication and that also precedes the division of the terminal branches (lingual, mental, and incisor) of the inferior alveolar artery (IAA) — was the most affected region. Two studies [20–21] have previously suggested that the most common location of the ORN (any grade) is the mandible body, however, they did not specify the precise sub-region at higher risk of severe destruction. Based on our data, the molar region is a potential target for preventive measures, such as stricter radiation dose constraints or selective pre-irradiation dental extractions.

Besides anatomic location, prolonged time with devitalized mandibular bone also seems to be an important factor for this complication. Most of the cases in the present study presented with severe ORN later during the follow-up period, with half of cases undergoing surgery after 10 years. In the same direction, Caparrotti et al. [22] showed that ORN can occur even beyond 5 years after completing intensity-modulated radiotherapy (IMRT) in a cohort of oropharynx cancer patients. Notani et al. [5] described the association between late ORN onset and more advanced stage, with no case of grade I (confined to the alveolar bone) ORN when the complication developed after 36 months. In our series, more extensive bone involvement and associated fractures were detected in the cases that underwent extensive ORN surgery after more than 6 years from the previous cancer treatment. Taken in conjunction, these findings reinforce the importance of prolonged cancer survivorship programs to detect and treat this possible morbid complica-

tion. Of note, recent advances indicate that CT [23] and nuclear magnetic resonance imaging [24] radiomics are promising tools to guide early detection of radiation-induced changes in the bone.

After therapeutic resection of the mandible, no further ORN recurrences were detected. Extensive resections with immediate reconstructions using bone from a non-irradiated donor area improves functional and aesthetic outcomes at a cost of increased procedure length and complexity. The analysis of the complication events (nearly 1/3 of cases in 1 year) provides important insights. The case with a post-op myocardial infarction highlights the importance of judicious pre-operative evaluation of surgical risks since many patients have substantial cardiovascular risk due to their smoking history [25]. The other two cases with hardware exposure in the oral cavity and with bilateral temporo-mandibular joint dislocation indicates that there is opportunity for improvement in the reconstruction techniques, such as the use of osteomyocutaneous peroneal artery-based combined flap [26] for massive defects instead of double free flaps [27] when appropriate after surgeon evaluation.

The main limitation of our study is the limited number of patients, which is due to the rarity of late stage ORN. These severe cases are usually referred to tertiary centers with expertise to perform extensive mandible resections and reconstructions. To illustrate that, six cases of the current study were referred from outside institutions to manage the actinic complication. The lack of detailed data on the previous RT and dental procedures is a consequence of this pattern of referral. Finally, we could not perform deformable

image registrations of the affected mandibles with the model mandible due to the destruction of the mandible contours from ORN. To overcome potential uncertainties of rigid image registrations, we added an isometric 3-millimeter margin to our ORN regions to represent the final diagram with the most affected regions.

The precise pathophysiology of ORN is unknown. It is likely a multifactorial phenomenon, including vascular changes [23], bone hypoxia [28], actinic fibrosis [29] and associated infection [30]. Although absorbed radiation dose is certainly a relevant predisposing factor for the ORN, especially for the early events, our study suggests that subsites of the mandible body have variable propensities for developing severe ORN and fractures in the long term. Of note, the two cases with available dosimetric data had high radiation doses (≥ 70 Gy) to multiple sites of the mandible, but severe ORN only occurred in the molar area. Further studies evaluating constraints to specific sub-regions of the mandible (in particular, the molar area) are warranted.

Conclusions

In summary, severe ORN can present late in the surveillance period (> 8 years from original cancer treatment), and it involves the posterior lateral mandible body region in most cases. Mandible resection provides excellent control of the lesions with a moderate rate of complications.

Conflicts of interest

None declared.

Funding

None declared.

Data availability statement

Research data are stored in an institutional repository and will be shared upon request to the corresponding author.

Acknowledgements

We thank David Hernandez, MD and Andrew Huang, MD, FACS from the ENT Section — Operative Care Line, Michael E. DeBakey Veterans Affairs Medical Center, Houston, TX, USA for performing the surgical procedures.

References

1. Regaud C. Sur la nécrose des os atteints par un processus cancéreux et traités par les radiations. *Compt Rend Soc Biol.* 1922; 87: 629.
2. Epstein JB, Wong FL, Stevenson-Moore P. Osteoradionecrosis: clinical experience and a proposal for classification. *J Oral Maxillofac Surg.* 1987; 45(2): 104–110, indexed in Pubmed: [3468211](#).
3. Glanzmann C, Grätz KW. Radionecrosis of the mandibula: a retrospective analysis of the incidence and risk factors. *Radiother Oncol.* 1995; 36(2): 94–100, doi: [10.1016/0167-8140\(95\)01583-3](#), indexed in Pubmed: [7501817](#).
4. Schwarts HC, Kagan A. Osteoradionecrosis of the mandible: scientific basis for clinical staging. *Am J Clin Oncol.* 2002; 25(2): 168–171, doi: [10.1097/0000421-200204000-00013](#), indexed in Pubmed: [11943896](#).
5. Notani KI, Yamazaki Y, Kitada H, et al. Management of mandibular osteoradionecrosis corresponding to the severity of osteoradionecrosis and the method of radiotherapy. *Head Neck.* 2003; 25(3): 181–186, doi: [10.1002/hed.10171](#), indexed in Pubmed: [12599284](#).
6. Celik N, Wei F, Chen H, et al. Osteoradionecrosis of the mandible after oromandibular cancer surgery. *Plast Reconstr Surg.* 2002; 109(6): 1875–1881, doi: [10.1097/00006534-200205000-00014](#), indexed in Pubmed: [11994586](#).
7. Delanian S, Chatel C, Porcher R, et al. Complete restoration of refractory mandibular osteoradionecrosis by prolonged treatment with a pentoxifylline-tocopherol-clodronate combination (PENTOCLO): a phase II trial. *Int J Radiat Oncol Biol Phys.* 2011; 80(3): 832–839, doi: [10.1016/j.ijrobp.2010.03.029](#), indexed in Pubmed: [20638190](#).
8. Kolokythas A, Rasmussen JT, Reardon J, et al. Management of osteoradionecrosis of the jaws with pentoxifylline-tocopherol: a systematic review of the literature and meta-analysis. *Int J Oral Maxillofac Surg.* 2019; 48(2): 173–180, doi: [10.1016/j.ijom.2018.08.007](#), indexed in Pubmed: [30205911](#).
9. Mounsey RA, Brown DH, O'Dwyer TP, et al. Role of hyperbaric oxygen therapy in the management of mandibular osteoradionecrosis. *Laryngoscope.* 1993; 103(6): 605–608, doi: [10.1288/00005537-199306000-00005](#), indexed in Pubmed: [8502093](#).
10. Li Z, Liu S, Xie S, et al. Advanced osteoradionecrosis of the maxilla: a 15-year, single-institution experience of surgical management. *Acta Otolaryngol.* 2020; 140(12): 1049–1055, doi: [10.1080/00016489.2020.1812714](#), indexed in Pubmed: [32921212](#).
11. Withers H, Peters L, Taylor J, et al. Late normal tissue sequelae from radiation therapy for carcinoma of the tonsil: Patterns of fractionation study of radiobiology. *Int J Radiat Oncol Biol Phys.* 1995; 33(3): 563–568, doi: [10.1016/0360-3016\(95\)00229-r](#), indexed in Pubmed: [7558944](#).
12. Tsai CJ, Hofstede TM, Sturgis EM, et al. Osteoradionecrosis and radiation dose to the mandible in patients with oropharyngeal cancer. *Int J Radiat Oncol Biol Phys.* 2013; 85(2): 415–420, doi: [10.1016/j.ijrobp.2012.05.032](#), indexed in Pubmed: [22795804](#).
13. Khoo SC, Nabil S, Fauzi AA, et al. Predictors of osteoradionecrosis following irradiated tooth extraction. *Radiat Oncol.* 2021; 16(1): 130, doi: [10.1186/s13014-021-01851-0](#), indexed in Pubmed: [34261515](#).

14. Kubota H, Miyawaki D, Mukumoto N, et al. Risk factors for osteoradionecrosis of the jaw in patients with head and neck squamous cell carcinoma. *Radiat Oncol.* 2021; 16(1): 1, doi: [10.1186/s13014-020-01701-5](https://doi.org/10.1186/s13014-020-01701-5), indexed in Pubmed: [33402192](https://pubmed.ncbi.nlm.nih.gov/33402192/).
15. Kaplan EL, Meier P. Nonparametric estimation from incomplete observations. *J Am Stat Assoc.* 1958; 53: 457–81.
16. Gosset WS. "Student". The probable error of a mean. *Biometrika.* 1908; 6(1): 1–25.
17. Owosho AA, Tsai CJ, Lee RS, et al. The prevalence and risk factors associated with osteoradionecrosis of the jaw in oral and oropharyngeal cancer patients treated with intensity-modulated radiation therapy (IMRT): The Memorial Sloan Kettering Cancer Center experience. *Oral Oncol.* 2017; 64: 44–51, doi: [10.1016/j.oraloncology.2016.11.015](https://doi.org/10.1016/j.oraloncology.2016.11.015), indexed in Pubmed: [28024723](https://pubmed.ncbi.nlm.nih.gov/28024723/).
18. MD Anderson Head and Neck Cancer Symptom Working Group. Dose-volume correlates of mandibular osteoradionecrosis in Oropharynx cancer patients receiving intensity-modulated radiotherapy: Results from a case-matched comparison. *Radiother Oncol.* 2017; 124(2): 232–239, doi: [10.1016/j.radonc.2017.06.026](https://doi.org/10.1016/j.radonc.2017.06.026), indexed in Pubmed: [28733053](https://pubmed.ncbi.nlm.nih.gov/28733053/).
19. van Dijk LV, Abusaif AA, Rigert J, et al. Normal tissue complication probability (NTCP) prediction model for osteoradionecrosis of the mandible in patients with head and neck cancer after radiation therapy: a large-scale observational cohort. *Int J Radiat Oncol Biol Phys.* 2021; 111(2): 549–558, doi: [10.1016/j.ijrobp.2021.04.042](https://doi.org/10.1016/j.ijrobp.2021.04.042), indexed in Pubmed: [33965514](https://pubmed.ncbi.nlm.nih.gov/33965514/).
20. Thorn JJ, Hansen HS, Specht L, et al. Osteoradionecrosis of the jaws: clinical characteristics and relation to the field of irradiation. *J Oral Maxillofac Surg.* 2000; 58(10): 1088–1093, doi: [10.1053/joms.2000.9562](https://doi.org/10.1053/joms.2000.9562), indexed in Pubmed: [11021701](https://pubmed.ncbi.nlm.nih.gov/11021701/).
21. Schuster T, Mende U, Kübler A. Osteoradionecrosis of the jaws as a side effect of radiotherapy of head and neck tumours patients — a report of a thirty year retrospective review. *Int J Oral Maxillofac Surg.* 2003; 32(3): 289–295, doi: [10.1054/ijom.2002.0332](https://doi.org/10.1054/ijom.2002.0332), indexed in Pubmed: [12767877](https://pubmed.ncbi.nlm.nih.gov/12767877/).
22. Caparrotti F, Huang SH, Lu L, et al. Osteoradionecrosis of the mandible in patients with oropharyngeal carcinoma treated with intensity-modulated radiotherapy. *Cancer.* 2017; 123(19): 3691–3700, doi: [10.1002/cncr.30803](https://doi.org/10.1002/cncr.30803), indexed in Pubmed: [28608925](https://pubmed.ncbi.nlm.nih.gov/28608925/).
23. Barua S, Elhalawani H, Volpe S, et al. Computed tomography radiomics kinetics as early imaging correlates of osteoradionecrosis in oropharyngeal cancer patients. *Front Artif Intell.* 2021; 4(618469), doi: [10.3389/frai.2021.618469](https://doi.org/10.3389/frai.2021.618469), indexed in Pubmed: [33898983](https://pubmed.ncbi.nlm.nih.gov/33898983/).
24. Mohamed ASR, He R, Ding Y, et al. Joint Head and Neck Radiation Therapy-MRI Development Cooperative.. Quantitative dynamic contrast-enhanced MRI identifies radiation-induced vascular damage in patients with advanced osteoradionecrosis: results of a prospective study. *Int J Radiat Oncol Biol Phys.* 2020; 108(5): 1319–1328, doi: [10.1016/j.ijrobp.2020.07.029](https://doi.org/10.1016/j.ijrobp.2020.07.029). *Epub 2020 Jul 23*, indexed in Pubmed: [32712257](https://pubmed.ncbi.nlm.nih.gov/32712257/).
25. Price JF, Mowbray PI, Lee AJ, et al. Relationship between smoking and cardiovascular risk factors in the development of peripheral arterial disease and coronary artery disease: Edinburgh Artery Study. *Eur Heart J.* 1999; 20(5): 344–353, doi: [10.1053/euhj.1998.1194](https://doi.org/10.1053/euhj.1998.1194), indexed in Pubmed: [10206381](https://pubmed.ncbi.nlm.nih.gov/10206381/).
26. Cheng MH, Saint-Cyr M, Ali RS, et al. Osteomyocutaneous peroneal artery-based combined flap for reconstruction of composite and en bloc mandibular defects. *Head Neck.* 2009; 31(3): 361–370, doi: [10.1002/hed.20969](https://doi.org/10.1002/hed.20969), indexed in Pubmed: [19073007](https://pubmed.ncbi.nlm.nih.gov/19073007/).
27. Gabr E, Kobayashi MR, Salibian AH, et al. Mandibular reconstruction: are two flaps better than one? *Ann Plast Surg.* 2004; 52(1): 31–35, doi: [10.1097/01.sap.0000099819.90674.c6](https://doi.org/10.1097/01.sap.0000099819.90674.c6), indexed in Pubmed: [14676696](https://pubmed.ncbi.nlm.nih.gov/14676696/).
28. Leach RM, Ress PJ, Wilmshurst P. ABC of oxygen: hyperbaric oxygen therapy. *BMJ.* 1998; 317(7166): 1140–1143, doi: [10.1136/bmj.317.7166.1140](https://doi.org/10.1136/bmj.317.7166.1140), indexed in Pubmed: [1114115](https://pubmed.ncbi.nlm.nih.gov/1114115/).
29. Lyons A, Ghazali N. Osteoradionecrosis of the jaws: current understanding of its pathophysiology and treatment. *Br J Oral Maxillofac Surg.* 2008; 46(8): 653–660, doi: [10.1016/j.bjoms.2008.04.006](https://doi.org/10.1016/j.bjoms.2008.04.006), indexed in Pubmed: [18562055](https://pubmed.ncbi.nlm.nih.gov/18562055/).
30. Marx RE. Osteoradionecrosis: a new concept of its pathophysiology. *J Oral Maxillofac Surg.* 1983; 41(5): 283–288, doi: [10.1016/0278-2391\(83\)90294-x](https://doi.org/10.1016/0278-2391(83)90294-x), indexed in Pubmed: [6572704](https://pubmed.ncbi.nlm.nih.gov/6572704/).