



## Refractory Riedel's thyroiditis managed with low dose radiotherapy

Anna Lawless<sup>1,4</sup>, Alexander Papachristos<sup>2</sup>, Bruce Robinson<sup>3,5</sup>, Stanley Sidhu<sup>2,4,5</sup>, Thomas Eade<sup>1,4</sup>

<sup>1</sup>Department of Radiation Oncology, Royal North Shore Hospital, NSW, Australia

<sup>2</sup>Department of Endocrine Surgery, Royal North Shore Hospital, NSW, Australia

<sup>3</sup>Department of Endocrinology, Royal North Shore Hospital, NSW, Australia

<sup>4</sup>Faculty of Medicine and Health, The University of Sydney, NSW, Australia

<sup>5</sup>Kolling Institute of Medical Research, Royal North Shore Hospital, NSW, Australia

**Key words:** thyroid cancer; radiotherapy; inflammation

*Rep Pract Oncol Radiother* 2022;27(3):591–592

Riedel's thyroiditis (RT) is characterised by locally aggressive fibromatosis. Typical presentation is with a hard, fixed, non-tender goitre. Increasing fibrotic 'invasion' of surrounding structures can cause pain and compressive symptoms. Most patients are euthyroid [1].

Due to its rarity, the literature lacks evidence-based treatment algorithms. Glucocorticoids are mainstay of treatment, with tamoxifen often used second line. Use of rituximab or mycophenolate is described in case reports [1, 2]. Surgery can provide diagnosis or relieve tracheal compression, but resection is usually not possible due to involvement of adjacent structures [1].

Orbital radiotherapy is as effective as systemic corticosteroids for the treatment of acute thyroid orbitopathy (TRO) and may potentiate their benefits [3]. We postulated it may have a similar effect in RT, due to similar underlying inflammatory pathophysiology.

This article describes the first reported case of symptomatic, refractory RT managed with low dose radiotherapy.

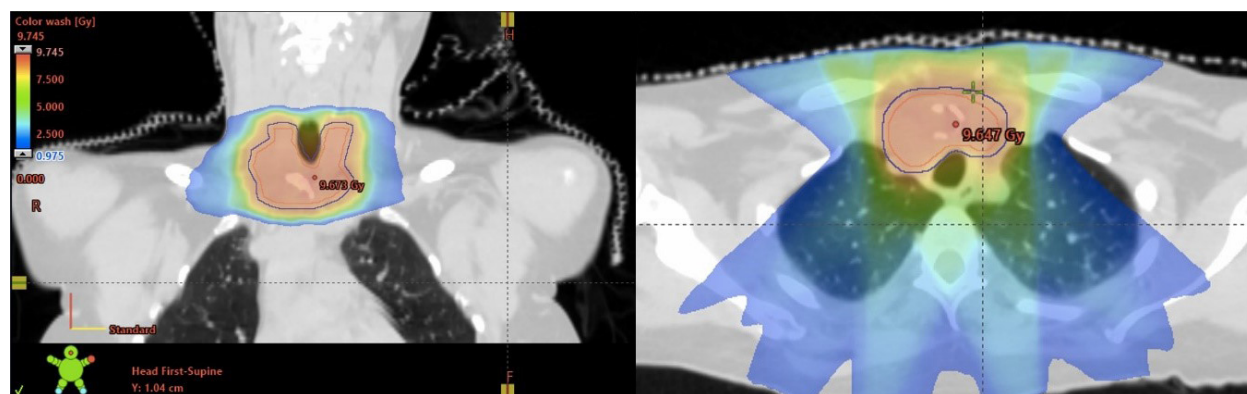
A 36-year-old female with no significant past medical history presented with painful mid-line neck swelling, dysphagia, dyspnoea, and stridor. Bloodwork including thyroid function tests were normal. Thyroid ultrasound and CT revealed large multinodular goitre with a heterogenous calcified mass arising from the right lower pole (right lobe 7.7 cm, left lobe 5.8 cm), with retrosternal extension, tracheal compression, and deviation.

Total thyroidectomy was planned for the presumed compressive, non-functioning multinodular goitre. Intra-operatively, there was infiltration of adjacent sternothyroid muscle, oesophagus, and trachea. The woody consistency and local invasion raised the suspicion of RT. Biopsy was performed, and thyroidectomy abandoned. Histopathology revealed inflamed fibrous tissue, with keloid appearance, entrapping thyroid follicles and adjacent skeletal muscle, without evidence of malignancy. Review by two pathologists confirmed the diagnosis of RT.

Prednisone and multimodal analgesia were commenced, but with minimal improvement after three

**Address for correspondence:** Prof. Thomas Eade, Northern Sydney Cancer Institute, Royal North Shore Hospital, St Leonards, NSW, Australia; e-mail: Thomas.eade@health.nsw.gov.au

This article is available in open access under Creative Common Attribution-Non-Commercial-No Derivatives 4.0 International (CC BY-NC-ND 4.0) license, allowing to download articles and share them with others as long as they credit the authors and the publisher, but without permission to change them in any way or use them commercially



**Figure 1.** Radiotherapy plan

weeks. Pulsed intravenous methylprednisone was also unsuccessful. Tamoxifen was trialed, but after six weeks the patient remained symptomatic. Following discussion at an institutional endocrinology multidisciplinary meeting, a trial of low dose radiotherapy was offered.

Radiotherapy was delivered to the thyroid gland to a total dose of 9 Gray in 5 daily fractions, using volumetric modulated arc therapy technique (Fig. 1). Treatment was well tolerated, with no acute adverse events.

Within eight weeks, severity of pain had reduced by 50%, and prednisone ceased. CT demonstrated 67% reduction in thyroid volume (102mL to 34mL), and increased tracheal diameter (7 mm to 16 mm, Supplementary File — Fig. S1). The patient remained euthyroid.

Due to partial response after four months, a second course of radiotherapy was undertaken. Further reduction in pain was achieved within four weeks. CT revealed additional mild reduction in thyroid size (50 mm diameter, previously 56 mm).

Treatment was well tolerated, likely due to low total dose and dose per fraction. Long term follow up will be required to determine the durability of response and assess for late toxicities.

This case reports a young woman with symptomatic RT, refractory to steroids and tamoxifen, who had a clinical and radiological response to low dose radiotherapy, warranting its consideration in the management of refractory RT.

#### Conflicts of interest

None declared.

#### Funding

None declared.

#### Ethics

Deemed exempt by Northern Sydney Local Health District Human Research Ethics Committee.

#### References

1. Hennessey JV. Clinical review: Riedel's thyroiditis: a clinical review. *J Clin Endocrinol Metab.* 2011; 96(10): 3031–3041, doi: [10.1210/jc.2011-0617](https://doi.org/10.1210/jc.2011-0617), indexed in Pubmed: [21832114](https://pubmed.ncbi.nlm.nih.gov/21832114/).
2. Soh SB, Pham A, O'Hehir RE, et al. Novel use of rituximab in a case of Riedel's thyroiditis refractory to glucocorticoids and tamoxifen. *J Clin Endocrinol Metab.* 2013; 98(9): 3543–3549, doi: [10.1210/jc.2012-4050](https://doi.org/10.1210/jc.2012-4050), indexed in Pubmed: [23824414](https://pubmed.ncbi.nlm.nih.gov/23824414/).
3. Gontarz-Nowak K, Szychlińska M, Matuszewski W, et al. Current Knowledge on Graves' Orbitopathy. *J Clin Med.* 2020; 10(1), doi: [10.3390/jcm10010016](https://doi.org/10.3390/jcm10010016), indexed in Pubmed: [33374706](https://pubmed.ncbi.nlm.nih.gov/33374706/).