



Case report

Octreotide in the treatment of malignant thymoma – Case report

Ondrej Sorejs^{a,b}, Milos Pesek^c, Jindrich Finek^a, Ondrej Fiala^{a,b,*}

^a Department of Oncology and Radiotherapy, Medical School and Teaching Hospital Pilsen, Charles University Prague, Czech Republic

^b Biomedical Center, Faculty of Medicine in Pilsen, Charles University in Prague, Czech Republic

^c Department of Pneumology, Medical School and Teaching Hospital Pilsen, Charles University Prague, Czech Republic

ARTICLE INFO

Article history:

Received 2 April 2020

Received in revised form 15 July 2020

Accepted 17 August 2020

Available online 25 August 2020

Keywords:

Thymoma

Octreotide

Treatment

Somatostatin analog

Case report

ABSTRACT

Thymomas are the most common mediastinal tumors. Systemic therapy for patients with unresectable or recurrent thymomas is a challenging field in the current oncology research. There is some evidence that somatostatin analogs combined with corticosteroids may have a role in the treatment of advanced malignant thymoma; however, the role of these agents have not been fully evaluated.

Case report: A 39-year-old man with metastatic thymoma was administered long-acting depot injection form of octreotide. Octreotide scan before the treatment initiation revealed low uptake. CT control after three months of the treatment revealed marked regression of pleural metastases, while the primary tumor mass remained stable. The treatment response was lasting for 9 months.

Conclusion: We describe an interesting case of marked clinical and radiological response of advanced malignant thymoma to the treatment with octreotide in a heavily pre-treated patient, even though octreotide scan revealed low uptake.

© 2020 Greater Poland Cancer Centre. Published by Elsevier B.V. All rights reserved.

1. Introduction

Thymomas are the most common mediastinal tumors representing approximately 20% of all mediastinal tumors and more than 50% of anterior mediastinal tumors.¹ They are epithelial tumors associated with a lymphoid component and, mostly, tend to grow slowly, but show a potential for local invasion, pleural dissemination, and even systemic metastases. The treatment strategy depends on the stage, which is usually based on the Masaoka staging system.² The majority of thymoma cases are encapsulated or non-invasive tumors that can usually be cured by surgical resection, eventually followed by radiotherapy. Patients with unresectable or recurrent thymomas are considered for a systemic therapy. The choice of systemic treatment has been a challenging task because the data from prospective clinical trials are limited.^{3,4} There is some evidence that somatostatin analogs combined with corticosteroids may have a role in the treatment; however, it has not been fully evaluated.^{5–8} We report a case of a heavily pre-treated patient with metastatic malignant thymoma with pleural dissemination who was effectively treated with long-acting octreotide and methylprednisolone.

* Corresponding author at: Department of Oncology and Radiotherapy, Medical School and Teaching Hospital Pilsen, Charles University Prague, alej Svobody 80, CZ-304 60 Pilsen, Czech Republic.

E-mail address: fiala.o@centrum.cz (O. Fiala).

2. Case report

In May 2007, a 39-year-old patient came to the hospital with the initial symptoms of cough and runny nose. A chest X-ray showed a non-specific obscuration. Bronchoscopy did not show any pathological findings. An extensive polycyclic-shaped tumor formation with central annular calcifications originating from the ventral middle mediastinum and multiple pleural dissemination on the right side and one metastatic lesion in the upper lobe of the right lung were revealed by computed tomography (CT). Subsequently, a core biopsy was done under a CT control and histologically verified as a malignant thymoma, type B2 WHO classification. Clinical stage was classified as III according to the Masaoka staging system. The patient underwent two cycles of chemotherapy containing cisplatin and etoposide, which was switched to the regimen containing adriamycin, cisplatin, vincristine and cyclophosphamide (ADOC). In September 2007, after 6 cycles of chemotherapy, a CT control showed partial regression. Thereafter, the patient underwent an unsuccessful attempt at surgical debulking of the tumor followed by concurrent chemo-radiotherapy (50.4 Gy to the primary tumor and mediastinal lymph nodes combined with weekly cisplatin in a dose of 40 mg/m²) which was finished in March 2008. Following the chemo-radiotherapy, a CT control showed a partial tumor regression. In April 2009, a new tumor lesion in the right lung was described on a CT and the patient was re-administered five cycles of ADOC regimen achieving disease stabilisation. In

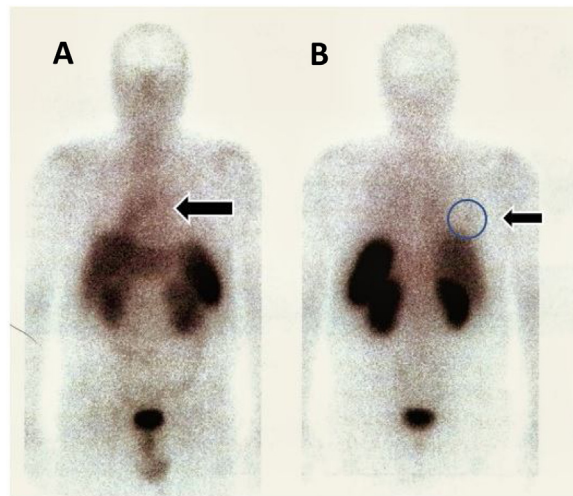


Fig. 1. Octreotide scan before octreotide treatment. It can be seen that there is low uptake in the tumor (A) and pleural metastasis (B) indicated by arrows. This is partly due to the low concentration of somatostatin receptors in the tumor.

January 2010, a CT control revealed progression with metastases in mediastinal lymph nodes and octreotide scan revealed a low uptake in the tumor masses (Fig. 1). The patient was once more re-administered four cycles of initially effective ADOC regimen resulting in a moderate regression of mediastinal lymphadenopathy. In September 2010, a CT control revealed progression and the patient was re-administered six cycles of cisplatin and etoposide achieving disease stabilization. In May 2011, a CT control revealed further disease progression and the treatment with combination of somatostatin analog and corticosteroid was initiated. The patient was administered a long-acting depot injection form of octreotide (Sandostatin LAR) at a dose of 20 mg administered every 4 weeks intramuscularly and oral methylprednisolone (Medrol) at a dose of 32 mg daily. In July 2011, a CT control revealed marked regression of pleural metastases, while the primary tumor mass remained stable (Fig. 2). The treatment was accompanied with steroid diabetes, when the daily dose of methylprednisolone was reduced to 24 mg, which was tolerated well. Apart from the symptoms associated with steroid diabetes, the patient did not have any other symptoms. In January 2012, a CT control revealed progression and the treatment was ended. Subsequently, the patient was treated with six cycles of docetaxel and due to the progression of the subpleural lesion on a CT control, the treatment was switched to gemcitabine. After three cycles of gemcitabine, a CT control revealed further progression in April 2014. As no other type of treatment could be offered to the patient, only a basic supportive care was indicated. In February 2015 the patient died.

3. Discussion

Current therapeutic options for systemic treatment of patients with advanced malignant thymoma are limited. The efficacy of somatostatin analogs in advanced malignant thymoma has not been fully elucidated and large randomized clinical trials are still missing. Palmieri et al. previously published results from a

study focusing on this interesting topic. The study enrolled sixteen patients with advanced malignant thymoma who were treated with somatostatin analogs, the overall response rate was 37%, the median survival was 15 months, and median time to progression was 14 months. Previously, it used to be thought that only tumors expressing somatostatin receptors respond to somatostatin analogs, but recent findings have changed that notion. Two distinct effects of somatostatin analogs have been proposed: direct actions, mediated by the somatostatin receptors, and indirect actions, independent of the receptors.⁹ Based on these findings, we decided to treat our patient with a combination of octreotide and corticosteroid, even though octreotide scan showed only a low uptake. Two months after treatment initiation, marked regression of pleural masses was revealed by a CT control and the patient lived without progression for almost nine months. Considering the results of octreotide scan, the marked response could be attributed to indirect anti-tumor activity as mentioned above. Although the detailed mechanisms of indirect anti-tumor activity of octreotide in thymomas are not fully understood, it has been reported that somatostatin and its synthetic analogs inhibit the release of growth factors and hormones that drive tumor growth, such as insulin, prolactin, insulin-like growth factor-1 (IGF-1), epidermal growth factor (EGF), transforming growth factor alpha (TGF alpha), gastrin, cholecystokinin and growth hormone.¹⁰ Moreover, somatostatin analogs can also indirectly control tumor growth by inhibiting angiogenesis.^{11–13} The treatment was accompanied with steroid diabetes, which is commonly seen in patients treated with corticosteroids. When the dose of methylprednisolone was reduced, the treatment was tolerated well. No adverse effects of octreotide treatment were seen.

In conclusion, we describe an interesting case of marked clinical and radiological response of metastatic malignant thymoma to the treatment with octreotide in a heavily pre-treated patient, even though octreotide scan revealed a low uptake.

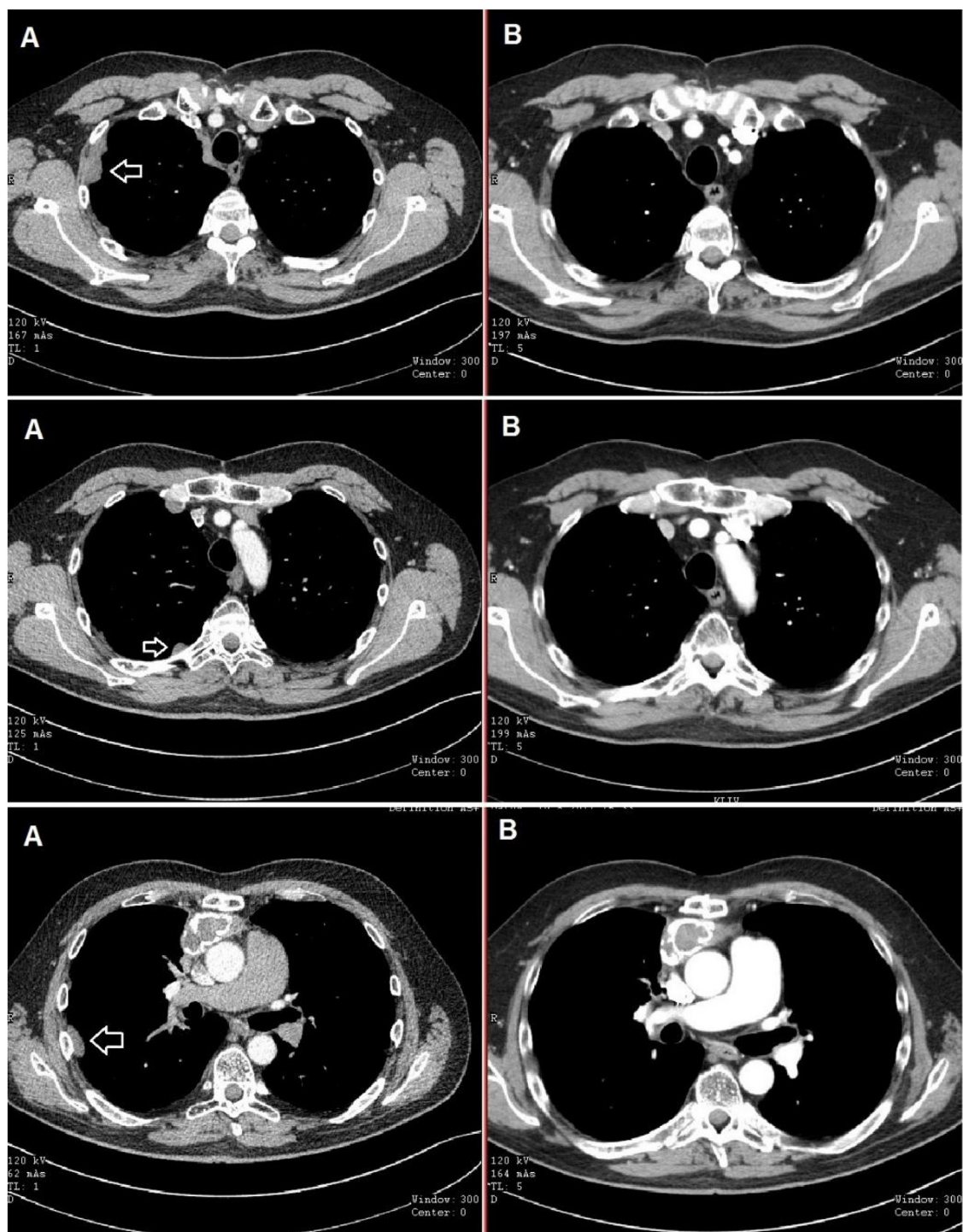


Fig. 2. CT scans showing regression of multiple pleural masses (A: before octreotide treatment, B: after two months).

Conflict of interest

JF has received honorarium from Astra Zeneca, Roche and Novartis for consultations and lectures unrelated to this project. OF, MP, MS, OS, DS, RK and OT declare that they have no actual or potential conflict of interest including any financial, personal or other relationships with other people or organizations that could inappropriately influence this work.

Financial disclosure

The authors would like to thank the patient voluntarily taking part in this case-report. The work was supported by the National Sustainability Program I (NPU I) Nr. LO1503 provided by the Ministry of Education Youth and Sports of the Czech Republic and by the Charles University Research Fund (Progres Q39), by the European Regional Development Fund-Project, Appli-

cation of Modern Technologies in Medicine and Industry” (No. CZ.02.1.01/0.0/0.0/17.048/0007280) and by the grant of Ministry of Health of the Czech Republic – AZV NV17-30748A, and by the European Union’s Horizon 2020 research and innovation programme under grant agreement N°856620.

References

1. Detterbeck FC. Evaluation and treatment of stage I and II thymoma. *J Thorac Oncol.* 2010;5:318–322, <http://dx.doi.org/10.1097/JTO.0b013e3181f20dab>.
2. Masaoka A, Monden Y, Nakahara K, Tanioka T. Follow-up study of thymomas with special reference to their clinical stages. *Cancer.* 1981;48:2485–2489, [http://dx.doi.org/10.1002/1097-0142\(19811201\)48:11<2485::AID-CNCR2820481123>3.0.CO;2-R](http://dx.doi.org/10.1002/1097-0142(19811201)48:11<2485::AID-CNCR2820481123>3.0.CO;2-R).
3. Girard N. Chemotherapy and targeted agents for thymic malignancies. *Expert Rev Anticancer Ther.* 2012;12:685–695, <http://dx.doi.org/10.1586/era.12.29>.
4. Yokoi K, Matsuguma H, Nakahara R, et al. Multidisciplinary treatment for advanced invasive thymoma with cisplatin, doxorubicin, and methylprednisolone. *J Thorac Oncol.* 2007;2:73–78, <http://dx.doi.org/10.1097/JTO.0b013e31802bafcb>.
5. Ferone D, van Hagen MP, Kwekkeboom DJ, et al. Somatostatin receptor subtypes in human thymoma and inhibition of cell proliferation by octreotide in vitro. *J Clin Endocrinol Metab.* 2000;85:1719–1726, <http://dx.doi.org/10.1210/jcem.85.4.6547>.
6. Palmieri G, Montella L, Martignetti A, et al. Somatostatin analogs and prednisone in advanced refractory thymic tumors. *Cancer.* 2002;94:1414–1420, <http://dx.doi.org/10.1002/cncr.10374>.
7. Palmieri G, Montella L, Lastoria S. Thymoma and somatostatin analogs. *Biology, diagnostic and clinical practice. Minerva Endocrinol.* 2001;26:193–195.
8. Pettit L, El-Modir A. The role of somatostatin analogues in the treatment of advanced malignant thymomas: Case report and review of the literature. *Br J Radiol.* 2011;84:7–10, <http://dx.doi.org/10.1259/bjr/16436465>.
9. Susini C, Buscail L. Rationale for the use of somatostatin analogs as antitumor agents. *Ann Oncol.* 2006;17:1733–1742, <http://dx.doi.org/10.1093/annonc/mdl1105>.
10. Murray RD, Kim K, Ren SG, Chelly M, Umehara Y, Melmed S. Central and peripheral actions of somatostatin on the growth hormone-IGF-I axis. *J Clin Invest.* 2004;114:349–356, <http://dx.doi.org/10.1172/JCI19933>.
11. Danesi R, Agen C, Benelli U, et al. Inhibition of experimental angiogenesis by the somatostatin analogue octreotide acetate (SMS 201–995). *Clin Cancer Res.* 1997;3:265–272.
12. Lawnicka H, Stepień H, Wyczolkowska J, Kolago B, Kunert-Radek J, Komorowski J. Effect of somatostatin and octreotide on proliferation and vascular endothelial growth factor secretion from murine endothelial cell line (HECa10) culture. *Biochem Biophys Res Commun.* 2000;268:567–571, <http://dx.doi.org/10.1006/bbrc.2000.2119>.
13. Jia WD, Xu GL, Sun HC, Wang L, Xu RN, Xue Q. Effect of octreotide on angiogenesis induced by hepatocellular carcinoma in vivo. *HBPD INT.* 2003;2:404–409.