REPORTS OF PRACTICAL ONCOLOGY AND RADIOTHERAPY 24 (2019) 672–680

Available online at www.sciencedirect.com

ScienceDirect

journal homepage: http://www.elsevier.com/locate/rpor

Case report

Increased radiation toxicity with germline ATM variant of uncertain clinical significance

Brandon T. Mullins[a,*], *Gaorav Gupta*[a,b]

[a] *Department of Radiation Oncology, University of North Carolina at Chapel Hill, 101 Manning Drive, CB #7512, Chapel Hill, NC, USA*

[b] *Lineberger Comprehensive Cancer Center, University of North Carolina at Chapel Hill, Chapel Hill, NC, USA*

ARTICLE INFO

Article history:
Received 24 May 2019
Received in revised form
15 July 2019
Accepted 21 September 2019
Available online 6 November 2019

Keywords:
ATM
Ataxia telangiectasia
Breast cancer
Radiation therapy
Toxicity
VUS

ABSTRACT

Background: While patients with ataxia telangiectasia are known to have increased radiation sensitivity, patients with germline heterozygous ataxia telangiectasia mutated (*ATM*) mutations can have widely varying functional and clinical effects, which can make management decisions difficult. With an increased prevalence of gene panel-based testing for breast cancer patients, radiation oncologists are increasingly confronted with patients who carry germline *ATM* variants of uncertain clinical significance. This study describes the clinical courses and outcomes of 5 breast cancer patients with varying germline heterozygous *ATM* mutations undergoing radiation therapy at our institution in order to provide additional knowledge of the varying clinical effects to aid future decision making.

Case Series: We identified 5 patients with breast cancer and varying germline heterozygous *ATM* mutations treated at the University of North Carolina Hospitals between 2015 and 2017. The median age at breast cancer diagnosis for the patient series was 46. Clinical effects of radiation treatment varied amongst the 5 patients. The one patient with a pathogenic *ATM* mutation had no increased radiation related toxicity. Of the 4 patients with *ATM* variants of uncertain significance, one patient had increased radiation sensitivity with Grade 3 dermatitis. All patients have remained recurrence free with a median duration of 18 months.

Conclusion: Our data illustrates that patients with germline heterozygous ATM mutations can have widely varying clinical effects with radiation therapy. Given the possibility of unpredictable deleterious effects, our study highlights the importance of caution and careful consideration when devising the multi-modality management strategy in these patients.

Published by Elsevier B.V. on behalf of Greater Poland Cancer Centre.

Abbreviations: ATM, Ataxia Telangiectasia Mutated; VUS, Variant of Uncertain Significance; IDC, Invasive Ductal Carcinoma; DCIS, Ductal Carcinoma In-situ; IMN, Internal Mammary Lymph Node; ALND, Axillary Lymph Node Dissection; SLNB, Sentinel Lymph Node Biopsy; ddAC, Dose Dense Adriamycin & Cyclophosphamide; TC, Taxol & Cyclophosphamide; TCH, Taxol, Cyclophosphamide, Herceptin; ER, Estrogen Receptor; PR, Progesterone Receptor; Her2, Human Epidermal Growth Factor Receptor 2.

* *Corresponding author*.
E-mail address: Brandon.mullins@unchealth.unc.edu (B.T. Mullins).

https://doi.org/10.1016/j.rpor.2019.09.008
1507-1367/Published by Elsevier B.V. on behalf of Greater Poland Cancer Centre.

1. Background

A hallmark of cancer development is defective DNA damage repair leading to genomic instability and genetic mutation.[1,2] In a given cell, multiple forms of DNA damage can occur with the potential of leading to genetic mutation if not properly repaired. In order to attempt repair, cells can activate multiple different DNA repair pathways (e.g., base excision repair, nucleotide excision repair, mismatch repair, homologous recombination, non-homologous end joining) and mutations in genes encoding proteins involved in these repair pathways have been associated with increased cancer risk.[3]

Germline homozygous mutation in the ataxia telangiectasia mutated (*ATM*) gene, which is involved in the cellular response to DNA double strand breaks, results in the ataxia telangiectasia (AT) syndrome that is characterized by cerebellar atrophy, vascular abnormalities, cancer susceptibility (including breast cancer), and marked radiation sensitivity.[4] Mutations leading to the syndrome can occur in any functional domain of the *ATM* gene and several hundred mutations have been linked thus far. Most of these mutations disrupt protein production, resulting in nonfunctional versions of the *ATM* protein that do not respond normally to DNA damage and thus are hypersensitive to radiation.

While the AT syndrome is extremely rare (1 in 40,000–100,000 people worldwide),[5] germline *ATM* heterozygosity occurs in about 1% of the population and has been associated with increased cancer susceptibility and radiation sensitivity.[6–9] Similar to the AT syndrome, germline carriers of *ATM* mutations may have decreased production of a functional *ATM* protein that results in defective DNA repair in irradiated tissues (i.e., haploinsufficiency). Experiments performed in genetically engineered mouse models support haploinsufficiency of heterozygous *ATM* mutations with regards to radiation sensitivity and cancer risk.[10] However, it is important to note that not every identified heterozygous germline *ATM* mutation leads to a functional gene effect resulting in increased radiation sensitivity, and the clinical significance of many mutations are unknown. Thus, it can be difficult to predict whether a given mutation without a presently known effect, will lead to a negative clinical effect or have no clinical significance. Many patients exist that have *ATM* gene mutations classified as variants of uncertain significance (VUS) in which the functional effect is uncertain and there is insufficient clinical evidence to support an increased cancer susceptibility risk. However, due to uncertainty of clinical impact and lack of available data, it is difficult to know whether radiation oncologists should alter management of patients with *ATM* germline variants due to the possibility of increased radiation sensitivity in patients presenting with germline *ATM* VUS mutations.

In this study, we report a clinical series of breast cancer patients with germline *ATM* heterozygosity receiving radiation therapy at our institution. One patient has a known pathogenic *ATM* mutation while the other four have VUS (one of which thought to be potentially pathogenic). Here we detail the cases, focusing on the clinical courses of the patients with known pathogenic *ATM* mutation and potentially pathogenic VUS mutation while highlighting key features of the other three VUS cases. Our study highlights the variability of clinical effect and radiation sensitivity amongst those with germline *ATM* heterozygosity with the goal of increasing the knowledge base on how to manage patients presenting with these findings.

2. Case series

This Institutional Review Board-approved series describes five patients with breast cancer and germline heterozygous *ATM* mutations treated at the University of North Carolina Hospitals between 2015 and 2017. Patient demographics including age at diagnosis, sex, race, and treatment details and outcomes were obtained through medical record abstraction (Tables 1 and 2). Genetic assessment was obtained through either the Ambry Genetics or Myriad myRisk Hereditary Cancer assessments.[11,12] Here we detail the clinical course of the two patients with less expected radiation reactions, and briefly describe the clinical course of the three remaining patients, to highlight the genetic assessment, radiation therapy decision making, and treatment-related responses.

2.0.1. *Case 1: Patient A (known pathogenic ATM mutation)*

2.0.1.1. *Initial history*

Patient A is a 46-year-old female who initially presented with clinical T1N3 right breast cancer (see Table 1 for additional patient and tumor-related details). Given the extent of disease, patient received neoadjuvant chemotherapy completing 4 cycles of dose-dense Adriamycin and Cyclophosphamide followed by 4 cycles of dose-dense Taxol. She tolerated chemotherapy fairly well with mild arthralgias and transaminitis. Five weeks after chemotherapy completion, right segmental mastectomy and right axillary lymph node dissection (ALND) were performed with post-surgical pathology revealing a partial breast tumor response to chemotherapy. Thirteen lymph nodes were examined from the ALND, which revealed fibrous scarring consistent with a complete pathologic response to treatment (1 lymph node with treatment effect). She was pathologically staged as ypT2, ypN0. She was then referred to radiation oncology for post-breast conserving surgery radiation therapy.

2.0.1.2. *Genetics*

Prior to radiation therapy consultation, genetic testing was performed, and identified a pathogenic mutation in the *ATM* gene. Patient had a heterozygous germline c.901 + 1 G > A intronic pathogenic mutation resulting from a G to A substitution one nucleotide after coding exon 6 (Table 3). This sequence alteration affects a donor splice site in intron 7 and likely results in an absent or truncated protein product. This loss-of-function variant in *ATM* was classified as pathogenic.[13] On meeting with the genetic counselor, she was advised that pathogenic mutations in *ATM* have been associated with increased risk of breast cancer; however, there was insufficient evidence at the time to recommend risk-reducing bilateral mastectomy. She was advised to remain

Table 1 – Patient and tumor characteristics of the breast cancer series.

Patient	Age at diagnosis	Sex	Race	Breast cancer laterality	Breast cancer stage	Breast cancer pathology	ATM mutation
A	46	F	Hispanic	Right	cT1N3 ypT2N0	IDC ER+, PR+, Her2− Grade 2	Pathogenic Mutation c.901 + 1 G > A Splice Site Mutation
B	48	F	Caucasian	Left	cT3N0 ypTisN0	IDC ER−, PR−, Her2- Grade 3	VUS p.R451C (c.1351 C > T) Missense Mutation
C	44	F	Caucasian	Left	cT1N0 pT1N0	Solid Papillary Carcinoma ER+, PR+, Her2− Grade 2	VUS p.Y583C (c. 1748 A > G) Missense Mutation
D	42	F	African American	Right	cT1N0 pT1N0	IDC ER+, PR+, Her2− Grade 3	VUS p.Ala112Thr (c.334 G > A) Missense Mutation
E	56*	F	Caucasian	Right	cT1N0 pT1N1	IDC ER+, PR+, Her2+ Grade 2	VUS Del of exons 47-50 Exon Deletion

Abbreviations: IDC, Invasive Ductal Carcinoma; ER, Estrogen Receptor; PR, Progesterone Receptor; Her2, Human Epidermal Growth Factor Receptor 2.
* Diagnosed with contralateral DCIS at age 41.

Table 2 – Treatment and outcomes of the breast cancer series.

Patient	Surgery	Chemotherapy	Radiation target	Radiation Dose/Fraction	Radiation toxicity (CTCAE)	Duration of local control	Overall survival
A	Segmental Mastectomy & ALND	Neoadjuvant ddAC + T	Right Breast & SCV (3-Field)	59 Gy/32 fractions	Grade 2 Skin Dermatitis	18 months	18 months
B	Mastectomy & SLNB	Neoadjuvant TC & ddAC	Left Chest Wall & SCV (3-Field)	45 Gy/25 fractions	Grade 3 Skin Dermatitis	20 months	20 months
C	Lumpectomy & SLNB	None	Left Breast (Tangents)	62 Gy/31 fractions	Grade 2 Skin Dermatitis	38 months	38 months
D	Lumpectomy & SLNB	None	Right Breast (Tangents)	59.4 Gy/33 fractions	Grade 1-2 Skin Dermatitis	9 months	9 months
E	Lumpectomy & ALND	Adjuvant TCH	Left Breast & SCV (3-Field)	50.4 Gy/28 fractions	Grade 1-2 Skin Dermatitis	10 months	10 months

Abbreviations: ALND – Axillary Lymph Node Dissection; SLNB – Sentinel Lymph Node Biopsy; ddAC – Dose Dense Adriamycin & Cyclophosphamide; TC – Taxol & Cyclophosphamide, TCH – Taxol, Cyclophosphamide, Herceptin.

in contact annually to ensure communication of additional findings related to her genetics.

2.0.1.3. *Radiation consultation and treatment*

Post-lumpectomy radiation was recommended to the right whole breast and regional nodes (IMN and supraclavicular) for breast conservation and treatment of potentially unresected internal mammary disease. Due to her pathogenic *ATM* mutation, and possibility of increased radiation sensitivity and acute toxicity, it was decided to reduce the dose per fraction from the institution's typical post-lumpectomy treatment dose (50 Gy to the whole breast ± at-risk nodal regions [based on nodal disease status] with a 10 Gy boost to the lumpectomy cavity, all in 2 Gy/fractions). For Patient A, the right whole breast and regional nodes were treated to 45 Gy in 1.8 Gy/fractions with a subsequent boost to the lumpectomy cavity and previously PET-avid right IMN of 14 Gy in 2 Gy/fractions to a total of 59 Gy. The potential risk of added radiation toxicity (given her ATM mutation) was thoroughly discussed, patient was consented to treatment, and CT simulation for radiation planning commenced.

During the first 2 weeks of treatment, her radiation course was unremarkable without skin erythema or hyperpigmentation. She noted continued right arm edema and soreness, which had been present since her surgery and worked with physical therapy for additional benefit. There was no worsening of her edema during treatment. She continued to apply emollients for moisturizing. By fraction 17 (30.6 Gy), mild erythema over the upper right breast was noted. There was no desquamation present. By fraction 22 (39.6 Gy), mild erythema was noted over the upper right breast and right axilla. No desquamation again was noted. After completing 45 Gy to the right breast and regional nodes, a 14 Gy boost to the right lumpectomy cavity and IMN commenced. By fraction

Table 3 – ATM sequence variants of the breast cancer series.

Patient	ATM location	Variant designation	Allele frequency	Amino acid substitution	Expected functional effect
A	Intron 7	c.901 + 1 G > A	0.00003%±	None	Pathogenic Mutation – Splice Site Mutation Predicted to be Pathogenic*
B	Exon 9	c.1351 C > T	0.008%*	Arginine replaced by Cysteine	VUS – Missense Mutation Uncertain – Though Predicted to be "Probably Damaging"[1] and "Tolerated"[2]
C	Exon 10	c. 1748 A > G	0.002%*	Tyrosine replaced by Cysteine	VUS – Missense Mutation Uncertain – Though Predicted to be "Benign"[1] and "Tolerated"[2]
D	Intron - Unspecified	c.334 G > A	0.0002±	Alanine replaced by Threonine	VUS – Missense Mutation Uncertain – Though Predicted to Likely be Benign¥
E	Exons 47-50	Del exons 47-50	Unspecified	None	VUS – Deletion Unknown Functional Effect¥

* From Ambry Genetics.[13]
¥ From Myriad myRisk.[12]
± From Clinvar.[25]
1 Predicted by PolyPhen *in silico* analysis.[15]
2 Predicted by SIFT *in silico* analysis.[16]

26 (46.8 Gy), moderate erythema had developed in both the right upper breast and right axilla with a small amount of dry desquamation over the right clavicle. By fraction 32 (57.6 Gy), more dry desquamation was present in the axilla but dry desquamation over the clavicle had improved. Throughout her course, she continued to have the moderate right arm/axillary post-surgical discomfort and worked with physical therapy. Overall, she tolerated her treatment well with expected radiation-related side effects. Her germline heterozygous pathogenic *ATM* mutation did not seem to clinically impact her radiation treatment.

2.0.1.4. *Post-Treatment*

After completing treatment, her lymphedema improved with physical therapy and her radiation related skin changes resolved. At 18 months post-treatment, she had no evidence of recurrence, good breast cosmesis, and no residual radiation effect.

2.0.2. *Case 2: Patient B (ATM VUS with uncertain but potentially pathogenic mutation)*

2.0.2.1. *Initial history*

Patient B is a 49-year-old female who initially presented with clinical T3N0 left breast cancer (see Table 1 for additional patient and tumor-related details). Due to the large tumor size (7.6 cm) and triple negative pathology, the patient received neoadjuvant chemotherapy with 4 cycles of weekly Taxol with every three week Carboplatin followed by 4 cycles of dose-dense Adriamycin and Cyclophosphamide, as per clinical trial CALGB 40603.[14] She had a great clinical response to Taxol/Carboplatin with tumor no longer palpable by cycle 4. She also tolerated chemotherapy reasonably well, only suffering grade 2 nausea and grade 2–3 fatigue. 5 weeks after completion of chemotherapy, left mastectomy with sentinel lymph node biopsy (SLNB) was performed with pathology revealing 0.7 cm of DCIS with no residual invasive cancer and 5/5 lymph nodes negative for cancer. Thus, her pathology was consistent with a pathologic complete response (pCR), ypTis ypN0. After a balanced discussion regarding the potential benefits of adjuvant radiotherapy for clinical T3 triple-negative breast cancer, the patient elected to proceed with post-mastectomy radiation therapy.

2.0.2.2. *Genetics*

Prior to radiation therapy consultation, genetic testing was performed and identified an *ATM* VUS. The patient had a heterozygous germline *ATM* missense variant, c.1351 C > T substitution in coding exon 9 of *ATM*, resulting in an amino acid substitution at position 451 (p.R451C). The mutation results in an arginine (i.e., positively charged residue) being replaced by a cysteine at codon 451, which is an amino acid with highly dissimilar properties. This amino acid position is also highly conserved in vertebrate species (Fig. 1). Interestingly, this alteration was predicted to be "probably damaging" by the PolyPhen *in silico* analysis[15] but "tolerated" by the SIFT *in silico* analysis,[16] but there was limited supporting evidence and it was deemed that the clinical significance of the alteration was unclear.[13] Thus, the patient's germline *ATM* mutation was classified as a variant of uncertain significance (VUS), and it was further unknown whether it may result in increased sensitivity to the effects of radiation therapy.

2.0.2.3. *Radiation consultation and treatment*

When Patient B was seen for consultation, the potential clinical significance of this *ATM* variant was very highly considered in treatment decision-making. Due to the patient's young age and the possibility of unconfirmed pathological lymph node positivity prior to neoadjuvant chemotherapy, it was felt that the benefits of adjuvant radiation therapy outweighed the risk of increased radiation sensitivity. Thus, a decision was made to radiate her left chest wall and regional nodes (axillary, supr-

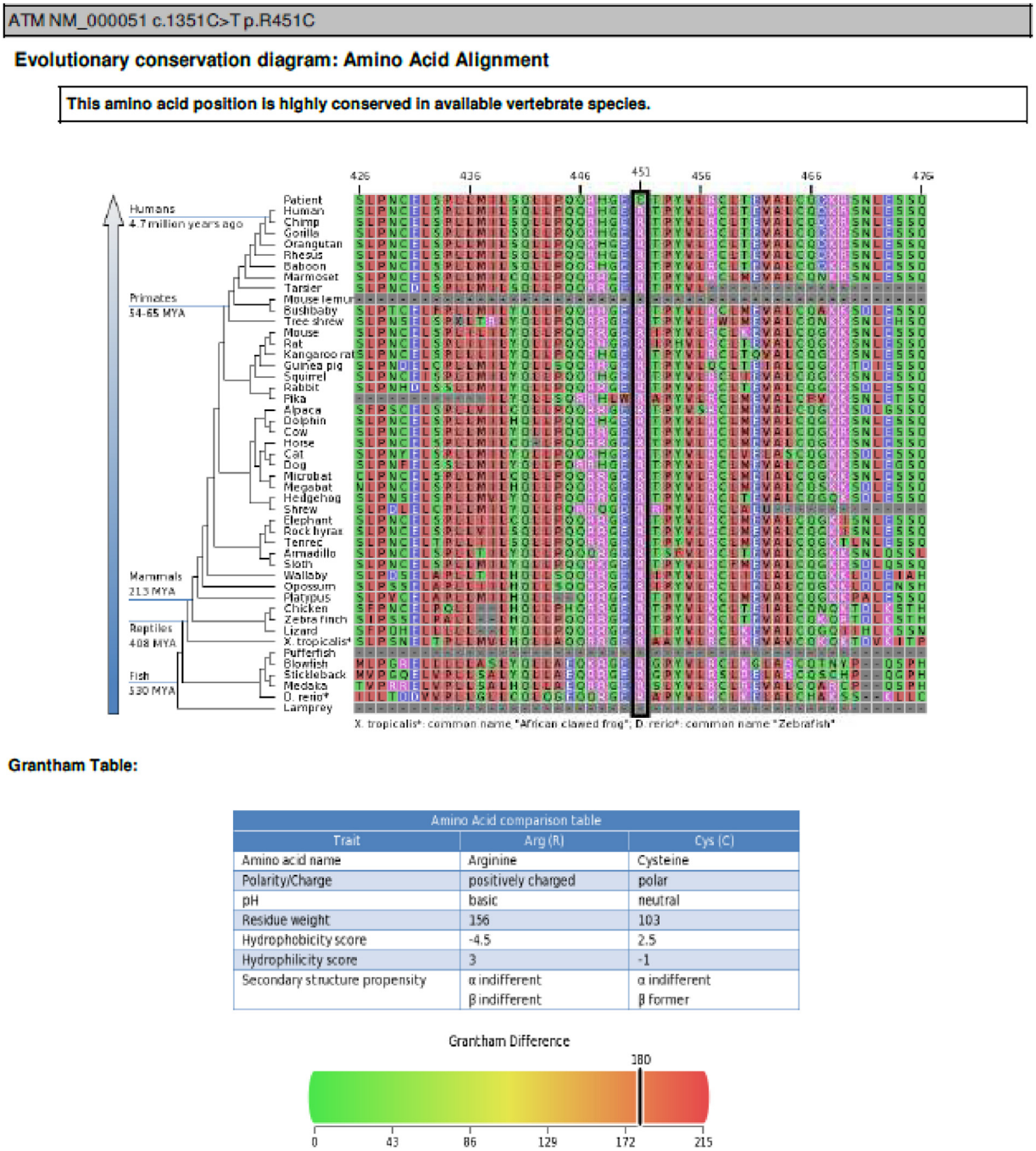

Grantham Table:

Amino Acid comparison table		
Trait	Arg (R)	Cys (C)
Amino acid name	Arginine	Cysteine
Polarity/Charge	positively charged	polar
pH	basic	neutral
Residue weight	156	103
Hydrophobicity score	-4.5	2.5
Hydrophilicity score	3	-1
Secondary structure propensity	α indifferent β indifferent	α indifferent β former

Fig. 1 – Figure Showing the Highly Conservative Nature of the Amino Acid Position for Patient B.

aclavicular, and the first three intercostal spaces of internal mammary nodes). Due to the possibility of the variant causing deleterious radiation sensitivity, it was decided to reduce the dose from the institution's typical post-mastectomy treatment dose. Typically in post-mastectomy patients, the chest wall and regional nodal volumes are treated to a dose of 50 Gy (2 Gy fractions) with a chest wall scar boost of 10 Gy (2 Gy fractions). However, due to the VUS, it was decided to treat the chest wall and regional nodes to 45 Gy (1.8 Gy fractions) with a possibility of a chest wall scar boost of 5.4 Gy (1.8 Gy fractions) depending on her normal tissue toxicity. The potential added toxicity risks given her *ATM* VUS were thoroughly discussed, she was consented to treatment, and she proceeded with CT simulation for radiation planning.

During the first 2 weeks of treatment, her radiation course was unremarkable with minimal radiation-related skin changes. During this time, she only experienced mild erythema and mild hyperpigmentation. She continued to apply daily emollients for moisturizing. During weekly status check after fraction 15, patient experienced slightly more toxicity with her skin experiencing mild erythema around the treatment field match-line without any desquamation. She also

had mild breast itching to which she applied hydrocortisone as needed. During weekly status check after fraction 20, patient's skin had developed moderate erythema and folliculitis with minimal dry desquamation. There was no moist desquamation at this time. However, after fraction 22, she reported that her skin reaction had greatly increased. When she was seen for her weekly treatment status check after fraction 24, she had developed severe erythema as well as moderate patches of moist desquamation in the treatment field, most prominent in the left axilla (Grade 3 skin dermatitis, CTCAE). She was provided silvadene cream and a decision was made not to pursue an additional chest wall scar boost due to the severe radiation-related skin reaction (possibly potentiated by her *ATM* VUS).

2.0.2.4. *Post-Treatment*

At 1-month post-treatment follow-up, patient had experienced great recovery from toxicity. The previous moist desquamation had completely healed, there was no appreciable dissymmetry, and her skin appeared healthy with only mild hyperpigmentation. Patient had a great recovery overall.

Patient had left breast reconstruction 7 months post-treatment and her surgeon was impressed by the extent of elasticity and the good cosmetic appearance of the breast despite her radiation treatment. At 20-months post-treatment follow-up, patient remained recurrence free with healthy appearing skin and good cosmetic appearance with only subtle dissymmetry. No evidence of long-term deleterious radiation-related effect.

2.0.3. *Cases 3-5: Patients C-E (ATM VUS with uncertain but likely tolerable mutation)*

2.0.3.1. *Initial history*

Patients C–E all had earlier stage, hormone receptor positive, breast cancer (Table 1). Patient E was also Her2 mutation positive. They all underwent breast-conserving surgery with Patient E additionally undergoing adjuvant systemic therapy with Taxol, Cyclophosphamide, and Herceptin (TCH), given her Her2+ mutation status, which she tolerated well without unexpected toxicity.

2.0.3.2. *Genetics*

On genetic analysis, they were all found to have *ATM* VUS missense mutations that were stated to have uncertain clinical effect. Patient C had a heterozygous germline p.Y583C missense variant, resulting from nucleotide substitution in coding exon 10 (c.1748 A > G). The mutation results in a tyrosine being replaced by cysteine at codon 583. Similar to Patient B, it was noted that these amino acids have highly dissimilar properties; however, Patient C's alteration was poorly conserved in available vertebrate species (Fig. 2) and was predicted to be "benign" and "tolerated" by the Polyphen and SIFT *in silico* analyses respectively.[15,16] Although, given the limited supporting evidence, again it was deemed that the clinical significance of the alteration remained unclear.[13] Patient D had a heterozygous germline variant of p.Ala112Thr (also known as c.334 G > A) which is a missense variant resulting from a G to A substitution at nucleotide position 334. The mutation results in an alanine being replaced by a threonine at codon 112. Patient D's mutation was thought to likely be benign, but again there was limiting supporting evidence and thus it was deemed that the clinical significance of the variant was unclear.[12] Patient E had a heterozygous germline variant labeled as del exons 47–50 which resulted in the deletion of exons 47–50 of the *ATM* gene. The deletion is in-frame and occurs in a region of unknown function and therefore is considered a variant of uncertain significance. Again, there was insufficient evidence to definitively determine whether or not this variant is associated with increased cancer risk.[12]

2.0.3.3. *Radiation consultation and treatment*

Given the concern for potential radiation sensitivity given the VUS mutations, all three patients received radiation courses that differed from the institution's traditional fractionation scheme (whole breast radiation [with/without additional regional nodal coverage given nodal disease status] to 50 Gy with a 10 Gy tumor bed boost all in 2 Gy fractions). Patient C received whole breast radiation to 46 Gy (2 Gy fractions) with a 16 Gy (2 Gy fractions) boost to the tumor bed. Patient D received whole breast radiation to 46.8 Gy (1.8 Gy fractions) with a 12.6 Gy (1.8 Gy fractions) boost to the tumor bed. Patient E received 50.4 Gy (1.8 Gy fractions) to the whole breast and regional nodal levels (given pathologic nodal positivity) without a tumor bed boost. These alterations in radiation course were all done in consideration of potential potentiated radiation toxicity. Fortunately, all three patients did very well through their radiation course with only expected grade 1–2 radiation-related skin dermatitis (CTCAE) improved with emollient use.

2.0.3.4. *Post-Treatment*

All three patients recovered well after treatment within the expected time period. They have had no significant late radiation-related breast effects and have good breast cosmesis. Additionally, they have had no evidence of recurrence during follow-up. Patient C, D, and E are 38, 9, and 10 months post-treatment, respectively, without evidence of recurrence or new disease (Table 3).

3. Discussion and conclusions

As demonstrated by our case series, there are varying clinical effects to heterozygous germline *ATM* mutations. As illustrated by Patient A, "pathogenic mutations", that are known to cause pathogenic effects to the *ATM* gene, will not always lead to adverse clinical effects when patients undergo radiation treatment. In the literature, there are 2 known reports of other patients harboring similar mutations who had a deleterious clinical response (though one patient did have a second pathogenic *ATM* variant).[17,18] This highlights the variability of clinical response given that Patient A, with a similar mutation, did not have potentiated radiation-related skin toxicity when undergoing a full course of treatment.

Additionally, while *ATM* VUS may have historically been viewed as clinically insignificant to many, our series illustrates the contrary. *ATM* VUS may lead to adverse clinical effects and radiation sensitivity in some patients while having no adverse effects in others, as evidenced by Patient B's relatively sudden

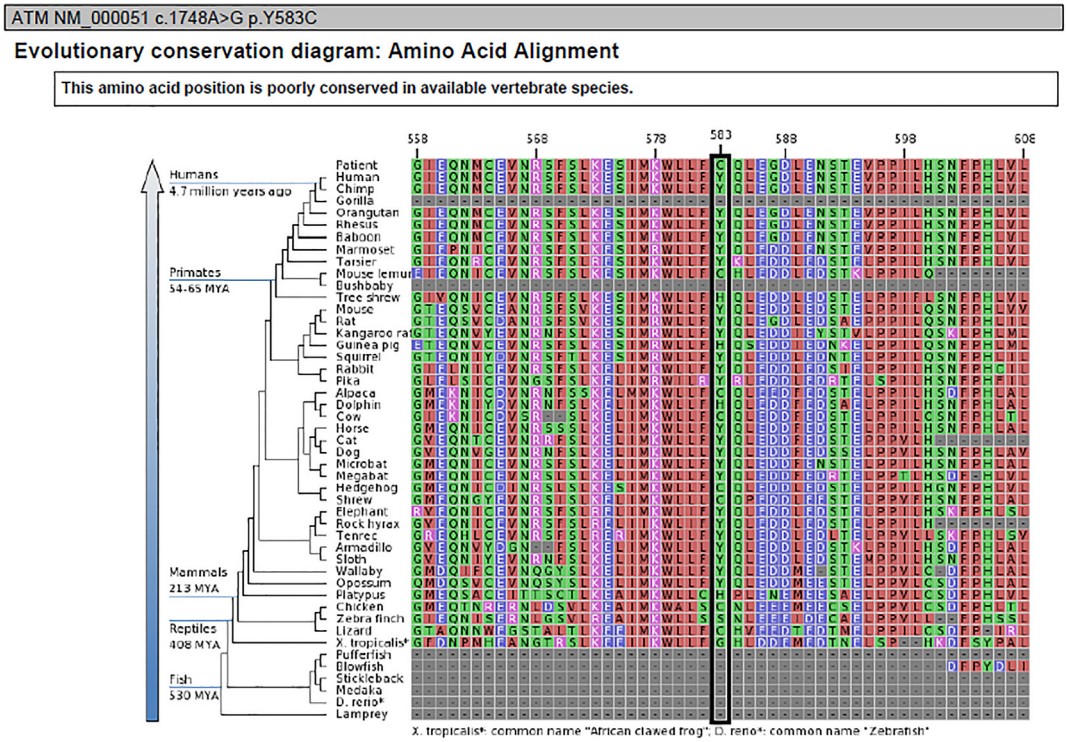

Grantham Table:

Amino Acid comparison table		
Trait	Tyr (Y)	Cys (C)
Amino acid name	Tyrosine	Cysteine
Polarity/Charge	polar	polar
pH	neutral	neutral
Residue weight	163	103
Hydrophobicity score	-1.3	2.5
Hydrophilicity score	-2.3	-1
Secondary structure propensity	α breaker strong β former	α indifferent β former

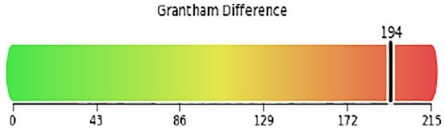

Fig. 2 – Figure Showing the Poorly Conservative Nature of the Amino Acid Position for Patient C.

onset of grade 3 skin toxicity compared to relatively mild grade 1–2 skin toxicity in Patients C–E, even at a lesser total radiation dose (45 Gy vs. 50–62 Gy). Three of the four patients with VUS had missense mutations and yet their degree of radiation sensitivity varied. A potential reason for Patient B's increased sensitivity to radiation lies within the location of her germline missense variant. There is evidence that missense mutations in highly-conserved residues can act as dominant-negative mutations and be associated with even greater functional and clinical effect than protein truncating mutations.[19–21] Thus, the highly conservative nature of her mutation could have contributed to the functional detriment and increased radiation sensitivity, despite presence of one copy of non-mutated *ATM*. Patient C's mutation was noted to be poorly conserved in species evolution while the conservative nature of Patient D & E's mutations were not known. Overall, as evidenced by these patients, it can be difficult to predict which *ATM* variants will lead to potentiated radiation-related reactions. These results highlight the importance of maintaining caution when treating patients with any form of *ATM* mutation, whether known to be pathogenic or of uncertain clinical significance. This is of additional importance when appreciating that many VUS' are classified as having unknown clinical effect merely based on a lack of currently available evidence on whether they cause an effect.[12,13]

Interestingly, in the literature, there is also report that heterozygous germline *ATM* mutations can lead to potentiated reactions and toxicity in conjunction with chemotherapy. Hasmats et al reported an association with increased carboplatin and paclitaxel toxicity with *ATM* mutation.[22] In our series, Patient A, B, and E all received chemotherapy. Notably, none of the patients in our series, including Patient A with the pathogenic mutation, had an exacerbated response to chemotherapy. However, given that there has been prior report

of additional toxicity, consideration to this should be maintained when seeing patients with *ATM* mutations, pathogenic or VUS, given these variable clinical responses.

Additional notable findings in our series were the relatively younger age at diagnosis and treatment outcomes. The median age of breast cancer diagnosis in our patient series was 46, which is 15 years younger than the average age of breast cancer diagnosis in the general population. This potentially relates to the increased cancer risk that can be seen in patients with germline heterozygous *ATM* mutations, particularly the increased relative risk of breast cancer in those younger than age 50.[23] Additionally, all five of our patients have remained recurrence free post-treatment at a median of 18 months. While Patients C & D both had early-stage, localized, hormone positive disease and good expected outcomes, Patients A, B, and E all had higher risk for recurrence based on their tumor characteristics. Patient A had clinical node-positivity, Patient B had a large tumor and triple negative receptor biology, and Patient E had pathologic node-positivity and triple positive receptor biology. Thus, no recurrences in our series thus far is not trivial. There are reports in the literature of improved cancer responses in *ATM* mutated patients. Ma et al reported a series of 8 patients with alternations in *ATM* demonstrating dramatic clinical responses to palliative radiotherapy.[24] Whether the *ATM* mutation had any relevance in breast cancer treatment response of our patients is unknown; however, it is another interesting finding in our series. With additional long-term follow-up, any unexpected potential recurrence and/or survival outcomes can be further evaluated.

In conclusion, our case series highlights that patients with heterozygous germline *ATM* mutations can have widely varying clinical responses to radiation therapy. While some patients with known pathogenic mutations will not have deleterious effects to radiation therapy, some patients with variants of uncertain significance that are seemingly benign may have serious radiation-related effects. Thus, when assessing patients with heterozygous *ATM* mutations in consultation, it is imperative to be mindful of this spectrum of effects and utilize caution when making management decisions to optimize patient care. Our findings suggest that heterozygous *ATM* mutations should not be considered a contraindication to adjuvant breast radiotherapy. However, a cautious approach with lower dosage per fraction is prudent to allow for close monitoring and potential adaptation of the total delivered dose according to the development of acute clinical toxicity.

Declarations

Ethics approval and consent to participate: All patients consented to participate in the study and to have their case published

Consent for publication: All patients consented to participate in the study and to have their case published

Conflicts of interest

None declared.

Financial disclosure

None declared.

Acknowledgements

We thank the patients who agreed to be included in this study. We thank the University of North Carolina Hospitals and Lineberger Cancer Center for providing support.

REFERENCES

1. Macheret M, Halazonetis TD. DNA replication stress as a hallmark of cancer. *Annu Rev Pathol* 2015;**10**:425–48.
2. Hanahan D, Weinberg RA. Hallmarks of cancer: the next generation. *Cell* 2011;**144**:646–74.
3. Ali R, Rakha EA, Madhusudan S, et al. DNA damage repair in breast cancer and its therapeutic implications. *Pathology* 2017;**49**(2):156–65.
4. Reiman A, Srinivasan V, Barone G, et al. Lymphoid tumours and breast cancer in ataxia telangiectasia; substantial protective effect of residual ATM kinase activity against childhood tumours. *Br J Cancer* 2011;**105**:586–91.
5. National Cancer Institute. https://www.cancer.gov/about-cancer/causes-prevention/genetics/ataxia-fact-sheet. Accessed 8/8/2018.
6. Swift M, Morrell D, Massey RB, et al. Incidence of cancer in 161 families affected by ataxia-telangiectasia. *N Engl J Med* 1991;**325**:1831–6.
7. Byrd PJ, Srinivasan V, Last JI, Smith A, Biggs P, Carney EF, et al. Severe reaction to radiotherapy for breast cancer as the presenting feature of ataxia telangiectasia. *Br J Cancer* 2012;**106**:262–8.
8. Ho AY, Fan G, Atencio DP, et al. Possession of ATM sequence variants as predictor for late normal tissue responses in breast cancer patients treated with radiotherapy. *Int J Radiat Oncol Biol Phys* 2007;**69**(3):677–84.
9. Cesaretti JA, Stock RG, Lehrer S, et al. ATM sequence variants are predictive of adverse radiotherapy response among patients treated for prostate cancer. *Int J Radiat Oncol Biol Phys* 2005;**61**(1):196–202.
10. Worgul BV, Smilenov L, Brenner DJ, et al. ATM heterozygous mice are more sensitive to radiation-induced cataracts than are their wild-type counterparts. *Proc Natl Acad Sci USA* 2002;**99**:9836–9.
11. Ambry Genetics. https://www.ambrygen.com/clinician/genetic-testing/4/oncology/breastnext Accessed 8/8/2018.
12. Myriad myRisk Hereditary Breast Cancer. https://myriad.com/healthcare-professionals/disease-education/breast-cancer/ Accessed 8/8/2018.
13. Ambry Genetics Variant Classification Scheme. https://www.ambrygen.com/clinician/our-scientific-excellence/variant-classification. Accessed 8/8/2018.
14. Sikov WM, Berry DA, Perou CM, et al. Impact of the addition of carboplatin and/or bevacizumab to neoadjuvant once-per-week paclitaxel followed by dose-dense doxorubicin and cyclophosphamide on pathologic complete response rates in stage II to III triple-negative breast cancer: CALGB 40603 (Alliance). *J Clin Oncol* 2015;**33**(1):13–21.
15. PolyPhen [Internet]: Adzhubei IA, et al. Nat Methods. 2010;7(4):248-249. Genetics.bwh.harvard.edu/pph2.
16. SIFT [Internet]: Ng PC & Henikoff S. Hum Genet. 2006;7:61-80. http://sift.jcvi.org.

17. Du L, Lai CH, Concannon P. Rapid screen for truncating ATM mutations by PTT-ELISA. *Mutat Res* 2008;**640**(1-2): 139–44.
18. Mitui M, Campbell C, Coutinho G, et al. Independent Mutational Events are Rare in the ATM Gene: Haplotype Prescreening Enhances Mutation Detection Rate. *Human Mutation* 2003;**22**:43–50.
19. Gatti RA, Tward A, Concannon P, et al. Cancer risk in ATM heterozygotes: a model of phenotypic and mechanistic differences between missense and truncating mutations. *Mol Genet Metab* 1999;**68**(4):419–23.
20. Tavtigian SV, Oefner PJ, Babikyan D, et al. Rare, evolutionarily unlikely missense substitutions in ATM confer increased risk of breast cancer. *Am J Hum Genet* 2009;**85**(4):427–46, http://dx.doi.org/10.1016/j.ajhg.2009.08.018.
21. Goldgar DE, Healey S, Dowty JG. Rare variants in the ATM gene and risk of breast cancer. *Breast Cancer Res* 2011;**13**(4):R73, http://dx.doi.org/10.1186/bcr2919.
22. Hasmats J, Kupershmidt I, Rodriguez-Antona C, et al. Identification of candidate SNPs for drug induced toxicity from differentially expressed genes in associated tissues. *Gene* 2012;**506**(1):62–8.
23. Thompson D, Duedal S, Kirner J, McGuffog L, Last J, Reiman A, et al. Cancer risks and mortality in heterozygous ATM mutation carriers. *J Natl Cancer Inst* 2005;**97**:813–22.
24. Ma J, Setton J, Morris L, et al. Genomic analysis of exceptional responders to radiotherapy reveals somatic mutations in ATM. *Oncotarget* 2017;**8**(6):10312–23.
25. ClinVar. https://www.ncbi.nlm.nih.gov/clinvar/. Accessed 8/8/2018.