

Available online at www.sciencedirect.com

ScienceDirect

journal homepage: <http://www.elsevier.com/locate/rpor>

Review

Review of strategies for MRI based reconstruction of endocavitary and interstitial applicators in brachytherapy of cervical cancer



José Richart^{a,*}, Vicente Carmona-Meseguer^b, Teresa García-Martínez^c, Antonio Herreros^d, Antonio Otal^e, Santiago Pellejero^f, Ana Tornero-López^g, José Pérez-Calatayud^b

^a Hospital Clínica Benidorm, Medical Physics Department, Alicante, Spain

^b Hospital La Fe-IRIMED, Department of Radiation Oncology, Medical Physics Section, Valencia, Spain

^c Hospital Universitario La Ribera, Medical Physics Department, Alzira, Spain

^d Hospital Clínic, Department of Radiation Oncology, Medical Physics Section, Barcelona, Spain

^e Hospital Arnau de Vilanova, Medical Physics Department, Lleida, Spain

^f Complejo Hospitalario de Navarra, Medical Physics Department, Pamplona, Spain

^g Hospital Dr. Negrín, Medical Physics Department, Las Palmas de Gran Canaria, Spain

ARTICLE INFO

Article history:

Received 28 November 2017

Received in revised form

4 April 2018

Accepted 23 June 2018

Available online 23 July 2018

Keywords:

Brachytherapy

Cervix cancer

Catheters reconstruction

Magnetic resonance

ABSTRACT

Brachytherapy plays an essential role in the curative intent management of locally advanced cervical cancer. The introduction of the magnetic resonance (MR) as a preferred image modality and the development of new type of applicators with interstitial components have further improved its benefits.

The aim of this work is to review the current status of one important aspect in the cervix cancer brachytherapy procedure, namely catheter reconstruction.

MR compatible intracavitary and interstitial applicators are described. Considerations about the use of MR imaging (MRI) regarding appropriate strategies for applicator reconstruction, technical requirements, MR sequences, patient preparation and applicator commissioning are included.

It is recommendable to perform the reconstruction process in the same image study employed by the physician for contouring, that is, T2 weighted (T2W) sequences. Nevertheless, a clear identification of the source path inside the catheters and the applicators is a challenge when using exclusively T2W sequences. For the intracavitary component of the implant, sometimes the catheters may be filled with some substance that produces a high intensity signal on MRI. However, this strategy is not feasible for plastic tubes or titanium needles, which, moreover, induce magnetic susceptibility artifacts. In these situations, the use of applicator libraries available in the treatment planning system (TPS) is useful, since they not only include accurate geometrical models of the intracavitary applicators, but also recent developments have made possible the implementation of the interstitial component.

* Corresponding author at: Medical Physics Department, Hospital Clínica Benidorm, Avda./Alfonso Puchades, 8, 03501, Benidorm, Alicante, Spain.

E-mail address: joserichart@clinicabenidorm.com (J. Richart).

<https://doi.org/10.1016/j.rpor.2018.06.005>

1507-1367/© 2018 Greater Poland Cancer Centre. Published by Elsevier Sp. z o.o. All rights reserved.

Another strategy to improve the reconstruction process is based on the incorporation of MR markers, such as small pellets, to be used as anchor points.

Many institutions employ computed tomography (CT) as a supporting image modality. The registration of CT and MR image sets should be carefully performed, and its uncertainty previously assessed. Besides, an important research work is being carried out regarding the use of ultrasound and electromagnetic tracking technologies.

© 2018 Greater Poland Cancer Centre. Published by Elsevier Sp. z o.o. All rights reserved.

1. Background

Brachytherapy (BT) plays an essential role in the curative intent management of locally advanced cervical cancer for which the conventional approach consists of external beam radiotherapy (EBRT) with concurrent chemotherapy followed by BT. Excellent local control rates are achieved with this scheme. Many authors have reported increasing levels of tumor control while decreasing rates in normal tissue toxicity when BT is involved in the overall course of the treatment, demonstrating its efficacy.^{1–3}

Furthermore, the introduction of image based planning in BT procedures has proven to have a huge impact in the clinical outcome improvement of the patients undergoing this type of procedures.⁴ During the last decade, BT of cervical cancer has evolved from a 2D approach and point based prescription, to 3D or 4D image based treatment planning, magnetic resonance imaging (MRI) being the preferred image modality, and volume based prescription, which allows taking into account the changes due to the tumor response during the treatment. In 2016, the International Commission on Radiation Units and Measurements, in collaboration with the Groupe Européen de Curithérapie – European Society for Radiotherapy and Oncology (GEC-ESTRO), published the ICRU report n° 89,⁵ where essentials for image acquisition, tumor contouring, dose calculation and treatment planning procedures such as applicator reconstruction are described.

The advent of the image guided adaptive brachytherapy (IGABT) has further improve local control rates.^{6–12} Precise target volume contouring on MRI and adaptive volume based (instead of point based) treatment planning underlies the good outcomes.

Some studies have analyzed the use of high conformal techniques, such as IMRT or SBRT, with the objective of replacing BT procedures.^{13–15} Nevertheless, these advanced techniques of EBRT are not able to produce dose distributions with as high doses and steep dose gradients delivered to the target, while minimizing dose to the critical structures as dose distributions typically produced in BT.¹⁶ Furthermore, lower survival rates have been reported when BT is not carried out. Undoubtedly, as stated in an article of Tanderup et al.¹⁶, high quality IGABT is of crucial importance in the management of locally advanced cervical cancer.

International recommendations advocate the use of MRI as the preferred image modality due to its superior soft tissue contrast.^{17–19} Therefore, applicators must be MR compatible. Additionally, it has been evidenced that the interstitial component, added to the intracavitary one, allows for a higher conformity and organs at risk dose sparing.^{12,20,21} In this work,

we have reviewed the commercially available applicators as well as some in-house developed ones, focusing on those having interstitial components.

Ideally, the reconstruction of the applicator geometry and its matching with the patient anatomy should be done in the same image study in which the physician defines the volumes to be treated, that is T2 weighted (T2W) MRI. However, the availability of the MR may be limited and, in addition, the identification of the source trajectory inside the void signal produced by the air filled interior of the applicators is difficult. Therefore, the use of other image modalities is sometimes beneficial in the reconstruction process. In this work a literature review is performed in order to gather information about how to facilitate the reconstruction procedure, including direct reconstruction, applicator library based reconstruction and electromagnetic tracking. The use of complementary or alternative image modalities is also addressed, such as CT and ultrasonography (US).

The authors want to emphasize that the different applicators or commercially available products mentioned in this work are presented merely with an illustrative purpose and do not represent any recommendation about their use in clinical practice.

2. MR compatible applicators for locally advanced cervical cancer

Bulky infiltrative extensive disease in cervix carcinoma with lateral parametrial invasion requires an interstitial component combined with the intracavitary one in the BT treatment in order to optimize properly the dose distribution in this adverse asymmetrical topography.^{22–24}

In this context, BT companies provide a considerable variety of mixed intracavitary-interstitial MR compatible cervix applicators in three modalities: interstitial-vaginal (IS-V), interstitial-perineal (IS-P) and interstitial-vaginal-perineal (IS-V&P). The first group (IS-V) includes ovoids with tandem²¹ and ring with tandem.²⁰ In the second group, Martinez et al.²⁵ developed a commercial interstitial-perineal (IS-P) template with vaginal obturator. Varian (VMS, Palo Alto, CA, USA) developed gynecological templates (Kelowna) for interstitial implants. Some users have created their own templates^{26,27} in order to suit their clinical requirements and facilitate the distribution of needles across the perineum. A prototype applicator, with combined perineal template and vaginal cylinder, is the Nice applicator, that was developed by Hannoun-Levi et al.²⁸ In the third group, (IS-V&P) one applicator from Bebig (Eckert & Ziegler, Berlin, Germany)

combines the perineal template and vaginal cylinder, with needles in the vaginal obturator. The Venezia applicator, which appeared recently in the market, is a solution bringing together vaginal and perineal interstitial elements (IS-V&P) (<https://www.elekta.com/brachytherapy/applicators.html>). 3D printing expands the possibilities of interstitial vaginal BT allowing modification and personalization of commercial solutions according to patient anatomy.^{29,30}

In the IS-V line, Fokdal et al.²⁹ use a biocompatible, 3D printing material in a study on virtual planning of the interstitial component to generate a custom cap with perforations for twelve needles, which is subsequently placed on a tandem applicator. Similarly, Lindegaard et al.³⁰ report the clinical use of a ring template created by 3D printing and assembled to a tandem applicator from Varian (VMS, Palo Alto, CA, USA). In addition to the economic gain and being able to be customized to the vaginal vault, the interstitial component vector directions can be designed with the angles obtained in a pre-plan.

Apart from this applicator repertoire, free hand interstitial implants,³¹ although less frequently used for different reasons (highly user-dependent, potentially imprecise, unstable and loss of parallelism between vectors), can represent a helpful choice in some special cases.³²

2.1. Interstitial-vaginal applicators

Ovoids with tandem, evolutions from the classic Manchester, Henschke and Fletcher applicators, modified to include holes in the ovoids for needles insertion in order to optimize dose coverage in parametrial invasion.³³ Varian (VMS, Palo Alto, CA, USA) has a MR compatible Fletcher type applicator with vaginal interstitial component. The equivalent IS-V applicator of Nucletron-Elekta company (Elekta, Veenendaal, The Netherlands) (www.elekta.com/brachytherapy) is called the Utrecht model. It resulted from collaboration with UMC Utrecht.^{21,33} The applicator Fletcher CT/MR (Elekta, Veenendaal, The Netherlands) has had an interstitial component added by the addition of a few holes in the ovoids, thus becoming a template for guiding the needles. Each ovoid has five holes: three located on the outer side and two additional holes on the inner side closest to the tandem in ventral and dorsal directions. The smallest ovoids, instead, have only had the three outer holes pierced.

The vaginal interstitial component can be combined with the ring endocavitary applicator,²⁰ adapted from the classic Stockholm applicator. That is the Vienna applicator from Elekta (Elekta, Veenendaal, The Netherlands). The Vienna applicator is meant to be used with titanium needles. This vendor also has an interstitial ring to be used with plastic needles. Varian (VMS, Palo Alto, CA, USA) and Bebig (Eckert & Ziegler, Berlin, Germany) have commercially available similar solutions offering different ring diameters, uterine tandems and number of inserted needles. Main features of these applicators are found in Table 1.

2.2. Interstitial-perineal applicators

Commercial interstitial-perineal (IS-P) templates²⁵ with a certain holes distribution, serve as a guide for needle insertion across the whole perineum. Recently, Varian (VMS, Palo Alto,

CA, USA) introduced the Kelowna interstitial template, shown in Fig. 1a. The integrated vaginal obturator is used to treat vaginal surface and include a tandem to stretch the dose distribution to the uterine cavity.

Some users have created their own perineal templates with cylinder and tandem, as is the case of the Benidorm applicator.²⁶ This applicator allows for mixing both an intracavitary component (cylinder and intrauterine tube from Elekta) and an interstitial one, commercialized by Lorca Marín S.A, Murcia, Spain (www.lorcamarin.com), Fig. 1b, being fully MR compatible. The template allows insertions in both parallel (to vaginal cylinder) and divergent angles. A second template, carved with three dimples on it, is attached to the first one to insert three markers that simplify the reconstruction process.³⁴ Another institution-specific template, the Pamplona applicator, based on the geometry of the MUPIT applicator from Elekta (Elekta, Veenendaal, The Netherlands), was modified to be used in MR, see Fig. 1c. The metallic parts were replaced by plastic, and used together with the CT/MR cylinder and the ProGuide 294 mm plastic needles from Elekta (Elekta, Veenendaal, The Netherlands).²⁷

2.3. Interstitial-vaginal and perineal applicators

As an example of solutions bringing together vaginal and perineal interstitial elements (IS-V&P) in the same applicator, we have the applicator M.A.C. (Mick-Alektiar-Cohen) from Bebig (Eckert & Ziegler, Berlin, Germany) shown in Fig. 1d. The endocavitary components consist in a tandem and cylinder. Intrauterine tubes of 0° or 30° are available, and vaginal obturators can be loaded to treat disease at any vagina's length. Interstitial component consists of up to 36 concentric channels for the placement of unilateral or bilateral needles for the parametrium. Its main features, components and accessories can be found in the brand catalog (www.bebig.com).

Another example of IS-V&P applicator is the ring and tandem type Venezia applicator from the vendor Elekta (Elekta, Veenendaal, The Netherlands) shown in Fig. 1e. The applicator enables to insert up to 134 plastic needles 6 F (2 mm) 294 mm long, both parallel and divergent to the intrauterine probe. A description of this applicator can be found in the reference (<https://www.elekta.com/brachytherapy/applicators.html>).

3. Practical considerations about the use of MR for cervix cancer BT

The GYN GEC-ESTRO working group published several articles providing considerations and recommendations about the use of MRI regarding, among other matters, appropriate strategies for applicator reconstruction, some technical requirements, adequate MR sequences, patient preparation and applicator commissioning.^{35,36}

MR facilities with magnetic field strength of 1.5 T are widely spread. In addition, the use of 3 T MR is increasing, although it is still rather limited. As the field strength increases, some effects, such as warming of the applicator, larger susceptibility artifacts, especially at the tip end of titanium applicators (ballooning), or distortions, may arise³⁷. Nixon et al. assessed

Table 1 – Summary of the current commercial applicators MR compatible with interstitial component, indicating the maximum number of needles, their length and direction as well as the potentially covered lateral dimension.

[illegible]




Fig. 1 – Applicators with perineal interstitial component. (a) Kelowna applicator (Varian), (b) Benidorm applicator (Lorca Marín), (c) Pamplona applicator, (d) M.A.C Applicator (Bebig) and (e) Venezia applicator (Elekta).

the titanium tandem and ovoid applicator for its safe use at 3 T MR scanner.³⁸ They used a protocol similar to the ASTM International method for assessing radiofrequency induced heating, magnetic displacement and induced torque.^{39–41} They reported difference in the rise in temperature of less than 0.5 °C due to the presence of the applicator placed in a phantom filled with a solution of distilled water. They found no displacement or induced torque. RF induced heating in a 3 T MRI scanner is relatively small and the use of titanium applicators seems to be safe. Nevertheless, their clinical use should be previously verified relative to MR safety parameters.³⁷

Some authors report the implementation into clinical routine of MR sequences for 3 T units.^{42,43}

Adequate patient preparation is required prior to MR scan. Although the preparation procedure may differ between centers, the use of antispasmodics is generally recommended in order to reduce bowel motion during scanning. The use of a saturation band is also recommended to improve contrast in the air-fat interface of subcutaneous tissue.³⁶ Dimopoulos et al. also include the most relevant acquisition parameters recommended for MR imaging.³⁶

T2W sequences, which are the ones recommended by GEC-ESTRO, allow a better target visualization. Ideally, the applicator reconstruction should be performed in the same study set as that used for contouring, thus avoiding the uncertainties due to registration procedures. In some situations, the reconstruction process may represent a challenge, for instance when titanium applicators or interstitial vectors are used. In such cases, additional image studies may be required. Some authors describe the utility of T1 weighted (T1W) sequences, 3D MR images or CT images to help with this issue, as it will be referenced forward in this report.

Special care should be taken regarding the determination of the tip end of the catheters. The slice width employed in axial images (usually 3–4 mm) may lead to certain inaccuracy,

which can be reduced by using additional image sequences, such as para-sagittal⁴⁴ or 3D.⁴⁵

Titanium applicators and needles produce a void signal on the MRI, the determination of the source path inside them being therefore difficult. Furthermore, they induce susceptibility artifacts, ballooning, at the end of the applicator and needles. Many strategies are published in literature in order to deal with this issue, as will be commented further in this text.^{34,46,47}

Prior to the validation of MRI for reconstruction purposes, an assessment of the geometric distortions should be done. These distortions are produced by inhomogeneities of the main magnetic field, but they also may be induced by the patient or the applicator itself. Therefore, since they are patient and sequence dependent, they should be evaluated in the same conditions as those used clinically. Wills et al. report distortions below 2 mm on a 0.35 T MR.⁴⁸ Wang et al.⁴⁹ studied thoroughly the sources and magnitude of geometric distortions and evaluated some correction algorithms provided by vendors. In order to reduce spatial distortions, sequences with high gradients bandwidths should be used. When registering MRI and CT images, special care should be taken if matching is only based on landmark points, since this procedure is more prone to be influenced by MRI distortions.^{50,51} Recently, two articles by Torfeh et al.^{52,53} about the impact of the MRI geometric distortions in BT of cervical cancer show distortions below 0.5 mm in the central region, having small repercussion on dose volume histograms (DVH) related parameters. A review article by Weygand et al. has been recently published⁵⁴ demonstrating a maximum distortion below 3 mm on a 1.5 T MR unit, the magnetic susceptibility induced distortion being smaller than the system dependent one. The largest distortions are found in anatomical landmarks containing air and soft tissue interfaces. Aubrey et al.⁵⁵ report distortions of less magnitude. They found a mean absolute system based distort-

ions of about 1 mm in the central area and 2 mm in the outer region. Distortions related to the presence of the applicators were found to be about 1 mm. Domingo et al.⁵⁶ reported distortions smaller than 2 mm by comparing distances in well defined, and frequently used in obstetrics pelvimetry, bony structures as measured on the MRI acquired at the moment of BT and on CT images.

4. Reconstruction based on MRI

The applicator reconstruction is a step of major relevance within the whole process of treatment planning of any BT procedure. Clear identification of the source path inside the catheters and the applicator is a challenge when using MRI. Inaccuracies in the process of reconstruction may lead to uncertainties in the dose delivered to both target and organs at risk.^{35,57}

Recommendations regarding the reconstruction of applicators in cervical cancer BT advocate the use of MRI as a preferred image modality since, as aforementioned, it is advantageous to perform the reconstruction process in the same image study employed by the physician for contouring, which is T2W, therefore avoiding uncertainties derived from registering procedures between different image sets.^{35,58}

The applicator reconstruction process may be classified mainly in two different modalities: direct and library based reconstructions.

4.1. Direct reconstruction

This exclusive MRI reconstruction method is based on the use of dummies, which usually consist of some kind of catheter filled with some substance that produces a high intensity signal on MRI. Some authors report the use of a CuSO_4 solution,⁴⁶ saline water,⁴⁴ glycerin,⁵⁹ or ultrasonography gel⁴⁷ as filling substances. The signal produced by these filled catheters represents the source trajectory inside the applicator.

In a work by Schindel et al.⁵⁹ seven types of agents to be used as MRI markers are analyzed. They quantified their intensity signal in both T1W and T2W images.

Adequate correspondence between actual source and dummies trajectories should be made during commissioning.

The long-term stability of these dummies must be verified since its characteristics may vary due, for example, to chemical changes or presence of air bubbles, which will require refilling the catheters. Adding some kind of tincture may be useful for detecting the presence of air bubbles, which would yield to an erroneous determination of distal dwell position of the source, especially if they are located in the tip end. The reconstruction is performed by following the signal produced by the dummies throughout every slice. In many treatment planning systems (TPS) this process can also be performed in sagittal, coronal or user-defined reconstructed views (Fig. 2).

The direct reconstruction method is feasible when dummies producing a high intensity signal visible on MRI are available for the applicator under consideration. But in some circumstances the applicator channel diameter is too small and, therefore, the signal produced by the dummy, even if it is available, is too weak. This would be the case of the interstitial component of some applicators.

In case of titanium applicators, dummies are not visible due to magnetic susceptibility artifacts. Haack et al.⁴⁶ propose a method that uses the signal of the artifact. They correlate the positions of the artifact and the source on MRI by comparing it with a CT scanner during commissioning. Therefore, once the artifact is located on the MRI, the source trajectory can be identified.

Hellebust et al.³⁵ suggest another reconstruction method. The void signal produced by plastic applicators on MRI consists of a black area representing the external dimensions of the applicator, but not the source path. For the reconstruction process, a deep knowledge of the applicator geometry and the source trajectories inside is required. During commissioning, relative positions between external markers of the applicator and some source dwell positions should be assessed, for instance, the distance between the tip of the tandem and the source first dwell position. Reference structures such as cavities, dimples or grooves that may be recognized on MRI are useful for reconstruction purposes if we know their positions relative to any dwell position of the source.

In implants with interstitial component, the accurate determination of the tip end of each needle on MRI may be an issue. Perez-Calatayud et al.⁶⁰ suggest a method for the reconstruction of the needles in the Utrecht applicator based on the

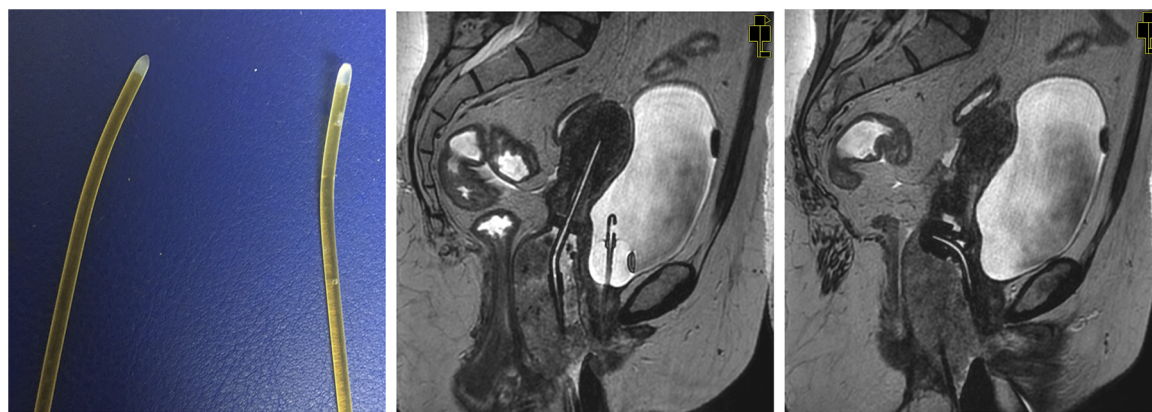

Fig. 2 – Left: dummies filled with water. Iodine tincture is added for coloring purposes providing a better visualization of the distal position and air bubbles. Central: sagittal view showing visualization of the dummy inside a plastic tandem. Right: sagittal view showing visualization of the dummy inside a plastic ovoid.

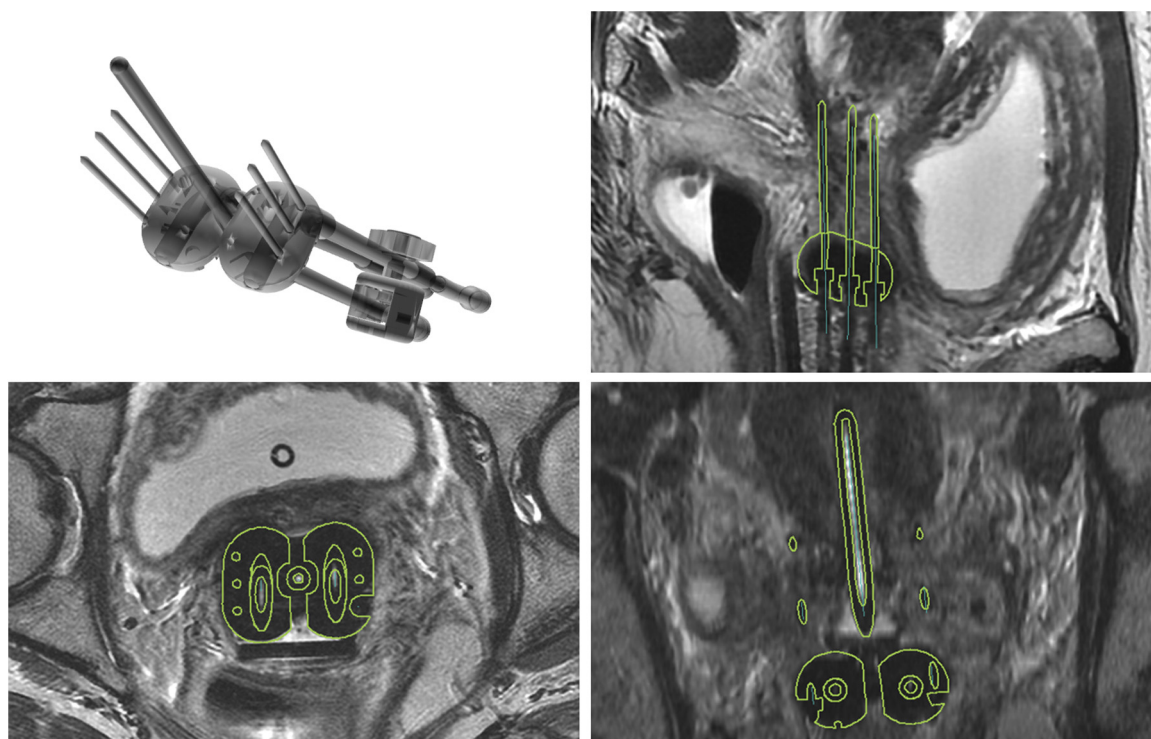


Fig. 3 – Model of the Utrecht applicator with interstitial component and sagittal, axial and coronal views of reconstructed applicator based on the TPS library.

“inserted length” of each needle as reported by the physician at the moment of the insertion, who measures it by means of a ruler engraved on the insertion tool. Once in the TPS, the first step is the location of the exit point of each needle on the ovoid surface. After that, the three views, transversal, sagittal and coronal, should be orientated so that the needle could be visualized in all of them. Finally, the “inserted length” is reproduced in the images with the help of the TPS ruler tool, the needle tip being thus defined.

Adequate commissioning of each applicator is an issue of major importance. Awunor et al.⁶² have quantified the systematic variations and uncertainties with commonly used ring applicators, reporting source positional differences of up to 2.6 mm between ring sets of the same type and geometry. Furthermore, another paper by Awunor et al.⁶³ shows differences in source position determination between different centers using ring applicators, emphasizing the importance of commissioning each ring before clinical use.

4.2. Library of applicators

As mentioned above, it is highly recommended that the reconstruction of the applicator be performed in the same image series in which the target and organs at risk have been contoured. In general, a compromise between small slice thickness and short acquisition times should be achieved in order to avoid image artifacts due to patient movement during image acquisition. However, even with a slice thickness around 3–5 mm, visualization of the applicator can be difficult or inaccurate in T2W images, especially in implants including needles.

With the help of applicator libraries, which contain accurate 3D models, the corresponding applicator configuration can be imported into the TPS, translated and rotated until the model matches the void signal produced by the applicator on the MRI. This procedure is fast, simple, and less prone to reconstruction errors, minimizing the risk of introducing an incorrect applicator geometry (such as wrong ring diameter or ovoid size) because visual verification of the applicator reconstruction can be done directly by checking whether the applicator void signal matches the 3D modeled applicator shape.³⁵ An applicator incorrectly modeled into the library will lead to systematic errors in the reconstruction and, thus, in the dosimetry planning. Therefore, a proper verification of each applicator model is mandatory during the commissioning.

We should differentiate between completely rigid applicators, such as the Vienna applicator, and other composed of several parts that, even though assembled, may suffer slight deviations respect to the model implemented in the library during its insertion into the patient. An example of this is the Fletcher applicator, for which the distance between ovoids may be regulated during insertion for a better adaptation to the vaginal size. If this is the case, each part of the applicator should be reconstructed independently because relative positions between channels are different from the modeled applicator into the library.

Some TPS have the so-called library of applicators available. A detailed geometric model of the applicator containing information about its external shape as well as an internal description of the source dwell positions is included in the model. In this way, the user can fit the external shape of the applicator to the anatomy of the patient, and the

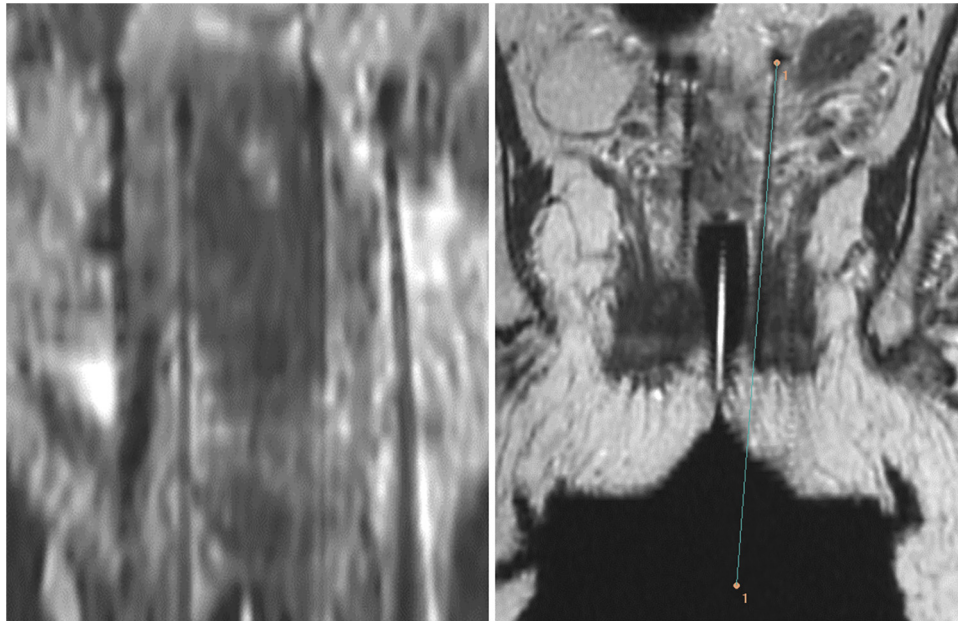


Fig. 4 – Left: “Ballooning” artifact at the tip end of the titanium needles. Right: reconstructed source path inside the needle and position of the tip end of the needle.

actual information of source trajectories and dwell positions is directly incorporated. Commercially available applicators libraries include rigid type applicators such as Fletcher, tandem and ovoids, or tandem and ring, but the interstitial component is not implemented in them. Recently, Otal et al.⁶¹ have proposed a method to incorporate the interstitial component of the Utrecht Applicator (Elekta, Veenendaal, The Netherlands) into the rigid applicator library of the Oncentra Brachy TPS (Elekta, Veenendaal, The Netherlands) (Fig. 3). By means of “third-party” software, the complete geometry of the applicator is modeled including external shape, inner dimensions of the channels and source paths. After modeling is completed, this model is incorporated into the applicators library of the TPS. The user may then match the void signal with the shape of the applicator. As the interstitial component is also included in the model, it is also automatically incorporated in the MRI. The software tools provided by the TPS may be used to slightly adjust the needle trajectories when they bend.

Furthermore, a correct applicator modeling should incorporate the actual source path, since it does not necessarily follow the channel center and it is applicator dependent. Adequate commissioning of applicator and library must be done to validate actual source position against applicator library.

In addition to manually matching the applicator shape and the void signal, the use of anchor points is also a convenient tool in the reconstruction process. Richart et al.³⁴ suggest a method for the in-house developed Benidorm applicator for the treatment of advanced disease. This applicator has a major interstitial component using titanium needles, for which an accurate determination of the tip end in T2W MRI is often difficult due to the presence of the “ballooning” artifact (Fig. 4). In order to determine the most distal dwell position, three A-vitamin pellets, which produce a high intensity signal on MRI, are embedded in the perineal template. The tip of the needle

can then be identified taking into account the inserted needle length as measured by the physician during the insertion. The direction of each needle is obtained by identifying the center of the needle throughout two different slices.

Moreover, a work by Otal et al.⁶¹ shows a method to incorporate into the applicator library of Oncentra Brachy TPS an applicator with a major interstitial component such as the Benidorm template. They use these three A-vitamin pellets as anchor points for reconstruction purposes (Fig. 5).

Schindel et al.⁵⁹ introduced a novel marker flange incorporated to a titanium tandem applicator and filled it with a contrast agent which can be visualized on MR images. It is used for improving the accuracy of the reconstruction process when using the titanium applicator.

Otal et al.⁶⁵ present a method in which three capsules, which are meant to be MRI markers, are embedded in a piece of material, produced by a 3D printer, and attached to the Vienna-type applicator of Bebig (Eckert & Ziegler, Berlin, Germany), which geometry has been modeled and included into the applicator library of Sagiplan TPS. The reconstruction is based on the location of these markers, whose positions with respect to the applicator geometry are accurately known, and then using them as anchor points.

5. Other images modalities different from T2W MR

The void signal produced by the applicators on MRI allows localizing the applicator within the anatomy of the patient, but frequently the source trajectories inside the applicator are not clearly visible. As aforementioned, this problem may be solved by modeling the applicator into a library or if dummies representing the source paths are available, which is not always the case. In such situations the acquisition of additional series

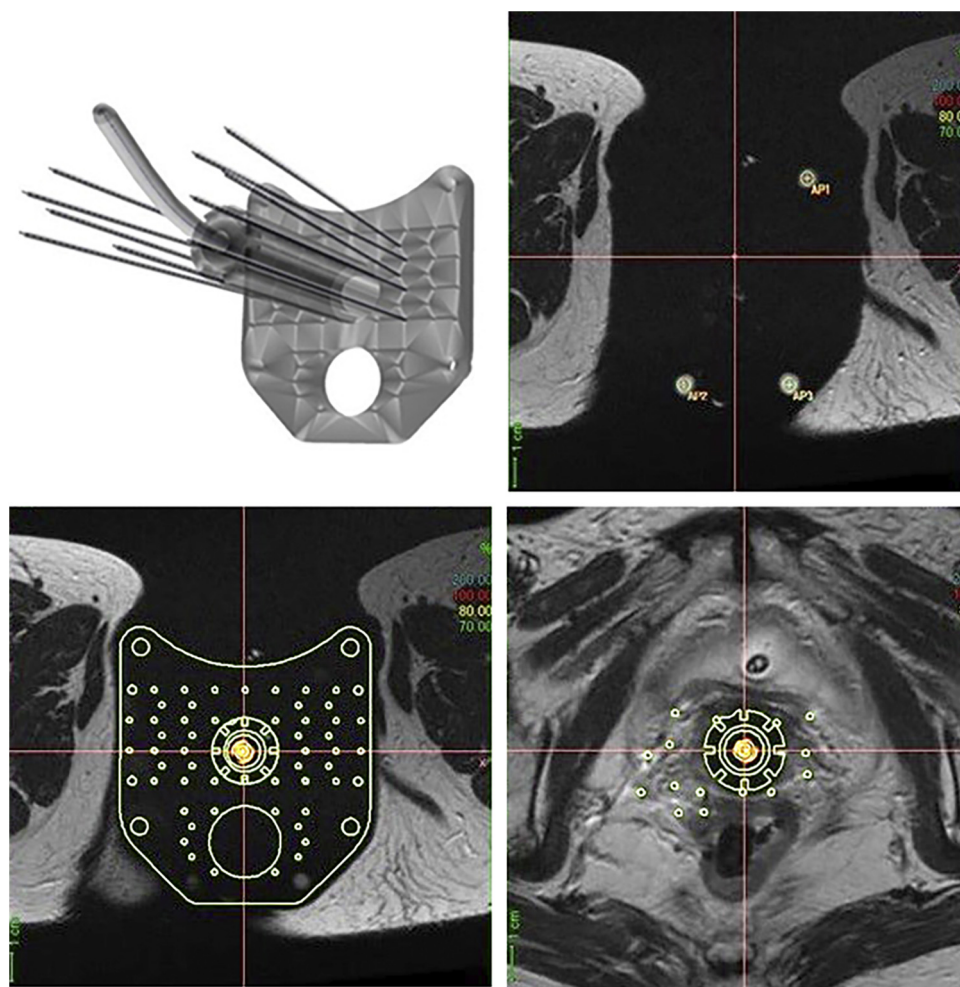


Fig. 5 – Model of the Benidorm template at different levels of the axial view, showing the plate alignment and the use of the A-vitamin pellets as anchor points. Applicator.

such as T1W, 3D MRI or CT may be necessary. Petit et al.⁴⁷ use a 3D radio-frequency Spoiled Gradient known as Echo (SPGR) sequence, with which the titanium Rotterdam tandem and ovoid applicator are accurately reconstructed using a single library applicator. Haack et al.⁴⁶ elaborate a method for the reconstruction of tandem and plastic ring and titanium applicators. They study the visibility on both T2W and T1W sequences of in-house developed MR markers filled with a copper sulfate solution.

On many occasions, the applicators library may not be available on the TPS. In addition, the access to MR may be limited. The use of a complementary, or even an alternative, image set, such as CT, may be necessary. Furthermore, there are scenarios where the use of CT may be advantageous relative to the reconstruction of the applicator or the interstitial needles³⁵ or when using gadolinium in the packing gauge into the vagina.¹⁸

Therefore, in cases of implants with titanium applicators, or implants with an interstitial component, the reconstruction based exclusively on MRI is challenging and may introduce uncertainties. Tanderup et al.⁵⁷ study the influence of random and systematic uncertainties in the applicator reconstruction by modeling translations and rotations of the applicator. They

concluded these uncertainties influence most the DVH parameters of the rectum and bladder and in the anterior–posterior direction. They showed deviations in these parameters up to 5–6% per mm of applicator displacement. Schindel et al.⁶⁴ analyzed the effect of the displacements of the tandem and ovoids as a whole, and the reconstruction uncertainties induced when shifting independently tandem and ovoids in the cranial caudal direction. They found that D2cc of the rectum is the most sensitive parameter to displacements, changing about 10% per ± 1.5 mm shift. In order to avoid dosimetric changes over 10%, reconstruction uncertainties must be kept within 3 mm. Kirisits et al.⁶⁶ published a complete and detailed analysis of uncertainties in BT. Recently, Oonsiri et al.⁶⁷ reported small effects on DVH parameters (D90 HR-CTV and D2cc for the rectum and bladder) of about 3% produced by reconstruction shifts of 1.3 mm.

The susceptibility artifacts induced by titanium applicators make the reconstruction process difficult when it is based on MRI exclusively, especially at the tip end of the applicator or needles.^{35,37,46,62,68} Susceptibility artifacts are position and sequence dependent, and may lead to low reconstruction accuracy, which can be improved by means of an additional CT scan.⁶⁹

Kim et al.³⁷ evaluate the artifacts and distortions produced by tandem and ring and tandem and ovoids in 3 T MRI, finding the T1W sequence favorable in terms of size of the artifacts present in the images. They report that artifacts are smaller than 2 mm at the tip of the applicator for T1W sequences, whereas larger distortions are found in T2W sequences (up to 7 mm), concluding that the exclusive use of MR based BT should be cautiously implemented. Haack et al.⁴⁶ identify the characteristic artifact produced on MRI. They correlate it to the actual position of the source by means of a comparison with a CT image study performed during the commissioning process. Hu et al.⁷⁰ evaluate a proton density weighted sequence (PDW) for the case of a tandem and ovoid titanium applicator using a 1.5 T MR scanner. They show that PDW sequence enhances the uterus-tandem contrast, consequently improving the applicator reconstruction accuracy. Thus, PDW and T2W sequences are conveniently combined for tumor delineation.

Kapur et al.⁴² implement the use of a 3D-balanced steady state free precession (3D b-SSFP) sequence in a 3 T MR scan and recognized it as the best sequence for catheter identification. They perform the reconstruction of intracavitary applicators (tandem and ovoids and tandem and ring), intracavitary–interstitial applications (Utrecht or Vienna Applicators) and interstitial plastic needles (freehand or with the Syed-Neblett template). The accurate determination of the tip end of the needles in T2W images is difficult. Besides, the more needles are used, the worse the visibility of their tip is, due to the ballooning artifact. The 3D b-SSFP sequence enhances the visibility of the needle, improving the reconstruction process. Nevertheless, the reconstruction of the needles on MRI is time consuming and sometimes they make use of a CT for this purpose.

In the cases in which a CT scanner is used as a supporting image modality, the registration with MRI should be carefully performed. It should be based on applicator geometry instead of bony structures, and its uncertainty should be previously assessed. Oinam et al.⁷¹ report a reconstruction method of the tandem and ring applicator by using rigid registration between a CT image set and MRI. They also evaluate the registration uncertainties and conclude that their impact on DVH parameters of the bladder, rectum and sigmoid are very sensitive to antero-posterior shifts. D2cc of the rectum is also largely affected by craneo-caudal registration uncertainties. They conclude that rigid registration of applicator between CT and MR image studies is feasible. This “hybrid” alternative is widely reported in literature in different modalities. Nesvacil et al.⁷² implement a method that uses MR at the first fraction and CT at the subsequent ones. Its use is limited to the case of small tumors and intracavitary component (tandem and ring). An applicator based image registration is performed and the target is transferred to the CT image study. Choong et al.⁷³ use a similar approach with a hybrid method (MR at the first fraction and CT at the following ones), reporting equivalent results in terms of dosimetry and late toxicity compared with treatments based exclusively on MRI. Similar findings are reported for many authors.^{74–77} The hybrid approach represents an alternative when access to MR is limited. Nevertheless, in cases of large tumors or when more complex implants are required, the hybrid approach may be suboptimal, and the use of MRI is recommended.⁷²

Recently, a work has been published investigating the clinical outcome for patients undergoing exclusively MRI plan treatments and comparing it with the outcome of patients undergoing CT plan treatments. They conclude that overall survival is significantly better in the first group while no differences were found in terms of toxicity between the two groups.⁷⁸

Another work by Wang et al.⁷⁹ make a literature review regarding HR-CTV assessment, finding differences in HR-CTV delineation between different image modalities. HR-CTV width is significantly overestimated on CT and its height underestimated. They propose that at least one MRI should be performed for an accurate assessment of the target dimension.

6. Recent and future prospects

An image modality with an increasing and promising role is ultrasonography (US). Besides providing good quality images for contouring purposes of HR-CTV and organs at risk, it has major advantages. It is a cost effective method, widely available in clinical environment and easy to transport. Many authors have reported the use of trans-abdominal (TAUS) or trans-rectal ultrasound (TRUS) as a guidance method during intraoperative insertion of intracavitary applications, as well as a system that provides high quality images of soft tissue for the definition of target volume.^{80–83} The use of US for interstitial BT was reported by Stock et al.⁸⁴ regarding the definition of the target and organs at risk. Sharma et al.⁸⁵ examined its role in terms of preventing perforations of the bladder and rectum during the needle insertion. A strong correlation in the assessment of the volumes of the uterus and the cervix was observed between TAUS and MRI in intracavitary BT.⁸⁶ Many authors have shown the feasibility of US assisted cervix BT compare to MRI.^{81,87–90} Some studies have been presented supporting its use in terms of clinical outcomes of patients undergoing intracavitary BT based on US imaging, showing similar findings that MRI based procedures, following GEC ESTRO recommendations.^{81,91}

At the moment, although recent studies support the use of US for contouring HR-CTV for IGABT of cervical cancer,^{92–94} its exclusive use in the reconstruction process has not yet been implemented in the case of complex and interstitial BT.

Recent work by Petric et al.⁹⁵ analyzes the promising role of the trans-cervical endosonography (TRACE) as an attractive alternative to the MRI based cervical BT. Although important advancements have been done about the use of US in cervical BT, further technical developments regarding hardware and software are required. Currently, the sole use of US cannot substitute the MRI based IGABT, considered as the gold standard.⁹⁶ Recently, Banerjee et al.⁹⁷ published a review article enumerating many aspects of the use of US in BT procedures.

Another attractive field is the development of tools that facilitate the reconstruction process of applicators and their modeling into the applicators libraries available in the TPS. Accurate models of applicators allow us to modify or to add markers that can be incorporated to them and easily prototyped by using a 3D printer. Sphere-shaped markers, for

example, are easy to localize in an MRI or CT sequence with an automatic algorithm allowing a self-reconstruction process of the applicator to be performed over the sequence of images.

Catheter reconstruction is one of the major challenges of the whole BT procedure. A precise source path determination is critical to achieve an accurate dosimetry. Electromagnetic tracking (EMT) has been in use for interventional radiology, guidance of intraoperative surgical procedures, and EBRT. Taking advantage of this experience, recently, EMT technology has been introduced in BT procedures with the aim of improving both reconstruction and dosimetric accuracy. Initially, this technology was used at the time of delivery to verify the catheter spatial distribution by comparing it with that previously assumed on the TPS, but its use in catheter reconstruction for planning is evident and significantly promising. Some authors have demonstrated its feasibility in interstitial prostate BT^{98,99} and breast BT.¹⁰⁰ Its role in cervical cancer BT is still under development. Franz et al.¹⁰¹ and Zhou et al.¹⁰² published two review articles about the use of EMT technologies in radiation oncology BT procedures. Recently, some works have been published evaluating the performance of EMT systems for its use in interstitial BT, reporting an excellent accuracy of about 1 mm.^{103–110}

Manufacturers are working on this development because of its high potential as a component of the HDR Units for both verification and reconstruction assessment.

In vivo dosimetry (IVD) applied to brachytherapy has proven its feasibility as an effective method for dose verification, source localization and applicator reconstruction. Some authors have published papers summarizing the dosimetry technology available for IVD in brachytherapy.^{111,112} Tanderup et al.¹¹³ explored the use of IVD for source tracking in cervix brachytherapy. They developed a method to monitor relative positions of applicator and dosimeters located in the rectum. Source localization of a HDR source was performed by Theriault-Proulx et al.¹¹⁴ by using a single-fiber multipoint plastic scintillation detector (mPSD) in a water phantom, and so, improving the accuracy of detection of the radioactive source position. Nakano et al.^{115,116} developed an algorithm to verify real-time source position by using a diamond detector. They achieved a resolution identifying the location of the source below 3 mm. Kertzschner et al.¹¹⁷ published a review paper in 2014, covering many aspects of the use of IVD in brachytherapy. Recently, a feasibility study for IVD in gynecological applications has been published by Van Gellekom et al.¹¹⁸. They evaluate differences between measured and predicted doses to verify the applicator configuration with the Utrecht Interstitial Fletcher applicators. Real time IVD can be used for source tracking during brachytherapy treatment delivery, as showed recently by Johansen et al.¹¹⁹

The link of EMT with the in-vivo systems will also be a very attractive challenge to guarantee treatment accuracy and verification.

7. Conclusions

A review of the state of the art of the catheter reconstruction on MRI based cervix BT has been presented. The MR compatible intracavitary and interstitial applicators have been

described together with considerations about the use of MRI regarding correct strategies for applicator reconstruction.

Current challenges in reconstruction procedures come from applicators having interstitial components (mainly in the case of plastic tubes) or titanium applicators. Different strategies have been found in the literature such as the use of TPS libraries including the interstitial component or supplementing the applicators with MR pellet markers to be used as anchor points. The use of other images modalities different from MR, such as CT or US, has been analyzed as well as increasingly used electromagnetic tracking technologies in interstitial BT.

Conflict of interest

None declared.

Financial disclosure

None declared.

REFERENCES

- [1]. Logsdon MD, Eifel PJ. Figo IIIB squamous cell carcinoma of the cervix: an analysis of prognostic factors emphasizing the balance between external beam and intracavitary radiation therapy. *Int J Radiat Oncol Biol Phys* 1999;**43**:763–75.
- [2]. Han K, Milosevic M, Fyles A, Pintilie M, Viswanathan AN. Trends in the utilization of brachytherapy in cervical cancer in the United States. *Int J Radiat Oncol Biol Phys* 2013;**87**:111–9.
- [3]. Nag S, Erickson B, Thomadsen B, Orton C, Demanes JD, Peteret D. The American Brachytherapy Society recommendations for high-dose-rate brachytherapy for carcinoma of the cervix. *Int J Radiat Oncol Biol Phys* 2000;**48**(1):201–11.
- [4]. Dimopoulos J, Pötter R, Kirisits C, et al. Impact of systematic MRI assisted treatment planning on local control in cervix cancer: Vienna experience in 145 patients treated by intracavitary ± interstitial brachytherapy from 1998–2003. *Int J Radiat Oncol Biol Phys* 2005;**63**(Suppl. 1):S219–20.
- [5]. International Commission on Radiation Units and Measurements. ICRU report 89: prescribing, recording, and reporting brachytherapy for cancer of cervix. *J ICRU* 2016;**13**(89).
- [6]. Tanderup K, Nielsen SK, Nyvang GB, et al. From point A to the sculpted pear: MR image guidance significantly improves tumour dose and sparing of organs at risk in brachytherapy of cervical cancer. *Radiother Oncol* 2010;**94**:173–80.
- [7]. Pötter R, Georg P, Dimopoulos JCA, et al. Clinical outcome of protocol based image (MRI) guided adaptive brachytherapy combined with 3D conformal radiotherapy with or without chemotherapy in patients with locally advanced cervical cancer. *Radiother Oncol* 2011;**100**(1):116–23.
- [8]. Lindegaard JC, Fokdal LU, Nielsen SK, Juul-Christensen J, Tanderup K. MRI-guided adaptive radiotherapy in locally advanced cervical cancer from a Nordic perspective. *Acta Oncol* 2013;**52**:1510–9.
- [9]. Rijkman EC, Nout RA, Rutten IH, et al. Improved survival of patients with cervical cancer treated with image-guided brachytherapy compared with conventional brachytherapy. *Gynecol Oncol* 2014;**135**:231–8.

- [10]. Tanderup K, Viswanathan AN, Kirisits C, Frank SJ. Magnetic resonance image guided brachytherapy. *Semin Radiat Oncol* 2014;**24**(July (3)):181–91.
- [11]. Sturdza A, Pötter R, Fokdal LU, et al. Image guided brachytherapy in locally advanced cervical cancer: improved pelvic control and survival in retroembry, a multicenter cohort study. *Radiother Oncol* 2016;**120**:428–33.
- [12]. Fokdal L, Sturdza A, Mazeron R, et al. Image guided adaptive brachytherapy with combined intracavitary and interstitial technique improves the therapeutic ratio in locally advanced cervical cancer: an analysis from the retroEMBRACE study. *Radiother Oncol* 2016;**120**:434–40.
- [13]. Kemmerer E, Hernandez E, Ferriss JS, et al. Use of image-guided stereotactic body radiation therapy in lieu of intracavitary brachytherapy for the treatment of inoperable endometrial neoplasia. *Int J Radiat Oncol Biol Phys* 2013;**85**(1):129–35.
- [14]. Sharma DN, Gandhi AK, Sharma S, Rath GK, Jagadesan P, Julka PK. Interstitial brachytherapy vs. intensity-modulated radiation therapy for patients with cervical carcinoma not suitable for intracavitary radiation therapy. *Brachytherapy* 2013;**12**(4):311–6.
- [15]. Jones R, Chen Q, Best R, Libby B, Crandley EF, Showalter TN. Dosimetric feasibility of stereotactic body radiation therapy as an alternative to brachytherapy for definitive treatment of medically inoperable early stage endometrial cancer. *Radiat Oncol* 2014;**9**:164.
- [16]. Tanderup K, Eifel P, Yashar C, Potter R, Grigsby P. Curative radiation therapy for locally advanced cervical cancer: brachytherapy is NOT optional. *Int J Radiat Oncol Biol Phys* 2014;**88**(3):537–9.
- [17]. Haie-Meder C, Pötter R, van Limbergen E. Recommendations from the gynecological (GYN) GEC ESTRO working group: concepts and terms in 3D image based 3D treatment planning in cervix cancer brachytherapy with emphasis on MRI assessment of GTV and CTV. *Radiother Oncol* 2005;**74**:235–45.
- [18]. Potter R, Haie-Meder C, Van Limbergen E, et al. Recommendations from gynecological (GYN) GEC-ESTRO working group (II): concepts and terms in 3D image-based treatment planning in cervix cancer brachytherapy-3D dose volume parameters and aspects of 3D image-based anatomy, radiation physics, radiobiology. *Radiother Oncol* 2006;**78**(1):67–77.
- [19]. Viswanathan AN, Thomadsen B. American Brachytherapy Society consensus guidelines for locally advanced carcinoma of the cervix. Part I: general principles. *Brachytherapy* 2012;**11**(1):33–46.
- [20]. Kirisits C, Lang S, Dimopoulos J, Berger D, Georg D, Pötter R. The Vienna applicator for combined intracavitary and interstitial brachytherapy of cervical cancer: Design, application, treatment planning, and dosimetric results. *Int J Radiat Oncol Biol Phys* 2006;**65**(2):624–30.
- [21]. Nomden CN, de Leeuw AA, Moerland MA, Roesink JM, Tersteeg RJ, Jürgenliemk-Schulz IM. Clinical use of the Utrecht applicator for combined intracavitary/interstitial brachytherapy treatment in locally advanced cervical cancer. *Int J Radiat Oncol* 2012;**82**(4):1424–30.
- [22]. Erickson B, Gillin MT. Interstitial implantation of gynecological malignancies. *J Surg Oncol* 1997;**66**:285–95.
- [23]. Gerbaulet A, Pötter R, Mazeron JJ, Meertens H, van Limbergen E. Interstitial brachytherapy and gynecological cancer. In: *The GEC ESTRO handbook of brachytherapy*. Brussels: ESTRO Publisher; 2002.
- [24]. Beriwal S, Demanes DJ, Erickson B, et al. American Brachytherapy Society consensus guidelines for interstitial brachytherapy for vaginal cancer. *Brachytherapy* 2012;**11**(1):68–75.
- [25]. Martinez A, Cox RS, Edmundson GK. A multiple-site perineal applicator (MUPIT) for treatment of prostatic, anorectal, and gynecologic malignancies. *Int J Radiat Oncol Biol Phys* 1984;**10**(February (2)):297–305.
- [26]. Villalba SR, Sancho JR, Palacin AO, Calatayud JP, Ortega MS. A new template for MRI-based intracavitary/interstitial gynecologic brachytherapy: design and clinical implementation. *J Contemp Brachyther* 2015;**7**(4):265–72.
- [27]. Roviroso A, Samper P, Villafranca E, editors. *Braquiterapia 3D guiada por la imagen*. Grupo de Braquiterapia de SEOR. EdikaMed S.L; 2017. <http://www.seor.es/braquiterapia-3d-guiada-por-la-imagen/>.
- [28]. Hannoun-Levi JM, Chand-Fouche ME, Gautier M, Dejean C, Marcy M, Fouche Y. Interstitial preoperative high-dose-rate brachytherapy for early stage cervical cancer: dose-volume histogram parameters, pathologic response and early clinical outcome. *Brachytherapy* 2013;**12**:148–55.
- [29]. Fokdal L, Tanderup K, Hokland SB, et al. Clinical feasibility of combined intracavitary/interstitial brachytherapy in locally advanced cervical cancer employing MRI with a tandem/ring applicator in situ and virtual preplanning of the interstitial component. *Radiother Oncol* 2013;**107**(1):63–8.
- [30]. Lindegaard JC, Madsen ML, Traberg A, et al. Individualised 3D printed vaginal template for MRI guided brachytherapy in locally advanced cervical cancer. *Radiother Oncol* 2016;**118**(1):173–5.
- [31]. 30th GEC-ESTRO Brachytherapy Course. Budapest 2017 Interstitial Brachytherapy Techniques. Gynecological tumors.
- [32]. Frank SJ, Jhingran A, Levenback C, Eifel PJ. Definitive radiation therapy for squamous cell carcinoma of the vagina. *Int J Radiat Oncol Biol Phys* 2005;**62**(May (1)):138–47.
- [33]. Jürgenliemk-Schulz IM, Tersteeg RJ, Roesink JM, et al. MRI-guided treatment-planning optimization in intracavitary or combined intracavitary/interstitial PDR brachytherapy using tandem ovoid applicators in locally advanced cervical cancer. *Radiother Oncol* 2009;**93**(November (2)):322–30.
- [34]. Richart J, Otal A, Rodríguez S, Nicolás A, DePiaaggio M, Santos M. A practical MRI-based reconstruction method for a new endocavitary and interstitial gynecological template. *J Contemp Brachyther* 2015;**7**(October (5)):407–14.
- [35]. Hellebust TP, Kirisits C, Berger D, et al. Recommendations from Gynaecological (GYN) GEC-ESTRO working group: considerations and pitfalls in commissioning and applicator reconstruction in 3D image-based treatment planning of cervix cancer brachytherapy. *Radiother Oncol* 2010;**96**(2):153–60.
- [36]. Dimopoulos JC, Petrow P, Tanderup K, et al. Recommendations from Gynaecological (GYN) GEC-ESTRO working group (IV): basic principles and parameters for MR imaging within the frame of image based adaptive cervix cancer brachytherapy. *Radiother Oncol* 2012;**103**(1):113–22.
- [37]. Kim Y, Muruganandham M, Modrick JM, Bayouth JE. Evaluation of artifacts and distortions of titanium applicators on 3.0-tesla MRI: feasibility of titanium applicators in MRI-guided brachytherapy for gynecological cancer. *Int J Radiat Oncol Biol Phys* 2011;**80**(3):947–55.
- [38]. Nixon E, Kim Y, Kearney WR, et al. HDR brachytherapy tandem and ovoid titanium applicator safety assessment in 3 T MRI. *Brachytherapy* 2008;**7**:135.
- [39]. ASTM.International. *Designation F2182-02a Standard test method for measurement of radio frequency induced heating near passive implants during magnetic resonance imaging*; 2002.
- [40]. ASTM.International. *Designation F2052-06 Standard Test Method for Measurement of Magnetically Induced Displacement Force on Medical Devices in the Magnetic Resonance Environment*; 2006.

- [41]. ASTM International. *Designation F2213-06 Standard Test Method for Measurement of Magnetically Induced Torque on Medical Devices in the Magnetic Resonance Environment*; 2006.
- [42]. Kapur T, Egger J, Damato A, Schmidt EJ, Viswanathan AN. 3 T MR-guided brachytherapy for gynecologic malignancies. *Magn Reson Imaging* 2012;30(November (9)):1279–90.
- [43]. Dempsey C, Arm J, Best L, Govindarajulu G, Capp A, O'Brien P. Optimal single 3 T MR imaging sequence for HDR brachytherapy of cervical cancer. *J Contemp Brachyther* 2014;6(1):3–9.
- [44]. Perez-Calatayud J, Kuipers F, Ballester F, et al. Exclusive MRI-based tandem and colpostats reconstruction in gynecological brachytherapy treatment planning. *Radiother Oncol* 2009;91(2):181–6.
- [45]. Petric P, Hudej R, Rogelj P, et al. Comparison of 3D MRI with high sampling efficiency and 2D multiplanar MRI for contouring in cervix cancer brachytherapy. *Radiol Oncol* 2012;46(3):242–51.
- [46]. Haack S, Nielsen SK, Lindegaard JC, Gelinek J, Tanderup K. Applicator reconstruction in MRI 3D image-based dose planning of brachytherapy for cervical cancer. *Radiother Oncol* 2009;91(2):187–93.
- [47]. Petit S, Wielopolski P, Rijnsdorp R, Mens JW, Kolkman-Deurloo IK. MR guided applicator reconstruction for brachytherapy of cervical cancer using the novel titanium Rotterdam applicator. *Radiother Oncol* 2013;107(1):88–92.
- [48]. Wills R, Lowe G, Inchley D, Anderson C, Beenstock V, Hoskin P. Applicator reconstruction for HDR cervix treatment planning using images from 0.35 T open MR scanner. *Radiother Oncol* 2010;94(3):346–52.
- [49]. Wang D, Doddrell DM. Geometric distortion in structural magnetic resonance imaging. *Curr Med Imaging Rev* 2005;1(1):49–60.
- [50]. Fransson A, Andreo P, Pötter R. Aspects of MR image distortions in radiotherapy treatment planning. *Strahlenther Onkol* 2001;177(February (2)):59–73.
- [51]. van Heerden LE, Gurney-Champion OJ, van Kesteren Z, et al. Quantification of image distortions on the Utrecht interstitial CT/MR brachytherapy applicator at 3 T MRI. *Brachytherapy* 2016;15(January–February (1)):118–26.
- [52]. Torfeh T, Hammoud R, Vasic A, et al. Impact of MR geometric distortion on brachytherapy in cervical cancer. *Phys Med* 2016;32(Suppl. 3):S229.
- [53]. Torfeh T, Hammoud R, Perkins G, et al. Characterization of 3D geometric distortion of magnetic resonance imaging scanners commissioned for radiation therapy planning. *Magn Reson Imaging* 2016;34(5):645–53.
- [54]. Weygand J, Fuller CD, Ibbott GS, et al. Spatial precision in magnetic resonance imaging-guided radiation therapy: the role of geometric distortion. *Int J Radiat Oncol Biol Phys* 2016;95(4):1304–16.
- [55]. Aubry JF, Cheung J, Morin O, Beaulieu L, Hsu IC, Pouliot J. Investigation of geometric distortions on magnetic resonance and cone beam computed tomography images used for planning and verification of high-dose rate brachytherapy cervical cancer treatment. *Brachytherapy* 2010;9(3):266–73.
- [56]. Domingo C, Richart J, Otal A, Perez-Calatayud J. A simple method to evaluate MRI distortion in Cervical Brachytherapy. Santander: Congreso SEOR; 2017.
- [57]. Tanderup K, Hellebust TP, Lang S, et al. Consequences of random and systematic reconstruction uncertainties in 3D image based brachytherapy in cervical cancer. *Radiother Oncol* 2008;89(2):156–63.
- [58]. Chajon E, Dumas I, Touleimat M, et al. Inverse planning approach for 3D MRI based pulse-dose rate intracavitary brachytherapy in cervix cancer. *Int J Radiat Oncol Biol Phys* 2007;69:955–61.
- [59]. Schindel J, Muruganandham M, Pigge FC, Anderson J, Kim Y. Magnetic resonance imaging (MRI) markers for MRI-guided high-dose-rate brachytherapy: novel marker-flange for cervical cancer and marker catheters for prostate cancer. *Int J Radiat Oncol Biol Phys* 2013;86(June (2)):387–93.
- [60]. Perez-Calatayud J, Carmona V, Lliso F, Pujades MC, Camacho C, Ballester F. Utrecht applicator reconstruction in MRI-based cervix gynecological brachytherapy. *ESTRO* 2011.
- [61]. Otal A, Richart J, Rodriguez S, Santos M, Perez-Calatayud J. A method to incorporate interstitial components into the TPS gynecologic rigid applicator library. *J Contemp Brachyther* 2017;9(1):59–65.
- [62]. Awunor O, Dixon B, Walker C. Direct reconstruction and associated uncertainties of ¹⁹²Ir source dwell positions in ring applicators using gafchromic film in the treatment planning of HDR brachytherapy cervix patients. *Phys Med Biol* 2013;58:3207–25.
- [63]. Awunor O, Berger D, Kirisits C. A multicenter study to quantify systematic variations and associated uncertainties in source positioning with commonly used HDR afterloaders and ring applicators for the treatment of cervical carcinomas. *Med Phys* 2015;8:4472–83.
- [64]. Schindel J, Zhang W, Bhatia S, Sun W, Kim Y. Dosimetric impacts of applicator displacements and applicator reconstruction-uncertainties on 3D image-guided brachytherapy for cervical cancer. *J Contemp Brachyther* 2013;5(4):250–7.
- [65]. Otal A, Richart J, Rodriguez S, et al. Nuevo método de reconstrucción de aplicadores en braquiterapia, en CT y MR, utilizando accesorios mediante una impresora 3D. VII Latin American Congress on Medical Physics. XIII Argentine Congress on Medical Physics 2016.
- [66]. Kirisits C, Rivard MJ, Baltas D, et al. Review of clinical brachytherapy uncertainties: analysis guidelines of GEC-ESTRO and the AAPM. *Radiother Oncol* 2014;110(January (1)):199–212.
- [67]. Oonsiri P, Alisanant P, Mephiew W, Suriyapee S, Amornwichet N. Effect of applicator reconstruction shifting on dosimetric dose-volume histogram parameters during magnetic resonance imaging in brachytherapy for cervical cancer patients. *Indian J Oncol Radiat Biol* 2017;3(1):1–6.
- [68]. Kim Y, Modrick J, Pennington E, Kim Y. Commissioning of a 3D image-based treatment planning system for high-dose-rate brachytherapy of cervical cancer. *J Appl Clin Med Phys* 2016;17(2):405–26.
- [69]. Zhou J, Zamdborg L, Sebastian E. Review of advanced catheter technologies in radiation oncology brachytherapy procedures. *Cancer Manage Res* 2015;7:199–211.
- [70]. Hu Y, Esthappan J, Mutic S, et al. Improve definition of titanium tandems in MR-guided high dose rate brachytherapy for cervical cancer using proton density weighted MRI. *Radiat Oncol* 2013;8:16.
- [71]. Oinam A, Tomar P, Patel F, Singh L, Rai B, Bahl A. CT and MR image fusion of tandem and ring applicator using rigid registration in intracavitary brachytherapy planning. *J Appl Clin Med Phys* 2014;15:191–204.
- [72]. Nesvacil N, Pötter R, Sturdza A, Hegazy N, Federico M, Kirisits C. Adaptive image guided brachytherapy for cervical cancer: a combined MRI-/CT-planning technique with MRI only at first fraction. *Radiother Oncol* 2013;107(1):75–81.
- [73]. Choong ES, Bownes P, Musunuru HB, et al. Hybrid (CT/MRI based) vs. MRI only based image-guided brachytherapy in cervical cancer: Dosimetry comparisons and clinical outcome. *Brachytherapy* 2016;15(1):40–8.

- [74]. Koulis TA, Doll CM, Brown D, et al. Implementation and validation of a combined MRI-CT-based cervical cancer brachytherapy program using existing infrastructure. *Brachytherapy* 2016;15(3):319–26.
- [75]. Berivwal S, Kim H, Coon D, et al. Single magnetic resonance imaging vs magnetic resonance imaging/computed tomography planning in cervical cancer brachytherapy. *Clin Oncol* 2009;21:483–7.
- [76]. Beriwal S, Kannan N, Kim H, et al. Three-dimensional high dose rate intracavitary image-guided brachytherapy for the treatment of cervical cancer using a hybrid magnetic resonance imaging/computed tomography approach: feasibility and early results. *Clin Oncol* 2011;23:685–90.
- [77]. Vargo JA, Beriwal S. Image-based brachytherapy for cervical cancer. *World J Clin Oncol* 2014;5(December (5)):921–30.
- [78]. Kamran SC, Manuel MM, Cho LP, et al. Comparison of outcomes for MR-guided versus CT-guided high-dose-rate interstitial brachytherapy in women with locally advanced carcinoma of the cervix. *Gynecol Oncol* 2017;145(2):284–90.
- [79]. Wang F, Tang Q, Lv G, et al. Comparison of computed tomography and magnetic resonance imaging in cervical cancer brachytherapy: A systematic review. *Brachytherapy* 2017;16(2):353–65.
- [80]. van Dyk S, Narayan K, Fisher R, Bernshaw D. Conformal brachytherapy planning for cervical cancer using transabdominal ultrasound. *Int J Radiat Oncol Biol Phys* 2009;75(1):64–70.
- [81]. Narayan K, van Dyk S, Bernshaw D, Pearly Khaw LM, Kondalsamy-Chennakesavan S. Ultrasound guided conformal brachytherapy of cervix cancer: survival, patterns of failure, and late complications. *J Gynecol Oncol* 2014;25(3):206–13.
- [82]. Rao PB, Ghosh S. Routine use of ultrasound guided tandem placement in intracavitary brachytherapy for the treatment of cervical cancer – a South Indian institutional experience. *J Contemp Brachyther* 2015;7:352–6.
- [83]. Dyk S, Schneider M, Kondalsamy-Chennakesavan S, Bernshaw D, Narayan K. Ultrasound use in gynecologic brachytherapy: time to focus the beam. *Brachytherapy* 2015;14(3):390–400.
- [84]. Stock RG, Chan K, Terk M, Dewyngaert JK, Stone NN, Dotting P. A new technique for performing Syed-Neblett template interstitial implants for gynecologic malignancies using transrectal-ultrasound guidance. *Int J Radiat Oncol Biol Phys* 1997;37:819–25.
- [85]. Sharma DN, Rath GK, Thulkar S, Kumar S, Subramani V, Julka PK. Use of transrectal ultrasound for high dose rate interstitial brachytherapy for patients of carcinoma of uterine cervix. *J Gynecol Oncol* 2010;21(1):12–7.
- [86]. Mahantshetty U, Khanna N, Swamidas J, et al. Trans-abdominal ultrasound (US) and magnetic resonance imaging (MRI) correlation for conformal intracavitary brachytherapy in carcinoma of the uterine cervix. *Radiother Oncol* 2012;102(1):130–4.
- [87]. van Dyk S, Sci DA, Kondalsamy-Chennakesavan S, Schneider M, Bernshaw D, Narayan K. Comparison of measurements of the uterus and cervix obtained by magnetic resonance and transabdominal ultrasound imaging to identify the brachytherapy target in patients with cervix cancer. *Int J Radiat Oncol Biol Phys* 2014;88(4):860–5.
- [88]. Dyk S, Kondalsamy-Chennakesavan S, Schneider M, Bernshaw D, Narayan K. Assessing changes to the brachytherapy target for cervical cancer using a single MRI and serial ultrasound. *Brachytherapy* 2015;14(6):889–97.
- [89]. Nesvacil N, Schmid M, Pötter R, Kronreif G, Kirisits C. Combining transrectal ultrasound and CT image-guided adaptive brachytherapy of cervical cancer: proof of concept. *Brachytherapy* 2016;15:839–44.
- [90]. Tamaki T, Miyaura K, Murakami T, et al. The use of trans-applicator intracavitary ultrasonography in brachytherapy for cervical cancer: phantom study of a novel approach to 3D-image brachytherapy. *J Contemp Brachyther* 2017;9(2):151–7.
- [91]. Dyk S, Narayan K, Bernshaw D, et al. Clinical outcomes from an innovative protocol using serial ultrasound imaging and a single MR image to guide brachytherapy for locally advanced cervix cancer. *Brachytherapy* 2016;15(6):817–24.
- [92]. Schmid MP, Nesvacil N, Pötter R, Kronreif G, Kirisits C. Transrectal ultrasound for image-guided adaptive brachytherapy in cervix cancer – an alternative to MRI for target definition? *Radiother Oncol* 2016;120(3):467–72.
- [93]. St-Amant P, Foster W, Froment MA, Aubin S, Lavallée MC, Beaulieu L. Use of 3D transabdominal ultrasound imaging for treatment planning in cervical cancer brachytherapy: Comparison to magnetic resonance and computed tomography. *Brachytherapy* 2017;16(July–August (4)):847–54.
- [94]. Kamrava M. Potential role of ultrasound imaging in interstitial image based cervical cancer brachytherapy. *J Contemp Brachyther* 2014;6(2):223–30.
- [95]. Petric P, Kirisits C. Potential role of TRAns Cervical Endosonography (TRACE) in brachytherapy of cervical cancer: proof of concept. *J Contemp Brachyther* 2016;8(3):215–20.
- [96]. Tanderup K, El Naga I, Carlson D, Klein E. Advances in image-guided brachytherapy. *Int J Radiat Oncol* 2017;97(5):873–5.
- [97]. Banerjee S, Kataria T, Gupta D, et al. Use of ultrasound in image-guided high-dose-rate brachytherapy: enumerations and arguments. *J Contemp Brachyther* 2017;9(2):146–50.
- [98]. Zhou J, Sebastian E, Mangona V, Yan D. Real-time catheter tracking for high-dose-rate prostate brachytherapy using an electromagnetic 3D-guidance device: a preliminary performance study. *Med Phys* 2013;40:021716.
- [99]. Bharat S, Kung C, Dehghan E, et al. Electromagnetic tracking for catheter reconstruction in ultrasound-guided high dose rate brachytherapy of the prostate. *Brachytherapy* 2014;1(3):640–50.
- [100]. Kellermeier M, Herbolzheimer J, Kreppner S, Lotter M, Strnad V, Bert C. SU-F-BRA-02: electromagnetic tracking in brachytherapy as an advanced modality for treatment quality assurance. *Med Phys* 2015;42:3533–4.
- [101]. Franz AM, Haidegger T, Birkfellner W, Cleary K, Peters TM, Maier-Hein L. Electromagnetic tracking in medicine: a review of technology, validation, and applications. *IEEE Trans Med Imaging* 2014;3(8):1702–25.
- [102]. Zhou J, Zamdborg L, Sebastian E. Review of advanced catheter technologies in radiation oncology brachytherapy procedures. *Cancer Manage Res* 2015;7:199–211.
- [103]. Damato AL, Viswanathan AN, Don SM, Hansen JL, Cormack RA. A system to use electromagnetic tracking for the quality assurance of brachytherapy catheter digitization. *Med Phys* 2014;41:101702.
- [104]. Mehrtash A, Damato A, Pernelle G, et al. EM-navigated catheter placement for gynecologic brachytherapy: an accuracy study. *Proc SPIE Int Soc Opt Eng* 2014;9036, 90361f.
- [105]. Boutaleb S, Racine E, Fillion O, et al. Performance and suitability assessment of a real-time 3D electromagnetic needle tracking system for interstitial brachytherapy. *J Contemp Brachyther* 2015;7:280–9.
- [106]. Poulin E, Racine E, Binnekamp D, Beaulieu L. Fast, automatic, and accurate catheter reconstruction in HDR brachytherapy using an electromagnetic 3D tracking system. *Med Phys* 2015;42:1227.

- [107]. Bert C, Kellermeier M, Tanderup K. Electromagnetic tracking for treatment verification in interstitial brachytherapy. *J Contemp Brachyther* 2016;**8**:448–53.
- [108]. Lugez E, Sadjadi H, Joshi CP, Akl SG, Fichtinger G. Improved electromagnetic tracking for catheter path reconstruction with application in high-dose-rate brachytherapy. *Int J Comput Assist Radiol Surg* 2017;**12**:681–9.
- [109]. Kellermeier M, Herbolzheimer J, Kreppner S, Lotter M, Strnad V, Bert C. Electromagnetic tracking (EMT) technology for improved treatment quality assurance in interstitial brachytherapy. *J Appl Clin Med Phys* 2017;**18**:211–22.
- [110]. Götz TI, Ermer M, Salas-González D, et al. On the use of multi-dimensional scaling and electromagnetic tracking in high dose rate brachytherapy. *Phys Med Biol* 2017;**62**:7959–80.
- [111]. Cygler JE, Tanderup K, Beddar S, Perez-Calatayud J. In vivo dosimetry in Brachytherapy. In: *Comprehensive brachytherapy: physical and clinical aspects*. Boca Raton, FL: Taylor & Francis; 2012. p. 379–96.
- [112]. Tanderup K, Beddar S, Andersen CE, Kertzscher G, Cygler JE. In vivo dosimetry in brachytherapy. *Med Phys* 2013;**40**:1–15.
- [113]. Tanderup K, Christensen JJ, Granfeldt J, et al. Geometric stability of intracavitary pulsed dose rate brachytherapy monitored by in vivo rectal dosimetry. *Radiother Oncol* 2006;**79**:87–93.
- [114]. Theriault-Proulx F, Beddar S, Beaulieu L. On the use of a single-fiber multipoint plastic scintillation detector for ^{192}Ir high-dose-rate brachytherapy. *Med Phys* 2013;**40**:062101.
- [115]. Nakano T, Suchowerska N, Bilek MM, McKenzie DR, Ng N, Kron T. High dose-rate brachytherapy source localization: positional resolution using a diamond detector. *Phys Med Biol* 2003;**48**:2133–46.
- [116]. Nakano T, Suchowerska N, McKenzie DR, Bilek MM. Real-time verification of HDR brachytherapy source location: implementation of detector redundancy. *Phys Med Biol* 2005;**50**:319–27.
- [117]. Kertzscher G, Rosenfeld A, Beddar S, et al. In vivo dosimetry: trends and prospects for brachytherapy. *Br J Radiol* 2014;**87**:20140206.
- [118]. Van Gellekom MPR, Canters RAM, Dankers FJWM, Loopstra A, van der Steen-Banasik EM, Haverkort MAD. In vivo dosimetry in gynecological applications. A feasibility study. *Brachytherapy* 2018;**17**(January–February (1)):146–53.
- [119]. Johansen JG, Rylander S, Buus S, et al. Time-resolved in vivo dosimetry for source tracking in brachytherapy. *Brachytherapy* 2018;**17**(January–February (1)):122–32.