


Available online at [www.sciencedirect.com](http://www.sciencedirect.com)

ScienceDirect

journal homepage: <http://www.elsevier.com/locate/rpor>

## Review

# Functional imaging in radiation therapy planning for head and neck cancer



Luis A. Pérez Romasanta<sup>a,\*</sup>, María José García Velloso<sup>b</sup>,  
Antonio López Medina<sup>c</sup>

<sup>a</sup> Radiation Oncology, Hospital Universitario de Salamanca, Ps. San Vicente 58, 37007 Salamanca, Spain

<sup>b</sup> Nuclear Medicine, Clínica Universidad de Navarra, Pamplona, Spain

<sup>c</sup> Medical Physics Department and Radiological Protection, Galaria – Hospital do Meixoeiro – Complexo Hospitalario Universitario de Vigo, Vigo, Spain

## ARTICLE INFO

## Article history:

Received 4 May 2013

Received in revised form

16 October 2013

Accepted 16 October 2013

## Keywords:

Radiotherapy planning

Functional imaging

Metabolic imaging

PET/CT

## ABSTRACT

Functional imaging and its application to radiotherapy (RT) is a rapidly expanding field with new modalities and techniques constantly developing and evolving. As technologies improve, it will be important to pay attention to their implementation. This review describes the main achievements in the field of head and neck cancer (HNC) with particular remarks on the unsolved problems.

© 2013 Greater Poland Cancer Centre. Published by Elsevier Urban & Partner Sp. z o.o. All rights reserved.

## 1. Positron Emission Tomography/Computed Tomography (PET/CT) in RT planning

### 1.1. Introduction

PET is a significant advance in cancer imaging with great potential for optimizing RT planning and thereby improving outcomes for head and neck cancer patients. The use of PET-CT in RT planning was reviewed by an international panel. The International Atomic Energy Agency (IAEA) organized two synchronized and overlapping consultants' meetings with experts from different regions of the world in Vienna in July

2006. Nine experts and three IAEA staff evaluated the available data on the use of PET in RT planning, and considered practical methods for integrating it into routine practice. For RT planning, FDG was the most valuable pharmaceutical. There was evidence for utility of PET in head and neck cancers, with promising preliminary data in many other cancers. The best available approach employs integrated PET-CT images, acquired on a dual scanner in the radiotherapy treatment position after administration of tracer according to a standardized protocol, with careful optimization of images within the RT planning system and carefully considered rules for contouring tumour volumes. PET will play an increasing valuable role in RT planning for a wide range of cancers.<sup>1</sup> More recent

\* Corresponding author. Tel.: +34 627744220.

E-mail addresses: [lapr@usal.es](mailto:lapr@usal.es), [lapr06@gmail.com](mailto:lapr06@gmail.com) (L.A. Pérez Romasanta).

review confirm the value of PET/CT as an adjunct in RT planning for two main reasons: better identification of the disease extent and characterization of the biological behaviour of the disease.<sup>2</sup>

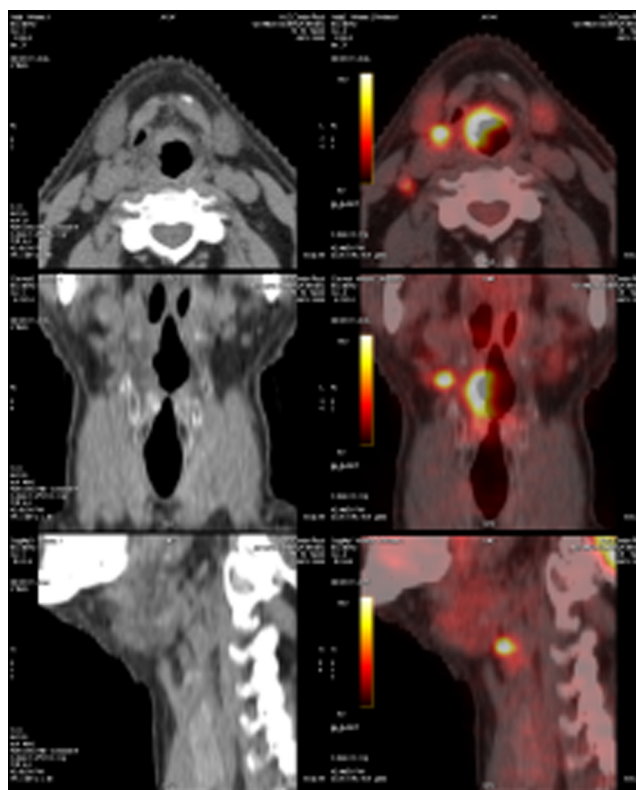
### 1.2. Advantages and disadvantages

Besides the obvious improvement in patient selection for radical treatment due to exclusion of distant metastases and of synchronous primary malignancy,<sup>3,4</sup> there are potential advantages to the use of 18F-FDG-PET/CT in RT planning for HNC: reduction of inter-observer variation in target volume delineation,<sup>5</sup> particularly when an institutional contouring protocol is developed,<sup>6</sup> smaller GTV volumes,<sup>7</sup> and more accurate identification of positive lymph nodes.<sup>8</sup>

The main disadvantages are the limited spatial resolution of PET images, the lower utility for identifying occult nodal metastases,<sup>8</sup> and the false positive readings due to inflammation, infection, radiation effect or physiological uptake.<sup>2</sup> As the spatial resolution of a CT image is below 1 mm, a neat tumour margin is frequently displayed, particularly in contrast-enhanced studies. This is not the case with PET images where the spatial resolution is just below 5 mm. This fact, combined with the background uptake of contrast due to physiologic processes, contribute to the fuzzy appearance of tumour edges. PET/CT does not add value over CT or MRI for T staging<sup>9</sup> and superficial tumour spread in HNC is often missed.<sup>7</sup> Therefore, a limitation of the PET image is its inability to define depth of invasion and relation of tumours to neighbouring structures (Figure 1).

Spatial resolution of PET limits its utility to characterize the micro-regional distribution of tumours phenotype. Pre-clinical studies have shown discrepancies between imaging with a small-animal PET scanner with a spatial resolution of 2.7 mm and the underlying microscopic reality represented by autoradiography.<sup>10</sup> Such a discrepancy means the macroscopic assessment of tumours with molecular imaging might not necessarily reflect their micro-regional distribution.<sup>11</sup> Many micro-regional tumour areas are likely to coexist within one clinical PET voxel. Negative scan findings cannot, therefore, exclude the presence of microscopic tissue involvement, and precise anatomic location of the signal can be difficult. Despite these inherent weaknesses, PET imaging has proven to generate quantitative tumour maps that accurately reflect the underlying microscopic reality in an animal model with a clinical realistic image contrast.<sup>12</sup> As the set-up tolerance is up to 3 mm for patients with HNC immobilized in thermoplastic masks, caution should also be given to dose prescriptions to a voxel of approximately 4 mm size as its precise location intra- or inter-fraction cannot be assured. Heterogeneous dose prescriptions adapted by voxel may not be possible with current delivery systems due to limited dose distribution spatial resolution and target localization inaccuracies related to set-up and organ motion errors. Furthermore, the microenvironment of treated and untreated tumours changes with time adding uncertainty to voxel oriented dose distributions.<sup>13,14</sup>

Accurate assessment of primary tumour size, extent, and depth of invasion is pertinent to planning the most



**Fig. 1 – 18F-FDG PET/CT on a patient with a supraglottic tumour. Avid tracer uptake helps to identify a positive lymph node located immediately lateral to the primary tumour. Physiologic uptake in the right vocal cords besides the fuzzy appearance of tumour borders due to low spatial resolution of PET image hamper the accurate delineation of tumour contours.**

appropriate local treatment. The most appreciated utility of PET/CT is the detection of an unknown primary in situations where there is a strong clinical suspicion of a primary despite a negative exploration and biopsy. It has been demonstrated that primary tumour detection was significantly higher with PET or PET/CT compared with CT or magnetic resonance imaging (MRI) due to a higher sensitivity.<sup>15</sup>

### 1.3. The segmentation problem

Before PET-based GTVs can reliably and reproducibly be incorporated into high-precision RT planning, operator-independent segmentation tools have to be developed and validated.<sup>16,17</sup> Simple visual interpretation of the PET signal is most commonly applied but is highly operator-dependent, as it is susceptible to the window-level settings of the images and to interpretation discrepancies.<sup>5</sup> Visual interpretation has significant inter and intra-observer variations which may be improved when criteria for tissue definition is included during interpretation.<sup>5</sup> Variability of the GTV based on PET images ( $GTV_{PET}$ ) delineation could be avoided adopting more objective methods, such as iso-contouring based on a fixed standardized uptake value (SUV), or relative thresholds such as a proportion of the maximum SUV

( $SUV_{max}$ ) in the tumour. Several reports have been published which compared different fixed or relative thresholding as  $GTV_{PET}$  delineation method.<sup>18,19</sup> Metabolic treatment volumes defined in relation to  $SUV_{max}$  are prone to variability between centres because  $SUV_{max}$  is highly dependent on contrast recovery and noise properties that vary across scanners and reconstructive protocols. Daisne et al. described a variable threshold adaptive to the signal-to-background ratio ( $R_{S/B}$ ) in their study on laryngeal cancer patients.<sup>20</sup> Subsequently, this group validated their results against volumetric histopathology for primary tumours of the larynx-hypopharynx.<sup>7</sup> Some authors have introduced gradient-based segmentation tools validated against phantoms and macroscopic specimens of laryngeal tumours (Geets X 2007),<sup>21</sup> background-subtracted relative-threshold level (RTL) method,<sup>22</sup> fuzzy locally adaptive Bayesian (FLAB) method,<sup>23</sup> and iterative TrueX algorithm.<sup>24</sup> Few segmentation algorithms have been clinically or histologically validated and this is a source of uncertainty for volume definition.

#### 1.4. Sensitivity and specificity

How the sensitivity and specificity of a particular imaging modality influence the radiation planning process depends on the underlying objective of the treatment. If the objective is to avoid missing a tumour at any expense, a highly sensitive approach needs to be selected. Such a selection will result in a lower specificity and in the inclusion of non-neoplastic tissue in the target volume. However, this approach reduces the likelihood of missing neoplastic cells. If, on the other hand, the aim is to avoid including non-neoplastic cells in the target volume to protect normal tissue, a highly specific approach needs to be elected. However, such an approach reduces sensitivity and increases the risk for missing tumour cells. When 18F-FDG PET/CT is introduced with treatment planning purposes, its sensitivity and specificity need to be compared with those of the standard test, this is, CT, and its potential impact on treatment planning needs to be determined. CT and 18F-FDG PET/CT perform with comparable diagnostic accuracies.<sup>25</sup> A meta-analysis has summarized the available literature on the use of 18FDG-PET for the assessment of the cervical lymph node status in squamous cell HNC. According to Kyzas et al., sensitivity and specificity of FDG PET were 80% and 86%, respectively, and of conventional diagnostic tests were 75% and 79%, respectively.<sup>8</sup> The detection of retropharyngeal lymph node metastases is particularly advantageous with FDG PET-CT. Chu et al. showed that adding FDG PET-CT to the conventional CT/MRI work up increased diagnostic efficacy, both sensitivity (89% vs 62%) and specificity (86% vs 60%).<sup>26</sup>

A potentially interesting use of 18F-FDG PET is staging for patients with nodes found negative (node negative) by other imaging modalities, in whom the issue could be to avoid treating neck nodes if an 18F-FDG PET examination is negative. However, data have indicated that in the node-negative neck, the sensitivity of 18F-FDG PET, compared with that of examination of a pathologic specimen after neck node dissection, is only about 70%.<sup>25</sup> PET/CT in its current stage, mainly impeded by a low spatial resolution, does not appear to offer an advantage in staging the clinically N0 neck due to high rates of

false positives and limited sensitivity for small metastatic deposits and, consequently, it is not likely to be superior for the selection of the target volume in neck lymph nodes.<sup>27</sup> The management of the N0 neck should not be based on PET-CT findings alone.<sup>28</sup> Furthermore, diverse PET segmentation tools identify a variable proportion of nodes classified as enlarged or marginally enlarged on CT, precluding its implementation in routine practice for neck volume definition until proper validation could be accomplished.<sup>29</sup>

#### 1.5. PET derived volumes for dose escalation studies

Due to the sub-optimal outcome for a significant proportion of patients with HNC, PET derived GTVs are an attractive target for dose escalation. The dose required to overcome radioresistance within the target volume is unknown. Biological modelling could guide the dose planning optimization process matching the heterogeneous dose distribution to the pretended radioresistant tumour subvolumes.<sup>30,31</sup> Current treatment prescriptions are already close to patient tolerance making it difficult to expand the therapeutic window through this strategy. Some clinical studies have been published evaluating the outcome of 18F-FDG-PET based dose escalation.<sup>32</sup> 18F-FMISO PET has also been used to define a hypoxic sub-volume and theoretical planning studies have demonstrated the potential to dose-escalate to this sub-volume.<sup>33,34</sup> One of the limitations of 18F-FMISO imaging in this setting may be its temporal variability. Nehmeh et al.<sup>35</sup> have shown in a study with 14 evaluable patients who underwent two baseline 18F-FMISO scans 3 days apart, a voxel by voxel analysis of putative hypoxic areas revealed a strong correlation across the two time points in only 6 patients. To date, no clinical studies have been published with outcome of dose escalation to 18F-FMISO-defined volumes. Troost et al.<sup>16,17</sup> demonstrated that high proliferative tumour subvolumes, as defined by 18F-FLT PET, can provide the basis for an IMRT plan with dose escalation within these regions.

#### 1.6. PET-image voxel-guided RT

Dose painting by numbers is a voxel-level prescription of dose based on a mathematical transformation of the image intensity of individual pixels. Quantitative use of images to decide both where and how to deliver radiation therapy in an individual case is also called theragnostic imaging. Dose painting targets are imaging surrogates for cellular or microenvironmental phenotypes associated with poor radioresponsiveness.<sup>36</sup> Planning and feasibility studies and preliminary tolerance studies have been published.<sup>37–39</sup> Feasibility studies using deformable image co-registration in three-phase adaptive dose-painting-by-numbers for head and neck cancer have been published.<sup>40</sup> Irradiation of smaller target volumes might have contributed to mild acute toxicity with no measurable decrease in tumour control.

#### 1.7. PET-image as a biomarker with prognostic and/or predictive value

18F-FDG-PET imaging might identify patients who are less likely to respond to current treatment strategies and may

benefit from alternative treatments, dose escalation, or early salvage options. Monitoring of early response during treatment could allow treatment modification or adaptation and this has been shown in a proof-of-principle study by Geets et al.<sup>41</sup> Several published studies have demonstrated this role using baseline 18F-FDG-PET parameters,<sup>42–49</sup> or 18F-FDG-PET imaging acquired 2–4 months following completion of treatment.<sup>50–53</sup> The optimum timing of 18F-FDG-PET imaging following treatment is uncertain due to 18F-FDG uptake in non-malignant inflammatory tissue which complicates interpretation.<sup>54</sup> Several studies have shown that the level of hypoxia depicted by 18F-FMISO PET before treatment correlates with loco-regional failure.<sup>55,56</sup> A change in 18F-FLT uptake early during radiotherapy of chemoradiotherapy is a strong indicator for long-term outcome.<sup>13,14</sup>

### 1.8. Clinical implementation and standardization

Despite a decade of activity in this field, functional imaging is yet to be implemented into routine clinical practice. The reason for this relates to most data being generated from single institution series with variations in imaging modality, sequence acquisition, data processing and analysis tools. The next challenge is implementing PET imaging and tackling the associated uncertainties. As preliminary findings are validated in larger studies, so attention to standardization of protocols and image processing and data analysis must occur. This is necessary not only for implementing findings from studies performed at other institutions but, most important, in the design for multicenter trials which must include rigorous quality assurance.<sup>57</sup> In the image acquisition process of PET-CT for RT planning, radiation oncologists and nuclear medicine physicians need to work together in close collaboration. This partnership is crucial due to the enormous organizational effort required and to assure correct interpretation of the imaging studies. Medical physicists also play an essential role due to their involvement in standardizing the process and in quality control. For all these reasons, multidisciplinary collaboration is absolutely essential if PET-CT imaging is to fulfil its potential for RT planning. Recommendations on the use of PET-CT in RT planning have been published previously, including those described by the European Society of Radiation Oncology (ESTRO) and European Association of Nuclear Medicine (EANM), in an attempt to standardize PET image acquisition, processing and reporting.<sup>58</sup> However, these are yet to be fully adopted. Consensuated recommendations by a working party of the Spanish of Radiation Oncology, Nuclear Medicine, and Medical Physics have been also published recently in these Reports.<sup>59</sup>

### 1.9. Conclusion

PET/CT is being used at present for volume definition and as a biomarker. Studies with multiple tracers obtained at different time points are testing the potential value of this modality for stratification of patients and RT dose escalation. Nevertheless, some intrinsic limitations as coarse spatial resolution and false positive readings besides methodological problems

like segmentation algorithm of choice and lack of standardization could hamper its clinical implementation.

## 2. MRI for RT planning

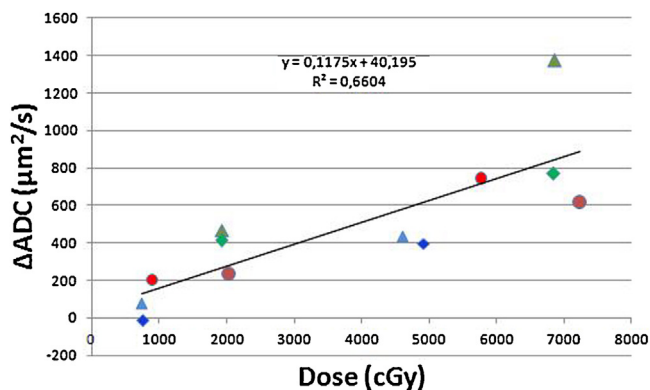
MRI can add to the radiotherapy treatment planning (RTP) process by providing excellent and improved characterization of soft tissues compared with CT and better spatial resolution compared with PET. MRI can benefit treatment planning by improving target volume delineation and assessment of planning margins in many cancer subtypes in sites such as the brain, spinal cord, soft tissues of the head and neck, trunk and limbs.<sup>60</sup> Techniques such as dynamic contrast enhanced MRI (DCEMRI) and diffusion MRI to better characterize tissue and tumour regions, BOLD technique (Blood Oxygen Level Dependent) for hypoxic areas, as well as ultrafast volumetric cine MR sequences to define temporal changes of target and organ at risk have all increased the scope and utility of MRI for treatment planning. Information from these MR developments may permit treatment individualization, strategies of dose escalation and image-guided radiotherapy.<sup>60</sup>

Furthermore, functional MRI is an important tool to understand the dynamics of tumour response to radiotherapy with potential application for adapting and individualizing the treatment. In order to adapt biological models to data from functional imaging, treatment, response and radio resistant volumes must be surveyed. This goal can be achieved with ADC maps (apparent diffusion coefficient) from diffusion weighted MRI (DWMRI). Once a predictive model of tumour response based on functional image is built up, a new optimization method will be achievable. The integration of functional MRI in the radiotherapy planning and treatment response evaluation has attracted the interest of different research groups worldwide,<sup>61–65</sup> up to the assembly of hybrid linac-MRI machines.<sup>66</sup>

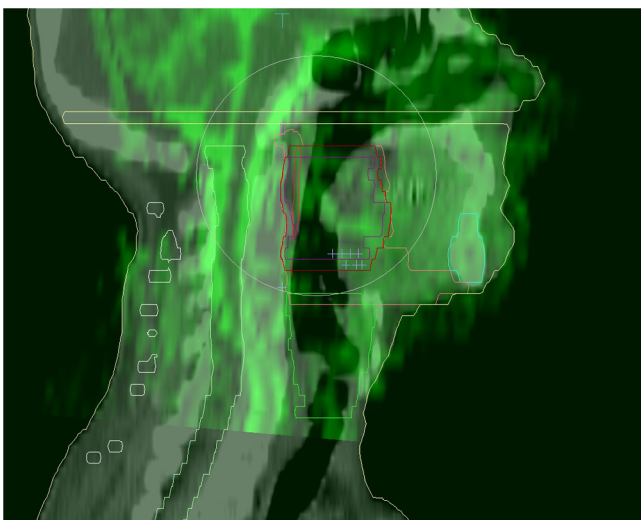
### 2.1. DWMRI/ADC

DWMRI measures the diffusion of protons in a medium. It is based in the attenuation of the signal according to Stejskal & Tanner model.<sup>67</sup> Tumour cells are bigger than normal cells and the extracellular volume is smaller in tumour regions, then the freedom of movements of protons in tumour regions is restricted. The logarithm of the signal attenuation is a function of the applied gradient, gap between pulses of gradient, and the pulse duration. Varying these parameters during acquisition, the apparent diffusion coefficient can be calculated for each voxel.

Fig. 2 shows the increment in ADC value as dose is delivered in seven different lesions of two patients (2 tumour lesions and 5 nodes) at different time points along the treatment. The main advantages of this technique for tumour response evaluation are the direct correlation between the measured ADC and tumour cell density, the quantitative nature of the ADC parameter that allows comparison between different centres, the ubiquity and availability of MR scans and the non-invasive nature of the procedure, not requiring contrast agent. Geometrical distortion, as can be observed in Fig. 3 and noisy images due to movement artefacts are the main disadvantages. Work



**Fig. 2** – Two patient of ARTFIBio project were monitored during treatment. In this figure, the increment in the average ADC of different target volumes (5 nodes and 2 primary tumours) during treatment in the low distorted region is shown.



**Fig. 3** – Distorted ADC map overlapping computed tomography in sagittal view from ARTFIBio project. Crosses indicate analyzed slices in Fig. 2.

is in progress to reduce geometrical distortion by using different diffusion weighted techniques, as DW-EPI<sup>68</sup> (diffusion weighted-echo planar imaging) or by using deformable registration methods (Fig. 3).

## 2.2. BOLD MRI

Contrast in BOLD techniques is due to the changes in the paramagnetic momentum between oxyhemoglobine and deoxyhemoglobine.<sup>69</sup> An increased rate of metabolic oxygen consumption generates an increase of concentration of deoxyhemoglobin (common in tumours and cerebral activity). This non-invasive technique allows the *in vivo* measurement of oxygenation distribution, not only previously the treatment, but also the evolution along the treatment, with no need of contrast agent. Information losses can be produced because movement artefacts.

## 2.3. DCE MRI

Dynamic contrast enhance MRI has been proposed for several authors for treatment monitoring<sup>70</sup> and for measurement of oxygenation distribution.<sup>71</sup> The main problem is the complexity of the data analysis and the correspondence between measurement and biological parameters. Another disadvantage is the necessity of contrast agent.

## 2.4. Conclusions

The combined information from different imaging modalities can improve radiotherapy treatment, not only through better target volume delineation, but also adapting treatment to real tumour dynamics during the treatment. ADC maps can be used not only for treatment planning, but also for quantification of tumour response voxel by voxel. The main weakness of this method is registration of the highly distorted images from DWMRI and great efforts are being carried out by scientific community to overcome this problem. Even more, the joint use of MRI diffusion data, DCEMRI and PET/CT can be useful for delimiting the tumour hypoxic areas. Variation of the hypoxic areas can be monitorized also during treatment by DCEMRI. Treatment response monitorization by functional imaging might be the way to implement biological adaptive radiotherapy.

## Conflict of interest

Authors certify that there is no conflict of interest with any financial organization regarding the material discussed in the manuscript.

## Financial disclosure

The authors are reporting that we have not a financial and/or business interests in a company that may be affected by the content reported in the enclosed paper.

## Acknowledgement

This work has been partially supported by ISCIII Grant PI11/02035.

## REFERENCES

1. MacManus M, Nestle U, Rosenzweig KE, et al. Use of PET and PET/CT for radiation therapy planning: IAEA expert report 2006–2007. *Radiother Oncol* 2009;91:85–94.
2. Newbold K, Powell C. PET/CT in radiotherapy planning for head and neck cancer. *Front Oncol* 2012;2:189.
3. Xu GZ, Zhu XD, Li MY. Accuracy of whol-body PET and PET-CT in initial M staging of head and neck cancer: a meta-analysis. *Head Neck* 2011;33:87–94.
4. Lonneux M, Hamoir M, Reychler H, et al. Positron emission tomography with [18F]fluorodeoxyglucose improves staging and patient management in patients with head and neck

- squamous cell carcinoma: a multicenter prospective study. *J Clin Oncol* 2010;**28**:1190–5.
5. Riegel AC, Berson AM, Destian S, et al. Variability of gross tumor volume delineation in head-and-neck cancer using CT and PET/CT fusion. *Int J Radiat Oncol Biol Phys* 2006;**65**:726–32.
  6. Berson AM, Stein NF, Riegel AC, et al. Variability of gross tumor volume delineation in head-and-neck cancer using PET/CT fusion. Part II: the impact of a contouring protocol. *Med Dosim* 2009;**34**:30–5.
  7. Daisne JF, Duprez T, Weynand B, et al. Tumor volume in pharyngolaryngeal squamous cell carcinoma: comparison at CT, MR imaging, and FDG PET and validation with surgical specimen. *Radiology* 2004;**233**:93–100.
  8. Kyzas PA, Evangeloy E, Denaxa-Kyzas D, Ioannidis JP. 18F-fluorodeoxyglucose positron emission tomography to evaluate cervical node metastases in patients with head and neck squamous cell carcinoma: a meta-analysis. *J Natl Cancer Inst* 2008;**100**:712–20.
  9. Kanda T, Kitajima K, Suenaga Y, et al. Value of retrospective image fusion of 18F-FDG PET and MRI for preoperative staging of head and neck cancer: comparison with PET/CT and contrast-enhanced neck MRI. *Eur J Radiol* 2013;**82**(11):2005–10.
  10. Christian N, Lee JA, Bol A, De Bast M, Jordan B, Grégoire V. The limitation of PET imaging for biological adaptive-IMRT assessed in animal models. *Radiother Oncol* 2009;**91**:101–6.
  11. Bussink J, van Herpen CM, Kaanders JH, Oyen WJ. PET-CT for response assessment and treatment adaptation in head and neck cancer. *Lancet Oncol* 2010;**11**:661–9.
  12. Busk M, Horsman MR, Jakobsen S, et al. Can hypoxia-PET map hypoxic cell density heterogeneity accurately in an animal tumor model at a clinically obtainable image contrast? *Radiother Oncol* 2009;**92**:429–36.
  13. Hoeben BA, Bussink J, Troost EG, Oyen WJ, Kaanders JH. Molecular PET imaging for biology-guided adaptive radiotherapy of head and neck cancer. *Acta Oncol* 2013;**52**(7):1257–71.
  14. Hoeben BA, Troost EG, Span PN, et al. 18F-FLT PET during radiotherapy or chemoradiotherapy in head and neck squamous cell carcinoma is an early predictor of outcome. *J Nucl Med* 2013;**54**(4):523–40.
  15. Baek CH, Chung MK, Son YI, et al. Tumor volume assessment by 18F-FDG PET/CT in patients with oral cavity cancer with dental artefacts on CT or MR images. *J Nucl Med* 2008;**49**:1422–8.
  16. Troost EG, Bussink J, Hoffman AL, Boerman OC, Oyen WJ, Kaanders JH. 18F-FLT PET/CT for early response monitoring and dose escalation in oropharyngeal tumors. *J Nucl Med* 2010;**51**:866–74.
  17. Troost EG, Schinagl DA, Bussink J, et al. Innovations in radiotherapy planning of head and neck cancers: role of PET. *J Nucl Med* 2010;**51**:66–76.
  18. Schinagl DA, Vogel WV, Hoffmann AL, van Dalen JA, Oyen WJ, Kaanders JH. Comparison of five segmentation tools for 18F-fluoro-deoxy-glucose-positron emission tomography-based target volume definition in head and neck cancer. *Int J Radiat Oncol Biol Phys* 2007;**69**:1282–9.
  19. Greco C, Nehmeh SA, Schöder H, et al. Evaluation of different methods of 18F-FDG-PET target volume delineation in the radiotherapy of head and neck cancer. *Am J Clin Oncol* 2008;**31**:439–45.
  20. Daisne JF, Sibomana M, Bol A, Doumont T, Lonnet M, Grégoire V. Tridimensional automatic segmentation of PET volumes based on measured source-to-background ratios: influence of reconstruction algorithms. *Radiother Oncol* 2003;**69**:247–50.
  21. Murphy JD, Chisholm KM, Daly ME, et al. Correlation between metabolic tumor volume and pathologic tumor volume in squamous cell carcinoma of the oral cavity. *Radiother Oncol* 2011;**101**:356–61.
  22. van Dalen JA, Hoffmann AL, Dicken V, et al. A novel iterative method for lesion delineation and volumetric quantification with FDG PET. *Nucl Med Commun* 2007;**28**(6).
  23. Hatt M, Cheze le Rest C, Turzo A, Roux C, Visvikis D. A fuzzy locally adaptive Bayesian segmentation approach for volume determination in PET. *IEEE Trans Med Imaging* 2009;**28**(6):881–93.
  24. Knäusel B, Hirti A, Dobrozemsky G, et al. PET based volume segmentation with emphasis on the iterative TrueX algorithm. *Z Med Phys* 2012;**22**(1):29–39.
  25. Grégoire V, Haustermans K, Geets X, Roels X, Lonnet M. PET-based treatment planning in radiotherapy: a new standard? *J Nucl Med* 2007;**48**:685–775.
  26. Chu HR, Kim JH, Yoon DY, Hwang HS, Rho Y. Additional diagnostic value of (18)F-FDG PET-CT in detecting retropharyngeal nodal metastases. *Otolaryngol Head Neck Surg* 2009;**141**:633–8.
  27. Ozer E, Naiboglu B, Meacham R, Ryoo C, Agrawal A, Schuller DE. The value of PET/CT to assess clinically negative necks. *Eur Arch Otorhinolaryngol* 2012;**269**:2411–4.
  28. Schöder H, Carlson KL, Kraus DH, et al. 18F-FDG PET/CT for detecting nodal metastases in patients with oral cancer staged N0 by clinical examination and CT/MRI. *J Nucl Med* 2006;**47**:755–62.
  29. Schinagl DA, Hoffman AL, Vogel WV, et al. Can FDG-PET assist in radiotherapy target volume definition of metastatic lymph nodes in head-and-neck cancer? *Radiother Oncol* 2009;**91**(1):95–100.
  30. AAPM Task Group 166. *The use and QA of biologically related models for treatment planning*. AAPM; 2012. Report of AAPM Task Group 166.
  31. Dirscherl T, Rickhey M, Bogner L. Feasibility of TCP-based dose painting by numbers applied to a prostate case with 18F-choline PET imaging. *Z Med Phys* 2012;**22**(1):48–57.
  32. Madani I, Duthoy W, Derie C, et al. Positron emission tomography-guided focal dose escalation using intensity modulated radiotherapy for head and neck cancer. *Int J Radiat Oncol Biol Phys* 2007;**68**:126–35.
  33. Rajendran JG, Hendrickson KR, Spence AM, Muzi M, Krohn K, Mankoff DA. Hypoxia imaging-directed radiation treatment planning. *Eur J Nucl Med Mol Imaging* 2006;**33**(S1):44–53.
  34. Lee NY, Machalagos JG, Nehmeh S, et al. Fluorine-18-labeled fluoromisonidazole positron emission and computed tomography-guided intensity-modulated radiotherapy for head and neck cancer: a feasibility study. *Int J Radiat Oncol Biol Phys* 2008;**70**:2–13.
  35. Nehmeh SA, Lee NY, Schröder H, et al. Reproducibility of intratumor distribution of (18)F-fluoromisonidazole in head and neck cancer. *Int J Radiat Oncol Biol Phys* 2008;**70**:235–42.
  36. Bentzen SM, Grégoire V. Molecular imaging-based dose painting: a novel paradigm for radiation therapy prescription. *Semin Radiat Oncol* 2011;**21**:101–10.
  37. Madani I, Duprez F, Botterbert T, et al. Maximum tolerated dose in a phase I trial on adaptive dose painting by numbers for head and neck cancer. *Radiother Oncol* 2011;**101**:351–5.
  38. Duprez F, De Neve W, De Gerssem W, Coghe M, Madani I. Adaptive dose painting by numbers for head-and-neck cancer. *Int J Radiat Oncol Biol Phys* 2011;**80**:1045–55.
  39. Thorwarth D, Eschmann SM, Paulsen F, Alber M. Hypoxia dose painting by numbers: a planning study. *Int J Radiat Oncol Biol Phys* 2007;**68**:291–300.
  40. Berwouts D, Olteanu LA, Duprez F, et al. Three-phase adaptive dose-painting-by-numbers for head-and-neck cancer: initial results of the phase I clinical trial. *Radiother Oncol* 2013;**107**(3):310–6.

41. Geets X, Lee JA, Bol A, Lonneux M, Grégoire V. A gradient-based method for segmenting FDG-PET images: methodology and validation. *Eur J Nucl Med Mol Imaging* 2007;**34**:1427–38.
42. Scott AM, Gunawardana DH, Bartholomeusz D, Ramshaw JE, Lin P. PET changes management and improves prognostic stratification in patients with head and neck cancer: results of a multicenter prospective study. *J Nucl Med* 2008;**49**:1593–600.
43. Inokuchi H, Kodaira T, Tachibana H, et al. Clinical usefulness of [18F]fluoro-2-deoxy-d-glucose uptake in 178 head-and-neck cancer patients with nodal metastasis treated with definitive chemoradiotherapy: consideration of its prognostic value and ability to provide guidance for optimal selection. *Int J Radiat Oncol Biol Phys* 2011;**79**:747–55.
44. Higgins KA, Hoang JK, Roach MC, et al. Analysis of pre-treatment FDG-PET SUV parameters in head-and-neck cancer: tumor SUV(mean) has superior prognostic value. *Int J Radiat Oncol Biol Phys* 2012;**82**:548–53.
45. Liu WS, Wu MF, Tseng HC, et al. The role of pretreatment FDG-PET in nasopharyngeal carcinoma treated with intensity-modulated radiotherapy. *Int J Radiat Oncol Biol Phys* 2012;**82**:561–6.
46. Garg MK, Glanzman J, Kalnicki S. The evolving role of positron emission tomography-computed tomography in organ-preserving treatment of head and neck cancer. *Semin Nucl Med* 2012;**42**:320–7.
47. Xie P, Yue JB, Fu Z, Feng R, Yu JM. Prognostic value of 18F-FDG PET/CT before and after radiotherapy for locally advanced nasopharyngeal carcinoma. *Ann Oncol* 2010;**21**:1078–82.
48. Torizuka T, Tanizaki Y, Kanno T, et al. Prognostic value of 18F-FDG PET in patients with head and neck squamous cell cancer. *Am J Roentgenol* 2009;**192**:W156–60.
49. Machtay M, Natwa M, Andrel J, et al. Pretreatment FDG-PET standardized uptake value as a prognostic factor for outcome in head and neck cancer. *Head Neck* 2009;**31**:195–201.
50. Yao M, Smith RB, Graham MM, et al. The role of FDGPET in management of neck metastasis from head-and-neck cancer after definitive radiation treatment. *Int J Radiat Oncol Biol Phys* 2005;**63**:991–9.
51. Krabbe CA, Pruim J, Dijkstra PU, et al. 18F-FDGPET as a routine post treatment surveillance tool in oral and oropharyngeal squamous cell carcinoma: a prospective study. *J Nucl Med* 2009;**50**:1940–7.
52. Gupta T, Jain S, Agarwal JP, et al. Diagnostic performance of response assessment FDG-PET/CT in patients with head and neck squamous cell carcinoma treated with high-precision definitive (chemo)radiation. *Radiother Oncol* 2010;**97**:194–9.
53. Moeller BJ, Rana V, Cannon BA, et al. Prospective imaging assessment of mortality risk after head-and-neck radiotherapy. *Int J Radiat Oncol Biol Phys* 2010;**78**:667–74.
54. Ceulemans G, Voordechers M, Farrag A, Verdries D, Storme G, Everaert H. Can 18-FDG-PET during radiotherapy replace post-therapy scanning for detection/demonstration of tumor response in head-and-neck cancer? *Int J Radiat Oncol Biol Phys* 2011;**81**:938–42.
55. Eschmann SM, Paulsen F, Reimold M, et al. Prognostic impact of hypoxia imaging with 18F-misonidazolePET in non-small cell lung cancer and head and neck cancer before radiotherapy. *J Nucl Med* 2005;**46**:253–60.
56. Rischin D, Hicks RJ, Fisher R, et al. Prognostic significance of [18F]-misonidazole positron emission tomography detected tumor hypoxia in patients with advanced head and neck cancer randomly assigned to chemoradiation with or without tirapazamine: a substudy of T-TROG study 98.02. *J Clin Oncol* 2006;**24**:2098–104.
57. Boellaard R, O'Doherty MJ, Weber WA, et al. FDGPET and PET/CT: EANM procedure guidelines for tumour PET imaging: version 1.0. *Eur J Nucl Med Mol Imaging* 2010;**37**:181–200.
58. Gregoire V, Chiti A. PET in radiotherapy planning. *Radiother Oncol* 2010;**96**:275–356.
59. Caballero B, Cabrera A, Delgado JM, et al. Recommendations of the Spanish Societies of Radiation Oncology (SEOR), Nuclear Medicine & Molecular Imaging (SEMNI), and Medical Physics (SEFM) on 18F-FDG PET-CT for radiotherapy treatment planning. *Reports Pract Oncol Radiother* 2012;**17**:298–318.
60. Khoo VS, Joon DL. New developments in MRI for target volume delineation in radiotherapy. *Br J Radiol* 2006;**79**:S2–15.
61. Kim S, Loevner L, Quon H, et al. Diffusion-weighted magnetic resonance imaging for predicting and detecting early response to chemoradiation therapy of squamous cell carcinomas of the head and neck. *Clin Cancer Res* 2009;**15**:986–94.
62. Vandecaveye V, De Keyser F, Nuyts S, et al. Detection of head and neck squamous cell carcinoma with diffusion weighted MRI after (chemo)radiotherapy: correlation between radiologic and histopathologic findings. *Int J Radiat Oncol Biol Phys* 2007;**67**:960–71.
63. Koh DM, Collins DJ. Diffusion weighted MRI in the body: applications and challenges in oncology. *Am J Roentgenol* 2007;**188**:1622–35.
64. Yankeelov TE, Lepage M, Chakravarthy A, et al. Integration of quantitative DCE-MRI and ADC mapping to monitor treatment response in human breast cancer: initial results. *Magn Reson Imaging* 2007;**25**:1–13.
65. López Medina A, Aramburu D, Mera M, et al. ARTFIBio Project: quantifying tumour response voxel by voxel. *Second ESTRO Forum Book of Abstracts*. Geneva: Elsevier; 2013. p. S329.
66. Raaymakers BW, Lagendijk JJ, Overweg J, et al. Integrating a 1.5 T MRI scanner with a 6 MV accelerator: proof of concept. *Phys Med Biol* 2009;**54**:N229–37.
67. Stejskal EO, Tanner JE. Spin diffusion measurements: spin echoes in the presence of a time dependent field gradient. *J Chem Phys* 1965;**42**:288–92.
68. Schakel T, Terhaard CHJ, Hoogduin JM, Philippens MEP. SPLICE, a method to overcome geometric distortions in diffusion weighted imaging in head-and-neck cancer. *Radiother Oncol* 2013;**106**:S21. Abstract.
69. Norris DG. The effects of microscopic tissue parameters on the diffusion weighted magnetic resonance imaging experiment. *NMR Biomed* 2001;**14**:77–93.
70. Kallehauge JF, Nomden C, Arteaga de Castro CS, et al. Temporal changes in DCE-MRI parameters during treatment of locally advanced cervical cancer. *Radiother Oncol* 2012;**103**:S78.
71. Elliot JT, Wright EA, Tichauer KM, et al. Arterial input function of an optical tracer for dynamic contrast enhanced imaging can be determined from pulse oximetry oxygen saturation measurements. *Phys Med Biol* 2012;**57**:8285–95.