

Available online at [www.sciencedirect.com](http://www.sciencedirect.com)

SciVerse ScienceDirect

journal homepage: <http://www.elsevier.com/locate/rpor>

## Case report

# Nasopharyngeal mucoepidermoid carcinoma: A case report and review of literature

Javier Martínez Ollero\*, Asunción Hervás Morón, Ángel Montero Luis, Soraya Marcos Sánchez, Andrea Abondano Nazarewsky, M<sup>a</sup> José Salgueiro López, Alfredo Ramos Aguerri

Radiation Oncology Department, Ramón y Cajal University Hospital, Ctra. Colmenar Viejo, Km 9,100, C.P. 28049 Madrid, Spain

## ARTICLE INFO

## Article history:

Received 19 April 2012

Received in revised form

16 August 2012

Accepted 19 October 2012

## Keywords:

Mucoepidermoid carcinoma

Nasopharynx

Salivary gland tumor

Radiotherapy

MEC

Chemotherapy

## ABSTRACT

**Background:** Salivary gland-type tumors originating in the nasopharynx are rare, and only a few articles about mucoepidermoid carcinomas (MEC) in this location have been reported. We describe one case of nasopharyngeal MEC and, based on a review of the literature, discuss different therapeutic approaches that can be taken regarding the result of histological findings, radiological tests and extent of disease.

**Case presentation:** A 47-year-old woman diagnosed with mucoepidermoid carcinoma of nasopharynx, T1 N3 M0 (stage IV-B) was treated in 2007 with a combination of radiotherapy and chemotherapy to a maximum dose of 70 Gy and concomitant Cisplatin during the radiation. One year later, with the head and neck disease under control, mediastinal nodes relapse appeared which were treated with exclusive radiotherapy to a maximum dose of 65 Gy. One year after the first relapse, a second relapse was detected in the right lung, next to the previously treated mediastinal regions, and the patient initiated a treatment with exclusive chemotherapy based on TPF scheme.

**Conclusion:** For limited or resectable MEC, combined surgery with radiotherapy, or radiochemotherapy, should be considered the main treatment policy. On the other hand, in poorly differentiated, unresectable tumors or nasopharyngeal MEC, radiochemotherapy could be currently the main treatment approach.

© 2012 Greater Poland Cancer Centre. Published by Elsevier Urban & Partner Sp. z o.o. All rights reserved.

## 1. Background

Mucoepidermoid carcinoma (MEC) is a common malignancy in the salivary glands, especially, in the major salivary glands and intra-oral minor salivary glands.<sup>1</sup> MEC has been less

frequently reported to arise from other sites, including the lung, nasal cavity, paranasal sinuses and nasopharynx.

Salivary gland-type tumors of nasopharynx have been scarcely reported in the literature.<sup>1–3</sup> The etiopathogenesis, treatment and prognosis of salivary gland-type malignant tumors are still uncertain. We describe one case of

\* Corresponding author. Tel.: +34 913368222/8226; fax: +34 913368202.

E-mail addresses: [javierollero@hotmail.com](mailto:javierollero@hotmail.com) (J.M. Ollero), [ahervas.hrc@salud.madrid.org](mailto:ahervas.hrc@salud.madrid.org) (A.H. Morón), [angel.monteroluis@gmail.com](mailto:angel.monteroluis@gmail.com) (Á.M. Luis), [soraya8183@hotmail.com](mailto:soraya8183@hotmail.com) (S.M. Sánchez), [andrea.abondano.n@gmail.com](mailto:andrea.abondano.n@gmail.com) (A.A. Nazarewsky), [mariajosesalgueiro@gmail.com](mailto:mariajosesalgueiro@gmail.com) (M.J.S. López), [ramosaguerri@gmail.com](mailto:ramosaguerri@gmail.com) (A.R. Aguerri).

1507-1367/\$ – see front matter © 2012 Greater Poland Cancer Centre. Published by Elsevier Urban & Partner Sp. z o.o. All rights reserved.

<http://dx.doi.org/10.1016/j.rpor.2012.10.002>

nasopharyngeal MEC and, based on a review of the literature, discuss different therapeutic approaches that can be taken regarding the result of histological findings, radiological tests and extent of disease.

## 2. Case presentation

A 47-year-old woman with a 40-pack per year history of smoking tobacco and occasional alcohol consumption presented with bilateral lymph neck nodes, odynophagia and left neck pain. Her past medical history was only significant for a previous episode of infectious mononucleosis twenty-five years ago. She had no other medical history of note.

Physical examination revealed the presence of palpable bulky adenopathies in the left neck encompassing levels II-V, and levels II-III on the right neck. A CT-scan confirmed the presence of bilateral cervical lymph nodes along with asymmetry in the left cavum. Magnetic-resonance imaging revealed an anomalous enhancement in the left cavum suggesting a neoplastic growth. The PET-CT evidenced an increasing uptake of 18F-FDG in the left nasopharynx and cervical lymph nodes (see Fig. 1).

The biopsy of the nasopharynx and cervical lymph nodes evidenced the presence of multiple nests of cells forming ducts with eosinophilic material inside and the expression of low molecular weight cytokeratins detected by immunohistochemistry. All findings were consistent with a high grade MEC.

A final diagnosis of mucoepidermoid carcinoma of the cavum was established, cT1cN3M0 stage IVB according to the AJCC 7th edition.<sup>4</sup>

The case was evaluated in the head and neck tumors multidisciplinary recommending treatment with concomitant radiochemotherapy. The patient underwent radiotherapy with conventional 2 Gy/day fractionation up to a total dose of 50 Gy to the bilateral uninvolved II-V neck levels and retropharyngeal area. Palpable adenopathies less than 3 cm in diameter

were boosted up to 60 Gy. Finally, the gross tumor located on nasopharynx and lymph nodes greater than 3 cm in diameter received a total dose of 70 Gy with identical fractionation. Together with the radiation therapy, the patient received 3 courses of cisplatin (CDDP) at a dose of 100 mg/m<sup>2</sup> each 21 days, and 3 additional courses of chemotherapy after completion of simultaneous radiochemotherapy based upon the Al-Sarraf regimen with CDDP (100 mg/m<sup>2</sup>, day 1) and 5-FU (1 g/m<sup>2</sup>, days 1-5) each 21 days.<sup>5</sup>

A 18F-FDG-PET/CT performed 3 months after treatment did not reveal any increase of metabolism, nor of nasopharynx or lymphatic cervical levels. Only a slight focal increased tracer uptake was detected in mediastinal and right lung hilum nodes without being able to distinguish between tumor tissue and infectious process.

Four month later, a repeated 18F-FDG-PET/CT confirmed an increase of tracer uptake in the previous hilum and precaval lymphadenopathies without other significant data in the rest of the examination (see Fig. 2). With the suspicion of tumor relapse, a CT guided FNA biopsy of the nodes was considered but the patient declined this approach. The case was discussed in the head and neck tumors multidisciplinary committee recommending that the images were assumed as viable tumor and a salvage treatment was proposed. The patient underwent radiotherapy to the mediastinal and hilum areas up to a total dose of 50.4 Gy (1.8 Gy/fraction/day). Significant lymphadenopathies by 18F-FDG-PET/CT were boosted a final dose of 65 Gy (1.8 Gy/fraction/day). Concomitant chemotherapy with CDDP was rejected because of the progression of disease with this scheme. Targeted treatment based on Cetuximab or Bevacuzimab was dismissed due to the negative immunohistochemical analysis and PCR sequencing of EGFR and VEGR in the previous sample.

Six months after salvage treatment, a new 18F-FDG-PET/CT showed a good response in the hilum and mediastinal nodes treated, however, pathological images of new

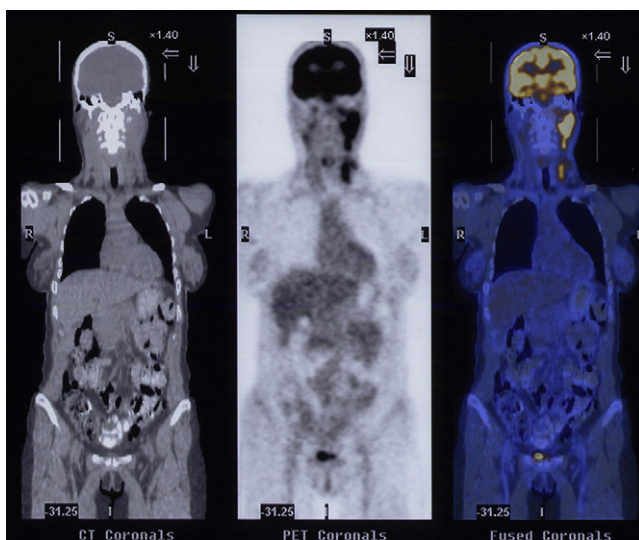


Fig. 1 – Diagnostic PET-CT with an increasing of tracer uptake of 18F-FDG in left nasopharynx and cervical lymph nodes.

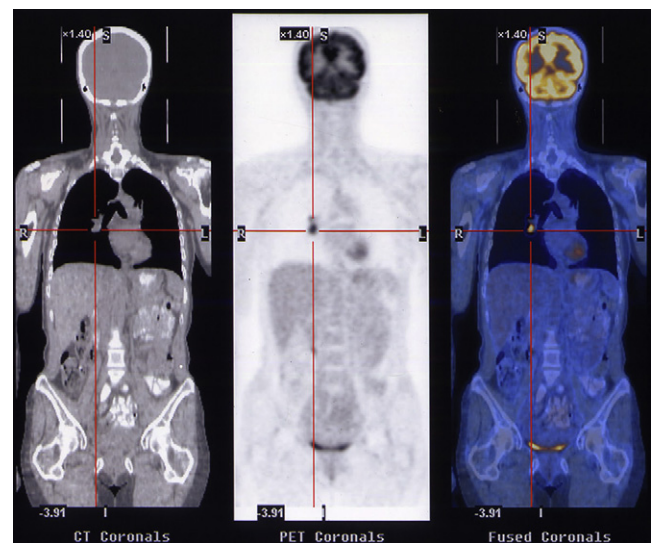
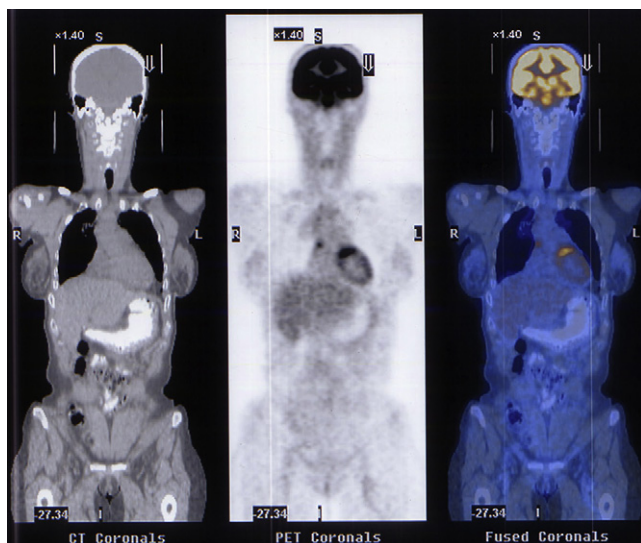


Fig. 2 – 18F-FDG-PET/CT, after 4 months of treatment, with an increased of tracer uptake in the right lung hilum and precaval lymphadenopathies without another significant data in the rest of the examination.



**Fig. 3 – 18F-FDG-PET/CT, after treatment of lung and hilum relapse, with a good response in the treated fields.**

lymphadenopathies in other mediastinal localizations were detected together with a suspicious image in lung parenchyma (see Fig. 3). A fibrobronchoscopy evidenced an occlusive bronchial mass, with biopsy of highly undifferentiated carcinoma cells unable to rule out that it was a metastasis of the initial mucoepidermoid carcinoma of the nasopharynx due to the high indifferenciation of the cells in the sample. A FNA biopsy of the transcarinal lymphadenopathies also showed carcinoma cells in the histological analysis. The patient was considered inoperable undergoing systemic chemotherapy with a paclitaxel, cisplatin and 5-FU without response. The patient died because of metastatic tumor progression 4 years after initial diagnosis.

### 3. Discussion

Mucoepidermoid carcinoma was first described by Stewart et al. in 1945<sup>6</sup> as a rare malignancy that arises in the major and minor salivary glands of the head and neck. MEC represents approximately one third of all carcinomas developing in these regions,<sup>7</sup> being the most common carcinoma in the parotid gland.<sup>8</sup>

Nasopharyngeal MEC comprising less than 15% of all nasopharyngeal salivary gland malignancies, that is, approximately 3% of all nasopharyngeal carcinomas.<sup>9</sup> Because of this, there are few articles that report only nasopharyngeal MEC and a few more that join nasopharyngeal MEC with other head and neck MECs or with other nasopharyngeal salivary gland malignancies.

MEC has a female predominance, with the highest prevalence in the fifth decade of life. As in other tumors, the usual symptoms are related to the location of the primary tumor, its infiltration of the surrounding structures, and the presence of cervical lymph nodes and distant metastases. Nasal bleeding and obstruction, headache, facial numbness, tinnitus or hearing loss, deafness and diplopia are the most common presentations.<sup>10</sup> The incidence of nasopharyngeal salivary

gland type malignancy metastasis in the context of MEC is low, less than 20–25% according to some authors.<sup>11</sup>

On the pathology exam, MEC is constituted by acinic cell cancer derived from cells of the terminal ducts and intercalated ducts.<sup>7</sup> Histochemical studies have detected that the tumor glands are like nests with positive mucous cells for mucin staining. Immunohistochemically, the lesions are positive for cytokeratins (CKs), p63, and MUC1, but negative for alpha-smooth muscle actin and EBER mRNA.<sup>12</sup> Additionally, the t(11;19)(q21;p13) translocation resulting in MAML2 gene rearrangement has been identified in a majority of MEC regardless of the grade and has been suggested as an additional marker of favorable prognosis, being a potentially useful confirmatory diagnostic test if positive.<sup>13</sup>

The different behavior of MEC compared with nasopharyngeal squamous cell carcinomas reflects the controversies in the mainstay of treatment. The best approach for local MEC is not clear. Surgery and radiotherapy (or concomitant radiochemotherapy) remain as the more contrasted options.<sup>12</sup>

It is unclear if MEC is a radiosensitive or a radioresistant tumor. Different authors have reported their experience with radiotherapy alone obtaining good control rates of the local disease in early stage tumors. However, many of these case series include MEC from different locations so it might be too early to reach the conclusion that nasopharyngeal MEC can be radiosensitive.<sup>11</sup> Based on the reported cases, it appears that poorly differentiated tumors are those that respond better to radiation.

The role of adjunctive radiotherapy after surgery is an approach in this kind of tumors although limited to the location. Post-operative radiotherapy acts as an important complement to the surgery improving the local control rates in patients with positive surgical margins. Because of this, combined surgery with radiotherapy is the main treatment policy for resectable MEC.<sup>14,15</sup>

Technological advances in radiotherapy allow limiting the highest dose to the tumor without affecting surrounding healthy organs. High-dose radiotherapy has been related to better outcomes in many localized tumors, like epidermoid cervix cancer or other squamous head and neck cancers. Together with this, the use of radiosensitizing drugs in combination with radiotherapy, has further increased local control of different tumors. Therefore, radical radiochemotherapy is frequently used in advanced loco-regional disease in head and neck tumors and nasopharyngeal tumors, the latter one being a good example of these improvements. Chemotherapy alone is mainly used for metastatic and advanced recurrent disease in head and neck cancer without result so evident in MEC. Cisplatin-based combination chemotherapy (such as cisplatin and 5-fluorouracil) has become a standard treatment approach for metastatic. Finally, our patient received chemotherapy alone when all the other therapies were depleted.<sup>11</sup>

In the present case, we decided to treat the patient with concomitant radiochemotherapy, considering that the tumor was located in the nasopharynx, where radiochemotherapy is considered the gold-standard treatment by all international cancer guidelines.<sup>16</sup> Moreover, due to the unclear radiosensitivity of the MEC, we tried to increase the radiosensitizing effect with a CDDP based scheme to increase the

radiobiological effect of the radiation therapy. Furthermore, due to the fact that Al-Sarraf scheme was at that time the most contrasted radiochemotherapy treatment in nasopharyngeal carcinomas, we used the whole scheme and added adjuvant chemotherapy to complete the treatment. Finally, this approach resulted in a very good response in the treated areas without radiologic and metabolic relapse post-radiochemotherapy. Also, it is important to note that the two tumor recurrences presented by the patient were in the areas where no radiotherapy, with or without chemotherapy, had been administered previously.

#### 4. Conclusions

For limited or resectable MEC, combined surgery with radiotherapy (or radiochemotherapy) should be considered the treatment of election. On the other hand, in poorly differentiated, unresectable tumors or nasopharyngeal MEC, radiochemotherapy could be currently the main treatment approach.

Because of the low incidence of nasopharyngeal MEC, the number of cases is relatively small for analysis. Prospective multicenter studies are necessary to further evaluate the optimal treatment approaches and the most relevant prognostic factors for these types of carcinomas.

#### Conflict of interest

The authors declare that they have no competing interests.

#### Financial disclosure

None declared.

#### Authors' contributions

All the authors read and approved the final manuscript.

#### REFERENCES

1. Kuo TT, Chan JKC, Wenig BM, Eveson JW. Nasopharyngeal adneocarcinoma and salivary gland-type carcinoma. In: Barnes L, Eveson JW, Reichart P, Sidransky D, editors. *World Health Organization Classification Tumors: pathology & genetics head and neck tumors*. Lyon: WHO Publications Center, Albany, NY, USA, IARC Press; 2005. p. 98.
2. Brown J, Choi EC, Fee Jr WE. Nasopharyngectomy for recurrent high-grade mucoepidermoid carcinoma after radiation failure. *Otolaryngol Head Neck Surg* 1999;120:564-6.
3. Schramm Jr VL, Imora MJ. Management of nasopharyngeal salivary gland malignancy. *Laryngoscope* 2001;111:1533-44.
4. *AJCC cancer staging manual*. 7th ed. New York: Springer-Verlag; 2010.
5. Al-Sarraf M, LeBlanc M, Giri PG, Fu KK, Cooper J, Vuong T, Forastiere AA, Adams G, Sakr WA, Schuller DE, Ensley JF. Chemoradiotherapy versus radiotherapy in patients with advanced nasopharyngeal cancer: phase III randomized Intergroup study 0099. *J Clin Oncol* 1998;16(April (4)):1310-7.
6. Stewart FW, Foote FW, Becker WF. Mucoepidermoid tumors of salivary glands. *Ann Surg* 1945;122:820-44.
7. Cawson RA, Gleeson MJ, Eveson JW. *The pathology and surgery of the salivary glands*. Oxford: ISIS Medical Media; 1997. pp. 117-169.
8. Edward C, Halperin, Carlos A, Perez, Luther W Brady (editors), Perez and Brady's principles and practice of radiation oncology; David E. Wazer, Carolyn Freeman, Leonard R. Prosnitz (associate editors). Philadelphia: Wolters Kluwer Health/Lippincott Williams & Wilkins; 2008.
9. Qiu F, Hua YJ, Guo L. Mucoepidermoid carcinoma of nasopharynx: a report of twelve cases. *Chin J Cancer* 2005;24:362-4.
10. Zhang Xi-mei, Cao Jian-zhong, Luo Jing-wei, Xu Guo-zhen, Gao Li, Liu Shao-yan, Xu Zhen-gang, Tang Ping-zhang. Nasopharyngeal mucoepidermoid carcinoma: a review of 13 cases. *Oral Oncol* 2010;46:618-21.
11. Liu Tian-Run, Chen Fu-Jin, Zhang Guan-Ping, Yang An-Kui. Different therapeutic strategies in primary salivary gland-type nasopharyngeal carcinomas. *Curr Opin Otolaryngol Head Neck Surg* 2011;19:87-91.
12. Kusafuka K, Takizawa Y, Iida Y, Ebihara M, Onitsuka T, Kameya T. Primary nasopharyngeal mucoepidermoid carcinoma in Japanese patients: two case reports with histochemical and immunohistochemical analysis and a review of the literature. *Virchows Arch* 2007;450:343-8.
13. Griffith Christopher C, Seethala Raja R. *Mucoepidermoid carcinoma of minor salivary glands: potential pitfalls and prognostic challenges*. Pittsburgh: Lippincott Williams & Wilkins, Inc.; 2011. Abstract.
14. Liu TR, Chen FJ, Qian CN, et al. Primary salivary gland type carcinoma of the nasopharynx: therapeutic outcomes and prognostic factors. *Head Neck* 2010;32:435-44.
15. Leung TW, Tung SY, Sze WK, et al. Treatment results of 1070 patients with nasopharyngeal carcinoma: an analysis of survival and failure patterns. *Head Neck* 2005;27:555-65.
16. Pfister David G, Ang Kie-Kian, Brizel David, et al. Cancer of the nasopharynx. *NCCN Pract Guidel Oncol* 2011;V2.