


Available online at www.sciencedirect.com

SciVerse ScienceDirect

journal homepage: <http://www.elsevier.com/locate/rpor>

Original research article

Intraoperative radiation therapy as part of breast conserving therapy of early breast cancer—Results of one-year follow-up

Żaneta Wareńczak-Florczak^{a,*}, Andrzej Roszak^{a,b,d}, Krystyna Bratos^{a,e},
Piotr Milecki^{b,c,f}, Aldona Karczewska-Dzionk^{c,f}, Hanna Włodarczyk^{a,e}

^a Greater Poland Cancer Centre, Department of Gynaecological Radiotherapy and Oncology, Garbary Street 15, 61-866 Poznan, Poland

^b Karol Marcinkowski University of Medical Sciences, Department of Electroradiology, Garbary Street 15, 61-866 Poznan, Poland

^c Greater Poland Cancer Centre, Department of Radiation Oncology, Garbary Street 15, 61-866 Poznan, Poland

ARTICLE INFO

Article history:

Received 14 April 2012

Received in revised form

13 August 2012

Accepted 31 October 2012

Keywords:

Intraoperative therapy

Breast conserving therapy

Cosmetic effect

Side effects

ABSTRACT

Aim: The aim of this study was to assess the therapeutic effect of intraoperative radiotherapy, describe the method, and examine the occurrence of side effects and quality of life.

Background: Breast conserving therapy has recently become a standard treatment modality in patients with early invasive cancer. Radiotherapy, along with surgery, is an integral part of such treatment. The important thing of radiotherapy is to deliver a high dose to the tumour bed. One of the methods is the intraoperative radiotherapy.

Materials and methods: The analysis comprised sixty Tis-T2N0-1A breast cancer patients treated with breast conserving surgery. Patients' mean age was 57 years (range: 32–73 years). Intraoperative radiation therapy was delivered in the operating theatre during surgery and involved a single dose of 10 Gy with an electron beam of 4, 6, 9 or 12 MeV. After that, all patients were treated with whole breast irradiation. During one year observation photos and side effects examination were made.

Results: Physical and imaging examinations performed during a one-year follow-up revealed no local or distant relapse and good tolerance of IORT. Acute mild responses to the radiotherapy occurred in 23.3% of patients. Based on the examination, a good and very good cosmetic effect was found in 78.3%, with 83.3% of patients evaluating their treatment effects in the same way.

Conclusions: Due to its exceptional physical and radiobiological properties, intraoperative radiation therapy can be a good alternative to other methods of boosting dose to the post-operative site in management of low stage breast cancer, enabling a precise therapy to the tumour bed.

© 2013 Published by Elsevier Urban & Partner Sp. z o.o. on behalf of Greater Poland Cancer Centre.

* Corresponding author. Tel.: +48 618850589; fax: +48 618850534.

E-mail addresses: zflorczak@poczta.onet.pl (Żaneta Wareńczak-Florczak), andrzej.roszak@wco.pl (A. Roszak), krystyna.bratos@wco.pl (K. Bratos), piotr.milecki@wco.pl (P. Milecki), aldona.karczewska@wco.pl (A. Karczewska-Dzionk), hanna.w@op.pl (H. Włodarczyk).

^d Tel.: +48 618850587; fax: +48 618850534.

^e Tel.: +48 618850589; fax: +48 618850534.

^f Tel.: +48 618850867.

1. Background

Breast cancer is the most prevalent cancer among women in the world and the most frequent cause of cancer deaths. Breast conserving therapy has recently become a standard treatment modality in patients with early invasive breast cancer. Radiation therapy, along with surgery, is an integral part of such treatment. Radiotherapy delivered to the whole breast remains to be a standard procedure in adjuvant treatment in breast cancer patients after breast-conserving surgery. Many studies have confirmed its efficacy in reducing both the risk of local relapse and breast cancer mortality.¹ Radiotherapy is aimed not only to cover the whole breast with a prescribed dose, but also to increase irradiation dose to the site of tumour removal, known as boost. The benefits of delivering an additional dose to a tumour site have been confirmed by the EORTC study.² There are many methods of delivering a high dose to the post-operative site: brachytherapy, external beam radiotherapy (electron or photon) and intraoperative radiotherapy.³ Intra Operative Radiation Therapy (IORT) enables a delivery of a single dose directly to the post-operative site in the course of a surgical procedure. The application of IORT allows to avoid a geographical error, enabling a delivery of a single dose to the target volume.

2. Aim

The aim of this study was to assess the therapeutic effect of intraoperative radiation therapy, describe the treatment method, and examine the occurrence of early and late reactions to radiation and quality of life, including the cosmetic effect, in women treated conservatively for low-stage breast cancer.

3. Materials and methods

The analysis comprised sixty Tis-T2N0-1A breast cancer patients treated with breast conserving surgery at the Greater Poland Cancer Centre in the period 2008–2009. Patients' mean age was 57 years (range: 32–73 years). The characteristics of the patients in terms of disease stage and histopathological evaluation are shown in Tables 1 and 2.

14 patients (23.3%) were managed with post-operative chemotherapy due to the presence of adverse predictors in post-operative specimens. Hormonal therapy was also given to 54 patients (93.3%) due to the presence of oestrogen and progesterone receptors in the tumours.

Intraoperative radiation therapy was delivered in the operating theatre during a breast conserving surgery. In the first

Table 1 – Sample characteristics.

Tumour size-T feature	No. of patients	No. of patients with N+ (N1a)
Tis	3	0
T1b	21	2
T1c	33	6
T2	3	1

Table 2 – Tumour histopathology.

Tumour histopathology (tumour type)	No. of patients
Ductal carcinoma	49
Labular carcinoma	4
Mucinous carcinoma	4
Papillary carcinoma	2
Tubular carcinoma	2

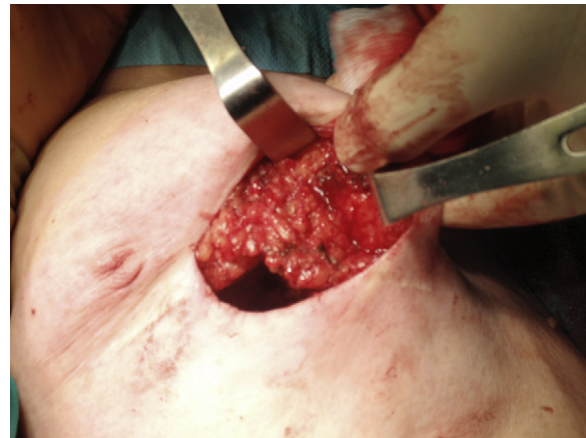

Fig. 1 – Preparation of the tumour bed.

phase, the surgeon excised a lesion with a margin of healthy tissues. The histopathologist evaluated the excised tumour by intraoperative examination and determined clear margins. In the next stage, some breast tissue was dissected from the fascia of the pectoralis major muscle along a 4–5 cm section for an aluminium-lead plate (thickness 0.5–1.0 cm, diameter 5–10 cm) to be placed there as protection for the organs at risk (lung, heart, pectoral muscle) – see Figs. 1 and 2. Mobilised breast tissue of the post-operative site was brought together over the plate. Depending on the size of the tumour and healthy tissue margin, a diameter of an applicator was selected for irradiation to cover the excision site with a 2 cm margin. With the mammary gland separated from the subcutaneous tissue, the skin could be drawn away from the

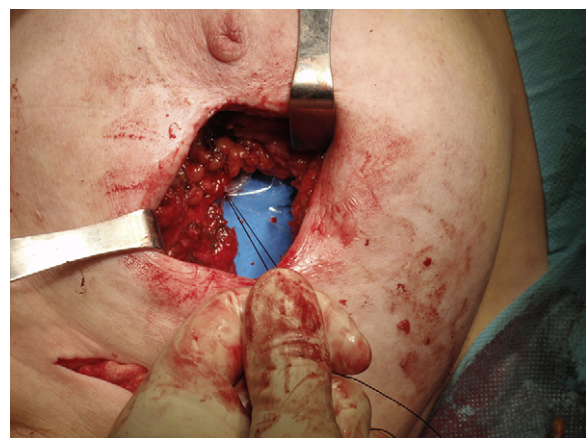


Fig. 2 – View of the aluminium-lead plate under the tissues of the tumour bed.

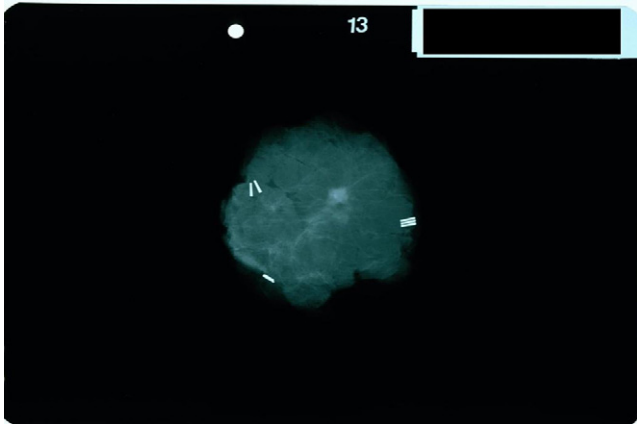


Fig. 3 – Tumour with the clips under the mammograph.

irradiated volume by being placed outside the applicator, thus avoiding the risk of its being irradiated.

In the case of clinically impalpable lesions, a radiomarker – i.e. a technetium isotope emitting low-energy gamma radiation used for marking albumin macroaggregates (Masoll) which acted as a carrier – was inserted into the tumour area under ultrasound guidance one day before the procedure. Then, in the course of surgery, the location of the tumour was determined using a scintillation counter and the tumour removed along with a margin of healthy tissue. After delineating the specimen with wires and clips, it was subjected to radiological assessment in order to locate the tumour and set margins (see Fig. 3), then, submitted for intraoperative histopathological examination.⁴

Following European recommendations, intraoperative sentinel biopsy was performed whenever clinically non-enlarged axillary lymph nodes were found. The procedure involved a radiomarker – i.e. technetium isotope emitting low-energy gamma radiation used for marking the albumin nanocolloids (Nanocoll) which acted as a carrier – inserted into the areolar area before the surgery. Then, the area with the highest irradiation was marked on the skin of the axilla by means of lymphoscintigraphy. An incision was made and a specimen of the lymph node collected for intraoperative examination at the site where the highest irradiation was detected using a manual scintillation counter. The node showing the highest radioactivity was identified to be a sentinel node. After removing the sentinel node, the excision site was checked for further possible radioactive nodes using a manual gamma radiation detector (the radioactive capture was recognised as negative for sentinel node capture <10%). If the result of the intraoperative test was negative, the procedure was terminated after sewing up the surgical wound. If the result of the intraoperative test was positive and metastases found in the sentinel node, axillary lymphadenectomy was performed.^{5,6}

At the Greater Poland Cancer Centre, intraoperative radiation therapy is performed with a Mobetron linear accelerator generating megavolt electron radiation. The application of electron beam ensures high homogeneity of dose distribution in the target volume. The planning and radiation processes

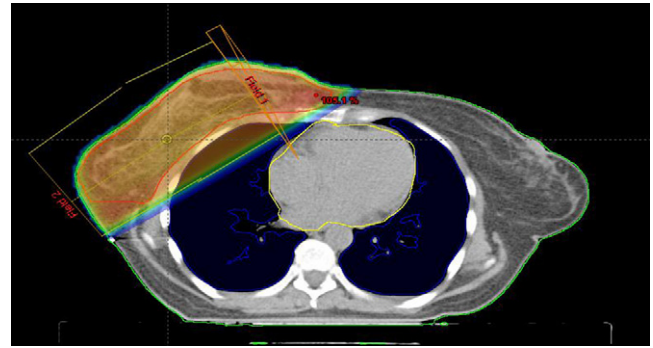


Fig. 4 – Two fields technique in the whole breast teleradiotherapy.

are conducted in the operating theatre in the course of surgery, after defining a target volume and placing applicators/collimators into the postoperative wound. Owing to that, a geographic error in locating a tumour bed can be avoided and radiotherapy correctly delivered to the patient.

Intraoperative radiation therapy at the Centre involved a single dose of 10 Gy with an electron beam of 4, 6, 9 or 12 MeV (66.7% of patients were treated with 6 MeV). Dose was specified to the reference isodose volume representing 95% of the prescribed dose. A collimator of 4–6 cm in diameter was used at an angle of 0–30° to deliver a right dose of radiation to a specific volume of the post-operative site. In 43.3% of patients (26), a bolus of 0.5–1 cm was used to obtain a desired dose distribution in the target volume. The mean depth of irradiated tissue was 1.97 cm.

After completing the surgical and radiotherapeutic procedures and having received a final histopathological results, the interdisciplinary team for breast cancer patients decided on further treatment. If so indicated by histopathological results, patients were given chemotherapy within the first stage following surgery with IORT, then whole breast radiation. If oestrogen and progesterone receptors were found, patients were given hormonal treatment with 20 mg of Tamoxifen as the first choice drug administered once per day.

All patients who underwent surgery with IORT were then treated with teleradiotherapy. Clinical Target Volume (CTV) comprised the whole mammary gland. Radiation was done using two adjacent beams with energy of 6 MeV generated in a Clinac linear accelerator in 25 fractions to a total dose of 50 Gy (Fig. 4).

In the next stage, within a follow-up of at least one year of the surgery with IORT and in the 1st, 6th and 12th months after teleradiotherapy, clinical examinations were made and patients' breasts photographed. Early and late responses were analysed using the RTOG/EORTC scale. The patients were also asked at every visit to complete a quality of life questionnaire (QLQ-C30) and a breast cancer questionnaire including questions on the cosmetic effect (QLQ-BR23), as recommended by RTOG/EORTC. Six months after teleradiotherapy, each patient was given a mammography and ultrasound examination of the breast, then mammography control was repeated every 12 months.

4. Results

Physical and imaging examinations performed during a one-year follow-up revealed no local or distant relapse. Intraoperative radiation therapy was well tolerated. None of the patients showed any radiation-induced reaction in the skin immediately after IORT. Five patients developed postoperative haematoma that required surgical drainage. No grade 3 and 4, early or late responses to whole-breast radiation therapy (WBRT) were observed. Acute grade 1 and 2 responses to WBRT in the skin occurred in 23.3% patients. The evaluation of the cosmetic effect 12 months after teleradiotherapy was each time performed by two radiation therapists. Based on the physical examination and photo analysis, a good and very good cosmetic effect was found in 78.3% of the patients.

Questionnaire responses showed 83.3% of patients evaluating their treatment effects as good or very good (12 months after teleradiotherapy). It has to be borne in mind, however, that questionnaires reflect patients' subjective opinions, hence the difference between patients' evaluations and those of the therapeutic team (83.3% vs. 78.3%). Pain in the breast and increased skin susceptibility were reported by 35% of the patients during follow-up, regardless of the time elapsed from the end of teleradiotherapy. These conditions occurred throughout the treated breast. Oedema of the breast was reported by 14% of the patients 1 month after treatment and 16% of the patients 6 and 12 months after whole-breast radiation therapy. Changes in the breast skin in the form of redness or visible vascular changes were reported as frequent by 36% of the patients after 1 month after teleradiotherapy and 22% in the 6th and 12th months of the follow-up.

5. Conclusions

1. Intraoperative radiotherapy can replace other methods of boost in breast conserving therapy.
2. This method is safe and leads to the shortening of therapy time as compared to electron or photon boost.
3. Radiotherapy boost during surgery not only enables good local control without geographic miss of the tumour, but also delivers good cosmetic effect after therapy.

6. Discussion

Adjuvant radiation therapy of the whole breast following a breast-conserving surgery remains a commonly recognised procedure in early stage breast cancer patients. Reports of the Early Detection of Breast Cancer Group confirm that radiotherapy reduces the risk of local relapse by 75%.¹

The impact of radiation dose on reduction of the relapse rate was, in turn, confirmed by EORTC study 22881-10882 which compared results of treatment and local control for patients treated with adjuvant radiation versus without a boost to the post-operative site. The risk of local relapse in patients who received a boost dose was reduced from 10.2% (no boost) to 6.2% ($p < 0.0001$).⁷ Therefore, it seems advisable that a boost dose to the post-operative site be used, apart from whole breast radiation therapy.

Intraoperative radiation therapy is one of the methods of delivering a higher dose to the tumour bed in adjuvant treatment of breast cancer patients. This modality allows a precise irradiation of the post-operative site as radiotherapy is delivered directly in the course of a surgical procedure. A good preparation and mobilisation of neighbouring tissue in the IORT method is a way to avoid geographical error that may occur with other radiotherapy methods, i.e. brachytherapy or teleradiotherapy to a selected volume. Owing to intraoperative radiation therapy, the period of radiation can also be shortened by one week, i.e. time needed for radiation to the tumour bed in teleradiotherapy.

The study group showed no local relapse in the breast during the one-year follow-up. Similar results have been reported by other authors.^{8,9} Yet with the follow-up period being very short, the result should be looked upon critically and reviewed again in a further stage of the follow-up.

Our study group did not show any early or late severe reactions to radiotherapy (grades 3 and 4). Mild early responses (grades 1 and 2) were found in 23.3% of the patients, which proved the applied treatment to be safe and effective. These results are similar to those provided by published reports analysing combined IORT with external beam radiotherapy.^{8,10-13}

While evaluating a new treatment modality, it is not only the therapeutic effect, manifested with local control and long-term survival (too early to assess in our study group), that matters, but also the cosmetic effect. Based on the physical examination and photo analysis, the cosmetic effect in our study group was rated as good and very good in 78.3% of the patients.^{8,11} This rating was also confirmed by 83.3% of the patients responding to a questionnaire on cosmetic effect. With the skin shifted away from the radiation area in the IORT technique, it was possible to reduce the risk of skin necrosis and telangiectasia in the region of the post-operative site. Treatment with IORT thus proved to be not only a safe modality that does not involve a higher risk of radiation-induced complications, but also the one that provides a satisfactory cosmetic effect.

The analysis of the quality of life and cosmetic effect questionnaires showed that the patients responded to the treatment quite well. Intraoperative radiation therapy and post-surgery external beam radiation did not have a substantial influence on the quality of life and appearance of the treated breast.

Due to its exceptional physical and radiobiological properties, intraoperative radiation therapy can be a good alternative to other methods of boosting dose to the post-operative site in management of low stage breast cancer, enabling a precise therapy to the tumour bed.

Conflict of interest

None declared.

Financial disclosure

None declared.

Acknowledgements

We acknowledge that materials of this article are original, have been made in our Centre and have not been published by any other authors.

REFERENCES

1. Abe O, Abe R, Enomoto K, et al. Effects of radiotherapy and of differences in the extent of surgery for early breast cancer on local recurrence and 15-year survival: an overview of the randomized trials. *Lancet* 2005;**366**:2087–106.
2. Bartelnik H, Horiot JC, Poortmans PM, Struikmans H, Van den Bogaert W. Impact of a higher radiation dose on local control and survival in breast-conserving therapy of early breast cancer: 10-year results of the randomized boost versus no boost EORTC 22881-10882 trial. *J Clin Oncol* 2007;**25**: 3259–65.
3. Kacprowska A, Jassem J. Partial breast irradiation techniques in early breast cancer. *Rep Pract Oncol Radiother* 2011;**16**(6):213–20.
4. Adamczyk B, Murawa P. Preoperative localization of nonpalpable breast nodules – which method to choose? *Rep Pract Oncol Radiother* 2008;**13**(4):201–4.
5. Adamczyk B, Murawa D, Połom K, Spychała A, Nowaczyk P, Murawa P. *Rep Pract Oncol Radiother* 2011;**16**(6):221–6.
6. Połom K, Murawa D, Michalak M, Murawa P. Sentinel node biopsy in breast cancer using infrared laser system first experience with PDE camera. *Rep Pract Oncol Radiother* 2011;**16**(3):82–6.
7. Jones H, Antonini N, Hart A, et al. Impact of pathological characteristics on local relapse after breast-conserving therapy: a subgroup analysis of the EORTC boost versus no boost trial. *J Clin Oncol* 2009;**27**:4939–47.
8. Kraus-Tiefenbacher U, Bauer L, Scheda A, et al. Intraoperative radiotherapy (IORT) in an option for patients with localized breast recurrences after previous external-beam radiotherapy. *BMC Cancer* 2007;**7**:178.
9. Ciabattonef A, Fortuna G, Ciccone V, et al. IORT in breast cancer as boost: preliminary results of a pilot randomized study on use of IORT for stage I and II breast cancer. *Radiother Oncol* 2004;**35**.
10. Klipper B, Kraus-Tiefenbacher U, Wenz F. Intraoperative radiotherapy (IORT) as partial treatment after surgery of early breast cancer. *Radiother Oncol* 2004;**92**.
11. Offersen BV, Overgaard M, Kroman N, et al. Accelerated partial breast irradiation as part of breast conserving therapy of early breast carcinoma: a systemic review. *Radiother Oncol* 2009;**90**:1–13.
12. Luini A, Orecchia R, Gatti G, et al. The pilot trial on interoperative radiotherapy with electrons (ELIOT): update on the results. *Breast Cancer Res Treat* 2005;**93**:55–9.
13. Ollila DW, Klauber-Domer N, Tesche LJ, et al. Feasibility of breast preserving therapy with single fraction in situ radiotherapy delivered intraoperatively. *Ann Surg Oncol* 2007;**14**:660–9.