

available at [www.sciencedirect.com](http://www.sciencedirect.com)journal homepage: <http://www.rpor.eu/>

## Original article

# Hyperfractionated high-dose rate brachytherapy in the treatment of oral tongue cancer

Lubos Tuček<sup>a</sup>, Jiri Petera<sup>b,\*</sup>, Igor Sirák<sup>b</sup>, Milan Vošmik<sup>b</sup>, Helena Doležalová<sup>a</sup>, Simona Brokešová<sup>b</sup>, Miroslav Hodek<sup>b</sup>, Linda Kašáová<sup>b</sup>, Petr Paluska<sup>b</sup>

<sup>a</sup> Department of Stomatology, University Hospital, Hradec Králové, Czech Republic

<sup>b</sup> Department of Oncology and Radiotherapy, University Hospital, Sokolská 581, 500 05 Hradec Králové, Czech Republic

## ARTICLE INFO

## Article history:

Received 19 April 2011

Received in revised form 9 June 2011

Accepted 11 July 2011

## Keywords:

Oral cancer

High-dose rate brachytherapy

## ABSTRACT

**Background:** Low-dose rate brachytherapy is a well established treatment modality of oral cancer. Data about high-dose rate (HDR) brachytherapy are still sparse with various fractionation schedules and heterogeneous results.

**Aim:** The aim of our retrospective study was to evaluate the results of HDR brachytherapy with doses of 3 Gy twice daily.

**Patients and methods:** Twenty patients with squamous cell tongue cancer were treated in the years 2001–2009 by exclusive HDR BT 18 × 3 Gy twice daily. The plastic tube technique was used. Median follow up was 47 months (7.8–118) since brachytherapy.

**Results:** The local and locoregional control was 85% and 68%, respectively. Bone necrosis developed in one case treated without mandibular shielding and soft tissue necrosis in 2 cases.

**Conclusion:** It can be concluded that HDR brachytherapy with 18 × 3 Gy twice daily is safe with promising local control. The risk of nodal recurrences is substantial.

© 2011 Greater Poland Cancer Centre, Poland. Published by Elsevier Urban & Partner Sp. z.o.o. All rights reserved.

## 1. Background

Brachytherapy (BT) is a well established treatment method of early stages of tongue cancer. BT is as effective as surgery for tumor control with better functional and cosmetic results in a majority of cases. In comparison with external beam radiotherapy (EBRT), brachytherapy allows delivery of higher doses of radiation in shorter time with reduction of volume of irradiated healthy tissues. The tumor control is improved and postradiation xerostomia and soft tissue fibrosis are less frequent.

Most experience with BT in tongue cancer was achieved with the manual afterloading technique and iridium wires with continuous low-dose rate (LDR) irradiation. Continuous LDR BT favors normal tissue repair during irradiation and results in a beneficial therapeutic ratio between tumor control probability and normal tissue complication probability. High-dose rate (HDR) afterloading devices have replaced LDR brachytherapy in many radiotherapy departments in the Czech Republic and other countries.<sup>1</sup> HDR BT has a higher biological effect in comparison with LDR BT, which is more profound for normal late reacting tissues than for tumor. The consequence is a less beneficial therapeutic ratio. HDR

\* Corresponding author. Tel.: +420 495 832 183; fax: +420 495 832 081.

E-mail address: [petera@fnhk.cz](mailto:petera@fnhk.cz) (J. Petera).

implants must be fractionated and numerous small fractions are recommended to allow for repair of healthy tissues and to achieve biological equivalence to LDR brachytherapy.<sup>2</sup>

For the use of HDR BT in oral cancer, only some controversial results of limited values are available to date<sup>3</sup> with various fractionation schemes. HDR is often considered to be dangerous for interstitial implants because of higher risk of complications. In our institution, we started with HDR BT of oral cancer in 2001 and since then we have treated 45 patients with BT alone or in combination with EBRT.

## 2. Aim

The aim of our retrospective study was to evaluate the tumor control and complications of HDR BT alone with 3Gy dose per fraction twice daily administered to patients with tongue cancer after tumor excision.

## 3. Patients and methods

### 3.1. Patients

Twenty patients with histologically proven squamous cell tongue cancer were treated by HDR BT alone at the Department of Oncology and Radiotherapy, University Hospital in Hradec Králové between 2001 and 2010. Nine patients were male and 11 were female, the median age was 59 years (43–74). All patients underwent clinical examination, neck ultrasound and chest X-ray prior to the start of the treatment. The patients' characteristics are presented in Table 1. All of them were cN0cM0. Median follow up was 47 months (7.8–118) since BT. The follow up consisted of clinical examination and ultrasound of the neck performed at 3-month intervals, with

X-ray examination once per year. All the patients signed an informed consent for the treatment.

### 3.2. Treatment

The surgery was limited to tumor excision. The margins were histologically negative in 6 patients, microscopically positive in 13 patients and macroscopically positive in 1 patient. Neck dissection as a part of primary treatment was performed in 5 patients. The indications were lymphangiogenesis in 1 case and tumor ulceration in 4 cases.

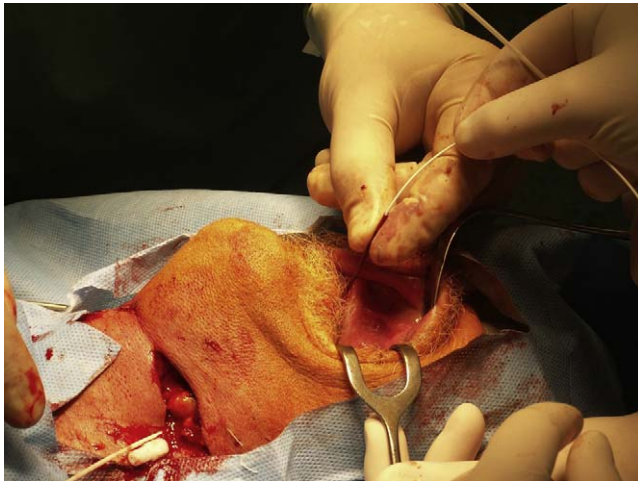
### 3.3. The brachytherapy technique

The technique involving interstitial plastic tubes with 1 cm spacing and double-planar configuration was used for the brachytherapy. Median number of catheters was 7 (3–10). The distribution of catheters in the central plane was either in equilateral triangles or in squares. The afterloading catheters were inserted through hollow stainless steel needles. Because of the technical difficulties with the insertion of the plastic tubes in the posterior part of the tongue, we invented a modification of the outer plastic tube technique. After a puncture with a hollow needle we pushed a guiding wire through the needle, took the needle away and, with the help of the wire, inserted a semirigid plastic tube with a sharp end. It was possible to insert the thin part of the afterloading catheter to the outer tube very easily, then to remove the tube and to pull the catheter out (Fig. 1). In our experience we have never succeeded to use the loop technique in combination with Gammamed, because we were not able to make the source go through the loop. Therefore, we replaced the loop technique with catheters protruding above the tongue (Fig. 2). To ensure that the top dwell position was above the tongue surface, plastic buttons of 9 mm in thickness were placed at the

Table 1 – Patients characteristics.

Patients no.	T category	Grade	Margins	Depth of infiltration (mm)	Neck dissection	Notice
1	1	2	R0	5		
2	1	1	R0	4		
3	2	2	R1	15		
4	1	2	R1	10		
5	1	1	R0	3		
6	1	2	R1	15		Ulceration
7	1	2	R2	4	Yes	Lymphangiogenesis
8	2	3	R1	15		Ulceration
9	1	1	R1	9	Yes	Ulceration
10	1	2	R1	4		
11	1	2	R1	3		
12	1	2	R1	4		Ulceration
13	1	3	R1	3		Terrain of CIS
14	1	2	R1	1		
15	2	2	R0	10		Ulceration
16	1	2	R1	7		
17	1	2	R1	4	Yes	Ulceration
18	1	3	R0	4		
19	2	2	R0	3	Yes	Ulceration
20	1	1	R1	3	Yes	Ulceration

R0 = microscopically negative; R1 = microscopically positive; R2 = macroscopically positive.



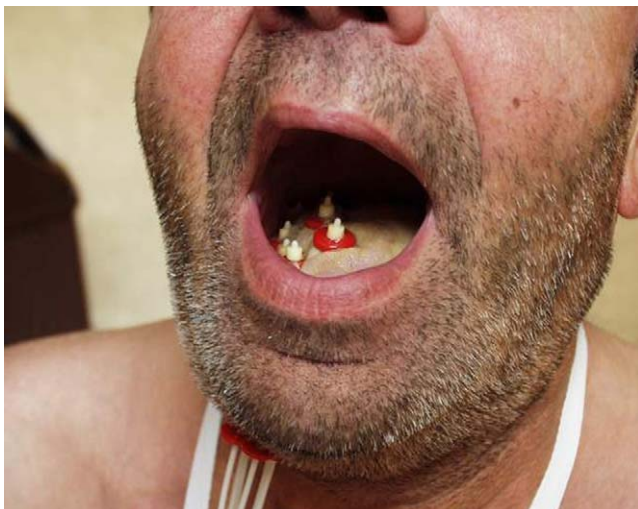**Fig. 1 – Technique of afterloading catheters insertion.**

top end of the catheter. By using a longer dwell time for the top dwell position, the tongue surface received an adequate dose. Catheters were secured by plastic buttons. Dose distribution was calculated using the Abacus-GammaMed planning system (Gammmed; Germany) in the first 6 applications till 2004; in the rest of the patients the Brachyvision (Varian; USA) planning system and CT based planning was used, with much a better chance to optimize the dose to the mandible (Fig. 3), which was contoured as an organ at risk. The prescription points were set at 5 mm outside the catheters. All patients received 18 fractions of 3 Gy administered twice daily with intervals of at least 6 h between fractions. The maximum dose limit to the mandible should be  $<2 \text{ Gy}/1 \text{ cm}^3$  without lead shielding.

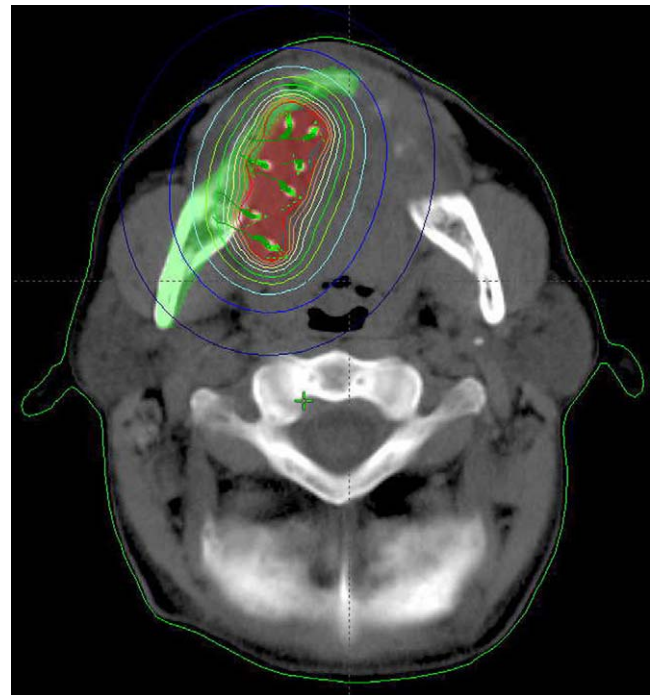
Individualized mandibular lead shielding was used in all patients except for the first one.

### 3.4. Statistical analysis

The Kaplan–Meier survival analysis was used for the estimation of survival functions.



**Fig. 2 – Implantation of afterloading catheters.**



**Fig. 3 – CT based planning of dose distribution.**

## 4. Results

Median volume of minimum target dose (MTD) was  $14.4 \text{ cm}^3$  (2.4–44). Median mean central dose (MCD) was 4.6 Gy (3.5–6.4). Median V150 was  $6.4 \text{ cm}^3$  (1.2–18). Median dose homogeneity index ( $\text{HI} = \text{MTD}/\text{MCD}$ ) was 65% (52–87).

The estimated 5-year local control was 85% and locoregional control was 68%. The probability of 5-year overall survival was 75%.

Two patients recurred only locally. One died of tumor progression to the floor of the mouth despite salvage surgery. The other one had invasive epidermoid cancer in the region of severe dysplasia up to carcinoma in situ. He refused salvage treatment and is alive with the tumor 38 months from the brachytherapy and 12 months from the recurrence. One patient recurred both locally and in the regional lymphatic nodes, and nodal recurrence only was observed in 3 patients. All of them were treated with surgery and EBRT but died of disease progression. The localization of nodal recurrence was submandibular region in all cases.

Most patients experienced grade 2 acute mucositis (according RTOG/EORTC criteria) after brachytherapy, which resolved within 8 weeks after the treatment completion. Only the first patient irradiated without mandibular shielding suffered mandibular osteoradionecrosis which was cured by sequestrectomy. In 2 patients a soft tissue radionecrosis occurred and was resolved after conservative treatment, in one of them the necrosis followed after a dental intervention.

## 5. Discussion

A 5-year local recurrence-free rate for early tongue cancer obtained by surgery is reported at 81–85% for T1 and at 77–85%



for T2 tumors.<sup>4,5</sup> The results achieved by LDR RT are comparable to those of Mazeron et al. who reported a 5-year local control rate of 87% in 155 patients with T1–T2N0M0 oral tongue carcinoma.<sup>6</sup> Published data reporting the use of HDR BT in the treatment of patients with oral cancer are still sparse. Additionally, those series vary in fractionation schemes, doses and results.

Umeda et al. compared the results in 25 patients with stage I–II tongue cancer treated with HDR BT with a group of patients treated with traditional LDR brachytherapy.<sup>7</sup> An average dose of 59 Gy (6 Gy  $\times$  9–10 fractions/5 days) was administered. Nine (36%) of the 25 patients in the HDR group manifested with local recurrence. Mandibular osteonecrosis was found in 5 patients. The local control and the incidence of osteonecrosis were significantly higher in the HDR group than in the LDR group.

Lau et al. reported only 53% local control rate in patients treated with HDR BT. They treated patients with a total dose of 45.5 Gy in 7 fractions.<sup>8</sup> Inoue et al. reported on Phase III trial comparing 25 eligible patients treated with LDR BT and 25 patients treated with HDR BT for early mobile tongue cancer.<sup>9</sup> Hyperfractionated HDR BT with a total dose of 60 Gy in 10 fractions during 1 week was used. Five-year local control rates for the LDR and HDR groups were 84% and 87%, respectively. Tongue ulcer occurred in 1 patient in both groups. Bone exposure occurred in 2 patients in the HDR group. For 1 of the 2 patients with bone exposure, the spacer reducing the dose of mandible was not used.

Yamazaki et al. examined the comparability of LDR BT with HDR BT in patients with early oral tongue carcinoma.<sup>10</sup> HDR BT was used in 58 patients to the total dose of 48–60 Gy in 8–10 fractions. The 5-year local control was 84%, which was comparable with the LDR group.

In our department, we used smaller doses per fraction in comparison with previous studies, which is recommended also by the American Society for Brachytherapy.<sup>11</sup> According to the linear quadratic model, 18 times 3 Gy in 14 days is equivalent to the dose of 66.77 Gy to the tumor with dose rate of 0.5 Gy/h in 7 days, with a slightly higher effect on late tissues (extrapolated response rate 114 Gy vs. 108 Gy). Parameters used for the calculation were:  $\alpha/\beta$  ratio = 10 Gy for tumor and 3 Gy for late tissues; sublethal damage repair time constant 1.2 h<sup>-1</sup> for tumor and 0.46 h<sup>-1</sup> for late tissues; repopulation parameter 0.3 day<sup>-1</sup> for tumor and 0.01 day<sup>-1</sup> for late tissues. Stepping iridium source of Gammamed HDR device and computerized treatment planning allow for optimized dose distribution inside the brachytherapy implant and present physical advantage of HDR brachytherapy. Our regime is close to the fractionation published recently by Guinot et al.<sup>12</sup> Guinot's study of 50 patients with oral tongue carcinoma treated by HDR brachytherapy includes 17 patients treated by exclusive BT with doses of 3–4 Gy per fraction b.i.d. with a minimum interval of 6 h between fractions. The local control was 100%, no case of bone necrosis was reported for this group of patients and soft tissue necrosis was observed in 4 patients. Our results show also a low risk of late complications and a high probability of local control achieved with small doses per fraction administered twice daily.

We observed regional recurrences in 4 of 20 patients (20%) with clinically negative (N0) neck nodes, in 1 case regional metastasis was combined with local recurrence. All

the patients died of the disease despite salvage surgery and EBRT. A wait-and-see policy is often recommended for the majority of patients with early tongue cancers treated by BT,<sup>13–15</sup> because a routine policy of elective neck dissection for clinically negative lymph nodes would subject a significant proportion of patients to an unnecessary procedure.<sup>16</sup> The incidence of regional metastasis of N0 early tongue cancer is reported to be about 20–50%.<sup>17,18</sup> In the study of Fujita et al., 36 of 127 (28%) patients with T1–2N0 oral tongue tumors treated by BT alone had regional metastases and 58% patients were salvaged by neck dissection.<sup>15</sup> Inoue et al. described 6 nodal metastases both in a group of 26 patients treated by LDR BT and a group of 25 patients treated by HDR BT (23% and 24%, respectively).<sup>9</sup> In a large study of Nakagawa,<sup>19</sup> neck metastases occurred in 185 (39%) of the 476 patients who underwent brachytherapy alone and their incidence of neck metastases was not significantly different from the incidence in the group irradiated by combination of EBRT with BT. Macroscopic appearance of the tumor was the only significant risk factor for nodal recurrence identified by a multivariate analysis. The incidence of cervical lymph node metastases was 62% among the invasive/ulcerative type of the tongue carcinoma and was lower among the superficial type and exophytic/nodular type (20 and 35%, respectively). In our study 3 of 4 patients with neck recurrence presented with the ulcerative type of tumor with tumor thickness  $\geq$  10 mm. In the recent study of Chakrabarti et al.,<sup>20</sup> the authors recommend prophylactic nodal irradiation in addition to brachytherapy even for early stage oral cancers treated with interstitial brachytherapy. Tumor thickness > 6 mm and the need for multiplanar implant were found to be statistically significant risk factors for nodal recurrence. A new promising approach to select patients for immediate neck treatment is to predict lymphatic metastases based on gene expression profile analysis.<sup>21</sup>

## 6. Conclusion

The HDR BT schedule of 18  $\times$  3 Gy twice daily is effective, has low risk of late complications and can be escalated. The risk of nodal recurrences is substantial. Mandibular shielding is necessary to reduce the risk of osteonecrosis.

## Acknowledgement

The project was supported by the Research Project MZO 00179906 of the Ministry of Health, Czech Republic.

## REFERENCES

1. Guedea F, Ventura M, Polo A, et al. Patterns of care for brachytherapy in Europe (PC BE) in Spain and Poland: comparative results. *Rep Pract Oncol Radiother* 2007;12:39–45.
2. Lebioda A, Makarewicz R, Rembielak A, Bialas B, Kabacinska R. Estimation of the  $\alpha/\beta$  ratio for lower lip cancer treated with interstitial HDR brachytherapy. *Rep Pract Oncol Radiother* 2007;12:207–10.
3. Strnad V. Treatment of oral cavity and oropharyngeal cancer. Indications, technical aspects and results of interstitial brachytherapy. *Strahlenther Onkol* 2004;180:710–7.

4. Whitehurst JO, Droulias CA. Surgical treatment of squamous cell carcinoma of the oral tongue: factors influencing survival. *Arch Otolaryngol* 1977;**103**:212–5.
5. Spio R, Strong EW. Epidermoid carcinoma of the mobile tongue. Treatment by partial glossectomy only. *Am J Surg* 1971;**122**:707–10.
6. Mazon JJ, Crook JM, Benck V, et al. Iridium 192 implantation of T1 and T2 carcinomas of the mobile tongue. *Int J Radiat Oncol Biol Phys* 1990;**19**:1369–76.
7. Umeda M, Komatsubara H, Nishimatsu N, Yokoo S, Shibuya Y, Komori T. High-dose rate interstitial brachytherapy for the stage I–II tongue cancer. *Oral Surg Oral Med Oral Pathol Oral Radiol Endod* 2000;**90**:667–70.
8. Lau HY, Hay JH, Flores AD, Therfall WJ. Seven fractions of twice daily high-dose rate brachytherapy for node-negative carcinoma of the mobile tongue results in loss of therapeutic ratio. *Radiother Oncol* 1996;**39**:15–8.
9. Inoue T, Inoue T, Yoshida K, et al. Phase III trial of high- vs. low-dose-rate interstitial radiotherapy for early mobile tongue cancer. *Int J Radiat Oncol Biol Phys* 2001;**51**:171–5.
10. Yamazaki H, Inoue T, Yoshida K, et al. Brachytherapy for early tongue cancer: low dose rate to high dose rate. *J Radiat Res* 2003;**44**:37–40.
11. Nag S, Cano ER, Demanses DJ, et al. The American Brachytherapy Society recommendations for high-dose-rate brachytherapy for head and neck carcinoma. *Int J Radiat Oncol Biol Phys* 2001;**50**:1190–8.
12. Guinot JL, Santos M, Tortajada MI, et al. Efficacy of high-dose-rate interstitial brachytherapy in patients with oral tongue carcinoma. *Brachytherapy* 2010;**9**:227–34.
13. Benk V, Mazon JJ, Grimad L, et al. Comparison of curietherapy versus external irradiation combined with curietherapy in stage II squamous cell carcinomas of the mobile tongue. *Radiother Oncol* 1990;**18**:339–47.
14. Shibuya H, Hoshina M, Takeda M, Matsumoto SA, Suzuki S, Okada N. Brachytherapy for stage I & II oral tongue cancer. An analysis of past cases focusing on control and complications. *Int J Radiat Oncol Biol Phys* 1990;**26**:51–8.
15. Fujita M, Hirokawa Y, Kashiwado K, et al. Interstitial brachytherapy for stage I and II squamous cell carcinoma of the oral tongue: factors influencing local control and soft tissue complications. *Int J Radiat Oncol Biol Phys* 1999;**44**:767–75.
16. Vandenbrouck C, Sancho-Garnier H, Chassagne D, Saravane D, Cachin Y, Micheau C. Elective versus therapeutic radical neck dissection in epidermoid carcinoma of the oral cavity: results of randomized clinical trial. *Cancer* 1980;**46**:386–90.
17. Mazon JJ, Crook JM, Marinello G, Walop W, Pierquin B. Prognostic factors of local outcome for T1 T2 carcinomas of oral tongue treated by Iridium 192 implantation. *Int J Radiat Oncol Biol Phys* 1990;**19**:281–5.
18. Pernot M, Malissard L, Aletti P, Hoffstetter S, Forcard JJ, Bey P. Iridium-192 brachytherapy in the management of 147 T2N0 oral tongue carcinomas treated with irradiation alone: comparison of two treatment techniques. *Radiother Oncol* 1992;**23**:223–8.
19. Nakagawa T, Shibuya H, Yoshimura R, et al. Neck node metastasis after successful brachytherapy for early stage tongue carcinoma. *Radiother Oncol* 2003;**68**:129–35.
20. Chakrabarti B, Chorai S, Basu B, et al. Late nodal metastasis in early-stage node-negative oral cavity cancers after successful sole interstitial brachytherapy: an institutional experience of 42 cases in India. *Brachytherapy* 2010;**9**:254–9.
21. Watanabe H, Mogushi K, Miura M, et al. Prediction of lymphatic metastasis based on gene expression profile analysis after BT for early stage oral tongue carcinoma. *Radiother Oncol* 2008;**87**:237–42.