

available at [www.sciencedirect.com](http://www.sciencedirect.com)journal homepage: <http://www.rpor.eu/>

## Original article

# Retroperitoneal primitive neuroectodermal tumour (PNET). A case report and review of the literature

Lena Marinova

Department of Diagnostic Imaging and Radiotherapy, Medical University, Varna, Bulgaria

### ARTICLE INFO

#### Keywords:

Primitive neuroectodermal tumour  
Neuroectodermal tumour  
External beam radiotherapy  
Multimodality treatment  
Radiosensitivity

### ABSTRACT

**Purpose:** We report a clinical case and present a brief review of the literature of peripheral primitive neuroectodermal tumour (PNET) as a rare disease. We discuss the difficult clinical and pathological diagnosis and the multidisciplinary approach to treatment of PNET. We debate radiosensitivity of extracranial recurrent retroperitoneal PNET.

**Methods and materials:** External beam radiation therapy was applied for a non-resectable local recurrence of retroperitoneal PNET in a 74-year-old woman. There were no distant metastases and our patient has refused chemotherapy.

**Results:** Local tumour control (LTC) was achieved after administration of a total dose of 60 Gy in 30 fractions by external beam 60 Cobalt radiotherapy.

**Conclusions:** PNET is an aggressive malignant tumour infiltrating lymphatics and metastasizing haematogenously. It requires a multimodality treatment. Late local recurrence of extracranial retroperitoneal PNET has shown high radiosensitivity, so local tumour irradiation could be a radical treatment even in non-resectable cases.

© 2009 Wielkopolskie Centrum Onkologii. Published by Elsevier Urban & Partner Sp. z.o.o. All rights reserved.

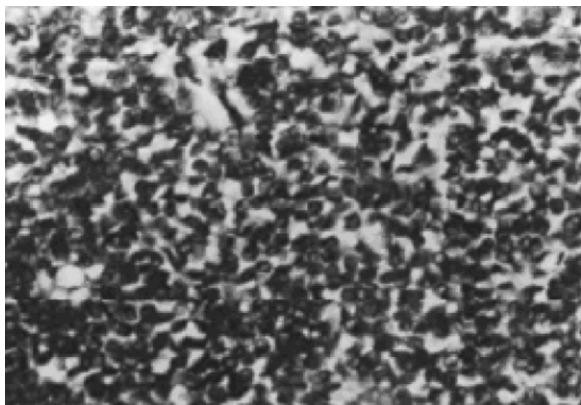
## 1. Introduction

Extracranial PNET is a rare disease with fast and infiltrating growth. In the past PNET was called neuroepithelioma. It is classified today as a neoplasm with neuroperipheral origin.<sup>1</sup> The tumour shows a very interesting histology. Extrasosseous neoplasm, including Ewing sarcoma, was described first by Teft et al. in 1969.<sup>2</sup> PNET consists of small, round cells and has Homer-Wright rosettes. After clinical observations on non-differentiated brain tumours (consisting of 90–95% non-differentiated cells) Hart and Earle in 1973 defined such tumour similarly to primitive neuroectodermal neoplasm.

Every neoplasm with primitive non-differentiated cells might be called PNET despite different tumour localization.<sup>3</sup> The WHO classification considers it “embryonal-like tumours” and PNET is a generic name for medulloblastoma.<sup>4</sup> Ewing sarcoma and PNET have similar pathomorphological characteristics, prognosis, immunohistochemistry and cytogenetics.<sup>5</sup>

Extracranial peripheral PNET can be found in different body sites. Many authors have reported PNET in the nasal cavity,<sup>6</sup> maxilla,<sup>7,8</sup> orbit,<sup>9</sup> heart,<sup>10</sup> kidney,<sup>11</sup> adrenal glands,<sup>12</sup> retroperitoneum,<sup>13</sup> ovary,<sup>14,15</sup> cervix,<sup>5,16,17</sup> uterus,<sup>18–20</sup> broad ligament of the body of the uterus,<sup>21</sup> vulva, vagina and septum rectovaginalis,<sup>22–26</sup> thoracic region (Askin’s tumour),<sup>27</sup> extremities,<sup>28,29</sup> etc. Routine use of immunohistochemistry and electronic microscopy facilitate diagnosis of peripheral PNET, so more and more cases are published.<sup>1</sup>

E-mail address: [rad.marinova@abv.bg](mailto:rad.marinova@abv.bg).



**Fig. 1 – Poorly to well formed rosettes.**

## 2. Case report

We present a 74-year-old woman with retroperitoneal PNET diagnosed in 2001. In 2001 a maximal tumour resection (R1) was carried out. The patient refused any adjuvant chemotherapy and radiotherapy. Seven months later a second operation was performed because of growing tumour mass. Radical surgical resection (R0) was done. A non-resectable local relapse without distant metastasis occurred after 4 years' remission (2006). External beam radiation therapy with mainly analgesic intent was performed.

*Preoperative finding (2001):* A large tumour mass with a size of 10/15 cm was palpated in the abdominal area.

*Intraoperative observation (2001):* A large tumour mass with a size of 13/16 cm was found sited in the retroperitoneum, pushing off the pancreas, duodenum and transverse colon. The formation grew out to the radix mesenterii and the duodenum, as well as to the vena cava inferior.

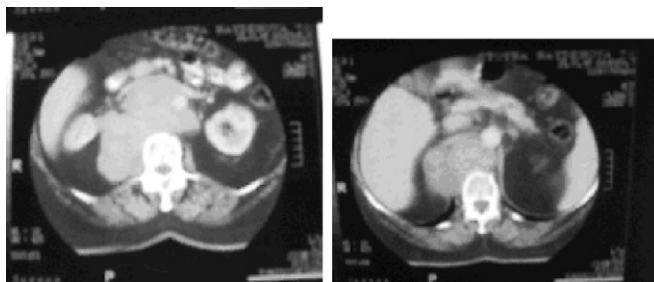
*Intraoperative (second operation after 7 months—2002):* The tumour mass started from the hilus of the right kidney, reaching deep into the intervertebral space, and grew out close to the vena renalis and vena cava inferior.

*Histology and immunohistochemistry:* The tumour consists of small, round cells, with poorly to well-formed rosettes. The diagnosis was primitive malignant tumour with MIC2 gene expression (Fig. 1).

Chest X-ray, ultrasound of abdomen, bone scan and CT of brain showed no distant metastasis.

*CT of abdomen (06.2006—before irradiation).* There is no ascites. Liver, gall-bladder, pancreas and spleen have normal size and structure. A large lobulated parenchymal tumour mass was registered in the prevertebral space starting from the level of the lower posterior mediastinum and it was traced retroperitoneally to the level of the aortic bifurcation. The mainly homogeneous look of the structure after contrast enhances its density and reveals peripheral hypodense zones, suggesting necrosis.

The mass embraces like a muff the large retroperitoneal vessels, the main branches of the abdominal aorta at the level of the kidney artery, infiltrating the intraperitoneal space, and invades the right iliopsoas muscle. Both kidneys are of normal size and excrete symmetrically without drainage dysfunc-



**Fig. 2 – CT of retroperitoneal PNET recurrence.**

tion. The CT diagnosis was retroperitoneal tumour recurrence (Fig. 2).

### 2.1. Radiotherapy

The retroperitoneal space was initially irradiated on a megavoltage machine (Cobalt 60) with single fractions of 2 Gy to a total dose of 44 Gy. Because the palliative analgesic effect was achieved, it was decided that the boost dose should be applied. The retroperitoneal space with the proximity of kidneys, spinal cord and liver is a difficult area for irradiation, so we delivered the maximum possible total dose of 60 Gy.

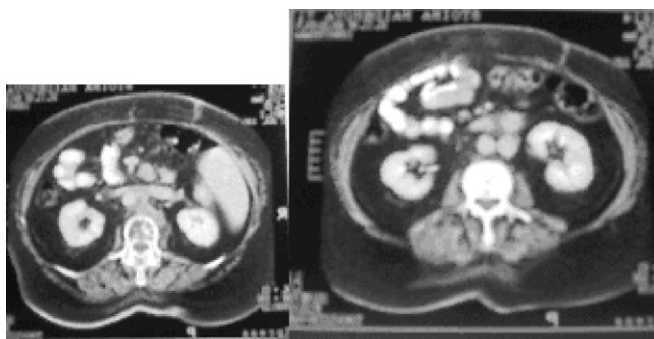
#### 2.1.1. Follow-up investigations

*CT of abdomen (2 months after the end of the radiotherapy).* There is no ascites. Liver, gall-bladder, pancreas and spleen appear to have standard size and structure. Both kidneys are of normal size and excrete symmetrically without drainage dysfunctions. No enlarged lymph nodes were revealed.

Compared to the previous CT, no retroperitoneal mass is scanned. Thickened soft tissues are found in the right prevertebral space at the level of L1–2; after contrasting no change in the density was established. Blurred lateral delineations of the right psoas muscle were noted.

#### 2.1.2. Conclusion

CT diagnosis was fibrosis (Fig. 3).



**Fig. 3 – CT scans after the application of the total irradiation dose of 60 Gy. Local tumour control achieved.**

### 3. Discussion

A literature review demonstrates that retroperitoneal PNET is a group of heterogeneous tumours including peripheral PNET and retroperitoneal non-differentiated sarcoma. We discuss a few major points of the problem:

- (1) *Difficult diagnosis of PNET.* Using only anamnesis and imaging modalities it is impossible to obtain the diagnosis preoperatively.<sup>12</sup> The pathohistological diagnosis is difficult.

Differential diagnosis includes many tumour entities such as primary small cell tumour, Wilms' tumour, carcinoid tumour, rhabdomyosarcoma, neuroblastoma, osteosarcoma, non-Hodgkin lymphoma, malignant melanoma and metastasis.<sup>30</sup> Immunohistochemistry and electron microscopy examinations are required. It refers to immature primitive malignant tumour, expressing the MIC2 gene, proved by the marker CD99.<sup>15,31</sup> Homer-Wright (H-W) rosettes are often found.<sup>32</sup> Cells seen on electron microscopic examination are characterized by small amounts of mitochondria and glycogen particles without neurosecretory granules.<sup>5,32</sup>

- (2) *Optimal treatment of PNET.* There are no standard guidelines or diagnosis and treatment of peripheral PNET, because of the small number of cases in different body sites.<sup>33</sup> Extraosseous PNETs are more aggressive, with worse prognosis than bone PNET (Ewing's sarcoma), and thus require multimodal treatment.<sup>34,35</sup> It has a trend to relapse locally, and to develop metastasis in the regional lymph nodes, lung, liver and bones.<sup>5</sup> Prognostic factors are based on the tumour stage, grade, patient's age, extent of the surgery, surgical margin status, treatment beginning time, etc.

Some authors have reported about chemotherapy for six weeks before or after surgery or radiotherapy.<sup>13</sup> Chemotherapy protocols for Ewing's sarcoma could be useful. PNET has also shown sensitivity to other chemotherapy regimens—ifosfamide, etoposide, teniposide and cisplatin.<sup>29,33</sup> In our case the patient has absolutely refused postoperative chemotherapy.

After biopsy or R1–R2 surgery radiotherapy to a total dose of 55–60 Gy is required.<sup>13,36</sup> Previous studies on combined treatment (surgery, radiotherapy and chemotherapy) of PNET have shown that this is a radio- and chemosensitive immature embryonic tumour. The observations and clinical experience demonstrate moderate radio- and chemosensitivity. Four to six cycles of doxorubicin and cyclophosphamide, radical surgery and irradiation lead to remission and dramatic tumour reduction.<sup>37</sup> Because of the sporadic nature of cases, both chemotherapy regimens<sup>1</sup> and total dose of irradiation are still not specified. Intensive follow-up with CT or MRI of abdomen and retroperitoneum every 6 months is needed.

- (3) *Radiosensitivity of late local PNET relapses.* Published data for PNET illustrate odd tumour characteristics to recur after 2–5 years, or even after 15 years.<sup>38</sup> We are presenting the current case of extracranial retroperitoneal PNET not only because of the casuistry, but as a case of rare late only local relapse, without distant metastasis. Although the recur-

rent tumour was aggressive, spreading over the adjacent major vessels and nerves, it was totally controlled after a total dose of 60 Gy. Our results support the thesis of moderate to high PNET radiosensitivity and demonstrate the possibility to control even non-resectable advanced cases by radical radiation doses.

### 4. Conclusions

1. PNET is an aggressive, immature embryonic radiosensitive tumour that tends to recur locally and to metastasize.
2. Retroperitoneal PNET is a radiosensitive tumour, for which the application of radical doses is recommended even in the case of non-resectable recurrence.
3. The biological behaviour of PNET predetermines the late local relapses. This requires multimodality treatment with surgery, radiotherapy and chemotherapy.

### REFERENCES

1. Isreal M, Miser J, Triche TJ. Neuroepithelial tumours. In: Pizz PA, Poplack DG, editors. *Pediatric oncology*, 29. Philadelphia: Lippincott; 1989. p. 923–34.
2. Teft M, Vawter GF, Mitus A. Paravertebral "round cell" tumors in children. *Radiology* 1969;92:1501–9.
3. De Vita VT, Helman Jr S. Neoplasms of the central nervous system in cancer. In: De Vita V, Helman S, editors. *Principles and practice of oncology*. 7th ed. Philadelphia: Lippincott Williams and Wilkins; 1997. p. 2059–60.
4. Kielher P, Bueger PC, Scheithauer BW. The new WHO classification of brain tumours. *Brain Pathol* 1993;3:255–68.
5. Malpica A, Moran CA. Primitive neuroectodermal tumor of the cervix: A clinicopathologic and immunohistochemical study of two cases. *Ann Diagn Pathol* 2002;6(5):281–7.
6. Böör A, Jurkovic I, Friedmann I, et al. Extraskelatal Ewing's sarcoma of the nose. *J Laryngol Otol* 2001;115:74–6.
7. Shah N, Roychoudhury A, Sarkar C. Primitive neuroectodermal tumor of maxilla in an adult. *Oral Surg Oral Med Oral Pathol Oral Radiol Endod* 1995;80(6):683–6.
8. Carvalho CM, Valette G, Nicolas G. Maxillar localization of a congenital peripheral primitive neuroectodermal tumor: A case report. *Int J Pediatr Otorhinolaryngol* 2006;1(1):27–32.
9. Kiratli H, Bilgic S, Gedikoglu G. Primitive neuroectodermal tumor of the orbit in an adult: A case report and literature review. *Ophthalmology* 1999;106(1):98–102.
10. Besirli K, Arslan C, Tüzün H, Öz B. The primitive neuroectodermal tumor of the heart. *Eur J Cardiothorac Surg* 2000;18(5):619–21.
11. Mor Y, Nass D, Raviv G, et al. Malignant peripheral primitive neuroectodermal tumour of the kidney. *Med Pediatr Oncol* 1994;23:437–40.
12. Komatsu S, Watanabe R, Naito M, et al. Primitive neuroectodermal tumor of the adrenal gland. *Int J Urol* 2006;13(5):606–10.
13. Eilber FC, Eilber KS, Eilber FR. Retroperitoneal sarcomas. *Curr Treat Options Oncol* 2000;1(3):274–8.
14. Demirtas E, Guven S, Seda Guvendag Guven E, et al. Two successful spontaneous pregnancies in a patient with a primary primitive neuroectodermal tumor of the ovary. *Fertil Steril* 2004;81(3):679–81.
15. Kawauchi S, Fukuda T, Miyamoto S, et al. Peripheral primitive neuroectodermal tumor of the ovary confirmed by CD 99 immunostaining. Karyotypic analysis, and RTPCR for EWS/Fli-1 chimeric m RNA. *Am J Surg Pathol* 1998;22:1417–22.

16. Tsao AS, Roth LM, Sandler A, Hurteau JA. Cervical primitive neuroectodermal tumor. *Gynecol Oncol* 2001;**83**:138-42.
17. Cenacchi G, Pasquinelli G, Montanaro L, et al. Primary endocervical extra osseous Ewing's sarcoma/PNET. *Int J Gynecol Pathol* 1998;**17**(1):83-8.
18. Odunsi K, Olatinwo M, Collins Y, et al. Primary primitive neuroectodermal tumor of the uterus: a report of two cases and review of the literature. *Gynecol Oncol* 2004;**92**(2):689-96.
19. Daya D, Lukka H, Clement PB. Primitive neuroectodermal tumors of the uterus: a report of four cases. *Hum Pathol* 1992;**23**:1120-9.
20. Fukunaga M, Nomura K, Endo Y, Ushigome S, Aizawa S. Carcinosarcoma of the uterus with extensive neuroectodermal differentiation. *Histopathology* 1996;**29**:565-70.
21. Lee KM, Wah HK. Primary Ewing's sarcoma family of tumors arising from the broad ligament. *Int J Gynecol Pathol* 2005;**24**(4):377-81.
22. Scherr GR, D'Ablaing III G, Ouzounian JG. Peripheral primitive neuroectodermal tumor of the vulva. *Gynecol Oncol* 1994;**54**:254-8.
23. Vang R, Taubenberger JK, Mannion CM, et al. Primary vulvar and vaginal extra osseous Ewing's sarcoma/peripheral neuroectodermal tumor: diagnostic confirmation with CD99 immunostaining and reverse transcriptase-polymerase chain reaction. *Int J Gynecol Pathol* 2000;**19**:103-9.
24. Petkovic M, Zamolo G, Muhvic D, Coklo M, Stifter S, Antulov R. The first report of extra osseous Ewing's sarcoma in the rectovaginal septum. *Tumori* 2002;**88**:345-6.
25. Farley J, O'boyle JD, Heaton J, Renmenga S. Extra osseous Ewing sarcoma of the vagina. *Obstet Gynecol* 2000;**96**:832-4.
26. Liao X, Xin X, Hong Lu X. Primary Ewing's sarcoma-primitive neuroectodermal tumor of the vagina. *Gynecol Oncol* 2004;**92**:684-8.
27. Shah ASM, Mohamed Z, Abdullah A. Primitive neuroectodermal tumor of the lung with pericardial extension: a case report. *Cardiovasc Pathol* 2007;**16**(6):351-3.
28. Hara O, Yalcin Yuksel H, Hilmi Murati H, et al. A case of primitive neuroectodermal tumor in the distal phalanx. *Jnt Dis Rel Surg* 2007;**18**(3):130-3.
29. Harder Y, Buechler U, Vogelin E. Primitive neurodermal tumor of the thumb metacarpal bone. A case report and literature review. *J Hand Surg Am* 2003;**28**:346-52.
30. Stout AP. A tumour of the ulnar nerve. *Proc N Y Pathol Soc* 1918;**18**:2-12.
31. Liombart-Bosch A, Contesso G, Peydro-Olaya A. Histology, immunohistochemistry, and electron microscopy of small round cell tumors of bone. *Semin Diagn Pathol* 1996;**13**:153-70.
32. Na J, Li J, Fang Z. Clinico-pathologic study of Ewing's sarcomas of bone and soft tissue and peripheral primitive neuroectodermal. *Zhonghua Zhong Liu Za Zhi* 1998;**20**:71-3.
33. Kimber C, Michalski A, Spitz L, et al. Primitive neuroectodermal tumours: anatomic location, extent of surgery, and outcome. *J Pediatr Surg* 1998;**33**:39-41.
34. Enzinger FM, Weiss SW. Primitive neuroectodermal tumors and related lesions. In: Enzinger FM, Weiss SW, editors. *Soft tissue tumors*. 4th ed. St. Louis: CV Mosby; 2001. p. 1265-311.
35. Terrier P, Henry-Amar M, Triche TJ, et al. Is neuro-ectodermal differentiation of Ewing's sarcoma of bone associated with an unfavorable prognosis? *Eur J Cancer* 1995;**31A**:307-14.
36. Evans RG, Nesbit ME, Gehan EA, et al. Multimodal therapy for the management of localized Ewing's sarcoma of pelvic and sacral bones: a report from the second intergroup study. *J Clin Oncol* 1991;**9**(7):1173-80.
37. Bacci G, Ferrari S, Bertoni F, et al. Neoadjuvant chemotherapy for peripheral malignant neuroectodermaltumor of bone: recent experience et the Instituto Rizzoli. *J Clin Oncol* 2000;**18**:885-92.
38. Rao RD, Robins HI, Mehta MP. Late recurrence of a primitive neuro-ectodermal tumor. *Oncology* 2001;**61**(3):189-91.