

Whole body MR in patients with multiple myeloma

Alina PIEKAREK, Piotr SOSNOWSKI, Adam NOWICKI, Mieczysław KOMARNICKI

Received: 11.05.2009

Accepted: 13.07.2009

Subject: original article

Clinical Radiology Department

Address for correspondence:

Alina Piekarek

Clinical Radiology Department

Poznań University

of Medical Sciences

Długa 1/2

Poznań, Poland

e-mail: alinamed@hotmail.com

ABSTRACT

BACKGROUND: Multiple myeloma is a cancer of plasma cells which leads to bone marrow infiltration.

AIM: Whole-body MR is the most sensitive imaging method available to detect multiple myeloma lesions.

MATERIAL AND METHODS: MR scans were performed in 100 patients with multiple myeloma who were receiving treatment in the Haematology Clinic in Poznań in the years 2005–2006. Whole-body MR scans were performed with general coil 1.0 T in STIR sequences and T1 sequences, in coronal and sagittal planes with scanning area covering the head, neck, trunk and the limbs (FOV for specific regions was 36–48 cm). The bone lesions were classified as focal (monofocal/multifocal lesions), infiltrative, mixed and “salt and pepper” type. Depending on the size of the lesions the patients were included in one of three groups according to Salmon-Durie Plus classification.

RESULTS: Four main types of multiple myeloma were distinguished based on MR scans: focal (48 patients; monofocal in 10 patients), infiltrative (17 patients), mixed type (19 patients) and “salt and pepper” type (4 patients). The remaining 12 patients had no multiple myeloma lesions in the bone marrow. Additionally, in 18% of patients a soft tissue mass could be observed. According to Salmon-Durie Plus categorisation 27 subjects were classified as having stage I, 16 patients stage II and 57 patients stage III disease. In 12% of patients MR data changed the disease staging.

CONCLUSIONS: WB MR is a sensitive and effective diagnostic method with an important impact on staging and further treatment of multiple myeloma.

KEY WORDS: whole-body MR (WB MR); multiple myeloma (MM); Salmon-Durie Plus (S-D Plus)

BACKGROUND

Multiple myeloma (*myeloma multiplex*) is a malignant neoplasm of plasma cells which invade the bone marrow. Multiple myeloma constitutes about 1% of all neoplasms and about 13% of blood neoplasms. The disease may invade the skeleton and the kidneys, may impair immune system function and may lead to haematological abnormalities. Prognosis depends on disease stage, particularly at the time of diagnosis. Treatment involves chemotherapy and bone marrow transplant, as well as radiotherapy.

AIM

Whole-body MR (WB MR) is the most sensi-

tive imaging method available to detect multiple myeloma lesions.

MATERIALS AND METHODS

Whole-body MR scans were performed in 100 subjects with multiple myeloma (39 females and 61 males; age 32 to 79 years; mean age 59.22 years) who were receiving treatment in the Haematology Clinic in Poznań University of Medical Sciences in the years 2005–06. In 62 patients WB MR was performed before the initiation of the treatment, whereas the remaining 38 patients had their WB MR scans performed during multi-phase treatment (after chemotherapy, bone marrow trans-

plant and/or radiotherapy). The time period between WB MR and treatment completion ranged from 3 to 21 days (17 days on average) and it was dependent on the disease stage, overall patient condition and the availability of WB MR.

Whole-body MR scans were performed using a general coil 1.0 T MR apparatus in STIR sequences (TR 2700 ms, TE 50 ms, TI 110 ms) and T1 sequences (TR 450 ms, TE 50 ms), in coronal and sagittal planes, covering the head, neck, trunk and the upper and lower limbs to the knee level (FOV for specific regions ranged from 36 to 48 cm). Additional sequences were performed in 19 patients with sporadic lesions detected in the head, abdomen and the joints. Bone marrow status was graded 0–2, both for focal and for infiltrative lesions, where:

0 = No lesions

1 = Uncertain lesions (indirect signal in STIR and/or T1 sequences)

2 = Certain lesions (significantly high signal in STIR sequences and significantly low signal in T1 sequences)

The number of focal lesions for a specific body region was determined and the lesion area was subjectively categorized as “no infiltration”, “minor infiltration” and “extensive, homogeneous infiltration”. Depending on the extent of the lesions the patients were included in one of three groups according to the Salmon-Durie Plus classification. (Table 1)

RESULTS

Whole-body MR scans allowed four main types of multiple myeloma to be distinguished:

1. Focal type (high signal foci in STIR sequences and low signal foci in T1 sequences) was observed in 48 patients, including monofocal type – detected in 10 patients. The smallest foci of <1 cm diameter were found in skull bones, whereas the largest foci of >4 cm diameter were detected in pelvic bones (Fig. 1–2)*

2. Infiltrative type (homogeneous infiltration of high signal in STIR sequences and low signal in T1 sequences) – detected in 17 patients (Fig. 3)

Table 1. Salmon-Durie Plus classification of multiple myeloma lesions

| | |
|---|---|
| I | 0–4 foci and/or absence of infiltration in MR/PET scans |
| II | 5–20 foci and/or minor infiltration in MR/PET scans |
| III | >20 foci and/or extensive, massive infiltration in MR/PET scans |
| A: creatinine <2 mg/dl B: creatinine >2 mg/dl | |

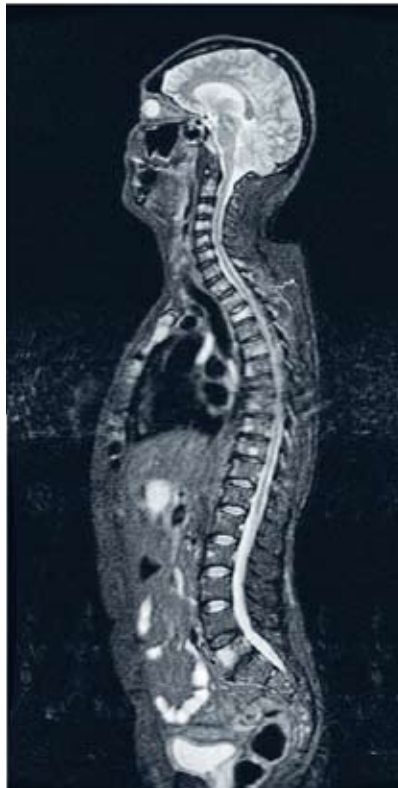

Fig. 1. Multifocal lesions, Stage III: b – sagittal STIR image: high signal focal lesions in the skull, sternum and vertebral bodies with collapsed Th2, c – sagittal SE T1-W image: low signal lesions in the sternum and vertebral bodies

3. Mixed type (diffuse foci seen against the infiltrative lesion background) – detected in 19 patients

4. “Salt and pepper” type (with high signal fat islets in T1 sequences) – detected in 4 patients

The remaining 12 patients had no multiple myeloma lesions in the bone marrow.

In 18% of our patients a soft tissue mass

* Nother focal lesions were taken into account (for instance angiomas of thoracic and lumbar vertebrae with high signal T1 and STIR (T2-W)).

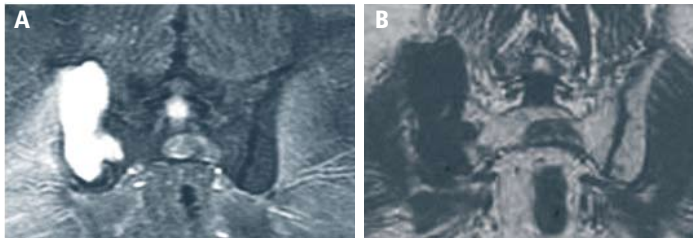


Fig. 2. Local mass in the right iliac bone over 9 cm in diameter: a – coronal STIR image, b – coronal SE T1-W image

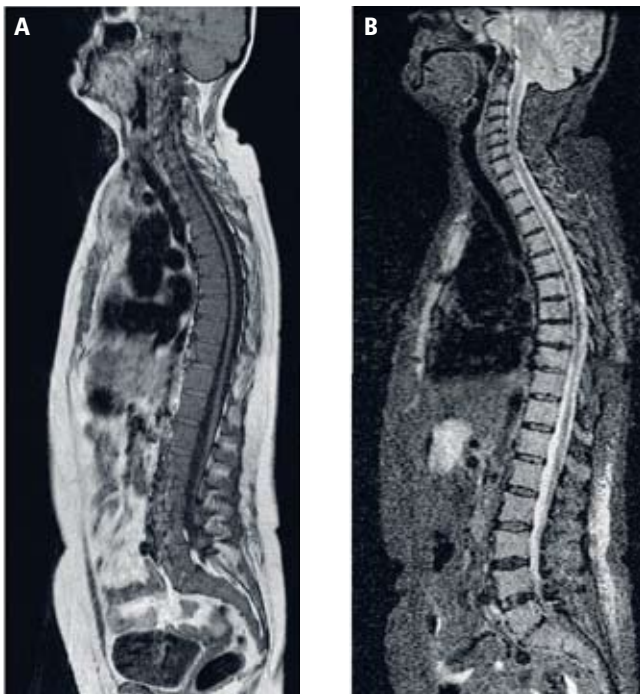


Fig. 3. Homogeneous infiltration, Stage III: a – sagittal T1-W image, low signal of the bone marrow in the sternum and in the spine; b – sagittal STIR image, high signal of the bone marrow

Table 2. Clinical vs. MRI staging: changes of staging – lower (L), higher (H) Clinical Staging MRI Staging

| | | |
|-----------|---------|---------|
| I stage | 23 | 27 |
| II stage | 28 (4L) | 16 (8H) |
| III stage | 49 | 57 |

was observed, usually located paravertebrally or in the pelvis. (Fig. 2). Forty-five subjects suffered from the fracture of at least one thoracic vertebra and 28 experienced fractures of lumbar vertebrae. Femoral frac-

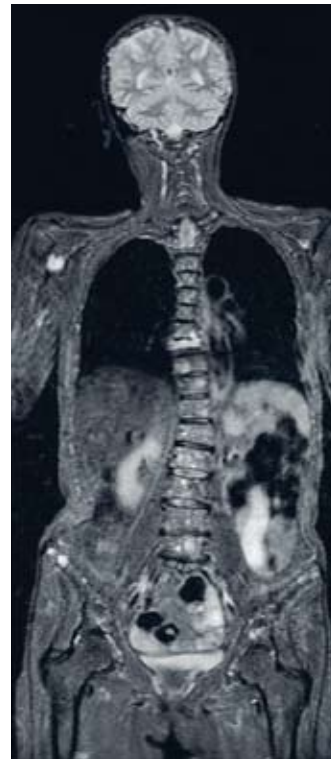

Fig. 4. Multifocal lesions, Stage III: a – coronal STIR, high signal lesions in the spine, pelvis, skull

ture occurred in 3 subjects. Of the total number of fractures (141), 95% involved the axial skeleton. According to Salmon-Durie Plus 27 patients were classified as having stage I, 16 patients stage II and 57 patients stage III disease (Table 2).

Disease staging as determined by clinicians based on biochemical markers and standard radiological scans was changed in 12 patients, of which 8 were re-classified to a higher stage and 4 to a lower stage of multiple myeloma.

DISCUSSION

„The reference whole-body MR protocol for multiple myeloma patients comprises two sequences, i.e. STIR and SE T1, in coronal and sagittal planes [1–4].

Typical multiple myeloma lesions yield a significantly high signal in STIR sequences and a low signal in T1 sequences [3, 5–7]. Bone marrow infiltration is manifested by means of diffuse foci or infiltrative lesions which may be accompanied by pathological fractures of the axial skeleton [4–9].

Based on the results of investigations of 77 subjects Baur-Melnyk et al. [7] distinguished the following types of the disease: focal multiple myeloma in 30% of patients, homogeneous infiltration in 38% of patients, mixed type lesions in 11% of patients and “salt and pepper” type of disease (with high signal fat islets in T1 sequences) in 3% of patients. In 28% of subjects bone marrow presentation was normal, but that did not exclude the diagnosis of multiple myeloma.

In our study material focal lesions were found in 48% of patients, homogeneous infiltration in 17% of patients, mixed type lesions in 19% of patients and “salt and pepper” type of lesions in 4% of patients. Clinical staging in most of our patients was advanced and in this stage multifocal lesions dominated (Fig. 1). In 18% of patients a soft tissue mass could be observed extravertebrally. In 12 subjects no bone marrow lesions could be observed; they were classified as stage I (Salmon-Durie Plus).

Pathological fractures primarily involved the axial skeleton in our study, but in less than 50% of cases (67/141) they were associated with focal or infiltrative lesions. Lecouvet et al. [9] proved that not every fracture in multiple myeloma patients is related to visible infiltration of the bonemarrow and in their study infiltrative lesions were associated only in 46% of fracture cases. This explains the low specificity of standard radiography [3, 4, 7, 8]

Whole-body MR scanning is an independent factor that can change both disease staging and prognosis, which has been reflected in the modification of the three-stage Salmon-Durie classification [1]. High sensitivity of MR in detecting bone marrow lesions is of particular importance in situations when conventional imaging does not reveal any abnormalities. This early stage of the disease, i.e. “smouldering disease”, does not require treatment, as a “watch and wait strategy” has been proved sufficient [7, 10]. Patients with stage I disease in whom MR scans reveal no lesions (12% of subjects in our study), patients with less than 4 foci and patients with “salt and pepper” type of lesions do not require chemotherapy. In an active form of multiple myeloma with extensive bone marrow infiltration WB MR can

reveal massive infiltrations or verynumerous (often incalculable) foci that are dispersed throughout the whole skeletal system [7]. In our study material, in 8 subjects WB MR revealed more advanced disease as compared to its clinical staging. Four patients, classified first to stage II of disease, after WB MR were re-classified as stage I and no treatment was needed (“watch and wait strategy”).

Some authors emphasize the high sensitivity of T1 SE fat-saturated scans with contrast enhancement, particularly in patients with a high degree of bone marrow infiltration [3, 7, 11] and in recently diagnosed, pre-treatment cases. These scans and control studies seem to be of particular value in monitoring the efficacy of treatment.

CONCLUSIONS

WB MR is a sensitive and effective diagnostic method with an important impact on staging and further treatment of multiple myeloma.

References

1. L Durie BGM: The role of anatomic and functional staging in myeloma: Description of Durie/Salmon plus staging system. *EJC* 2006; 42: 1539–43
2. Angtuaco EJC, Fassas ABT, Walker R et al: Multiple myeloma: Clinical review and diagnostic imaging. *Radiology* 2004; 231: 11–23
3. Kavanagh E, Smith C, Eustace S: Whole body turbo STIR MR imaging: controversies and avenues for development. *Eur Radiol* 2003; 13: 2196–205
4. Lecouvet FE, Malghem J, Michaux L et al: Skeletal survey in advanced multiple myeloma: radiographic versus MR imaging survey. *Brit J Haematol* 1999; 106: 35–9
5. Baur A, Stabler A, Bartl R et al: MRI gadolinium enhancement of bone marrow: age related changes in normals and in diffuse neoplastic infiltration. *Skeletal Radiol* 1997; 26: 414–8
6. Baur A, Stabler A, Steinborn M et al: Magnetresonanztomographie beim Plasmocytom: Wertigkeit verschiedener Sequenzen bei diffuser und lokaler Infiltrationsform. *Fortschr Roentgenstr* 1998; 168(4): 323–9
7. Baur-Melnyk A, Buhmann S, Dürr HR, Reiser M: Role of MRI for the diagnosis and prognosis of multiple myeloma. *EJR* 2005; 55: 56–63

8. Ghanem N, Lohrmann C, Engelhart M et al: Whole-body MRI in the detection of bone marrow infiltration in patients with plasma cell neoplasms in comparison to the 15 radiological skeletal survey. *Eur Radiol* 2006; 16: 1005–14
9. Lecouvet FE, Vande Berg BC, Maldague BE et al: Vertebral compression fractures in multiple myeloma. Distribution and appearance at MR imaging. *Radiology* 1997; 204: 195–9
10. Kyle R: Multiple myeloma. Diagnostic challenges and standard therapy. *Semin Hematol* 2001; 38 (2 Suppl 3): 11–4
11. Moehler TM, Hawighorst H, Neben K et al: Bone marrow microcirculation analysis in multiple myeloma by contrast-enhanced dynamic magnetic resonance imaging. *Int J Cancer* 2001; 93: 862–8