

Received: 2005.01.06
Accepted: 2005.05.13
Published: 2005.09.20

Results of interstitial HDR brachytherapy for cancer of the lower lip

**Andrzej Lebioda^{1,2}, Roman Makarewicz^{1,2}, Joanna Terlikiewicz^{1,2},
 Anna Wronczewska², Renata Kabacińska^{1,2}, Anysja Zuchora²**

¹ Department of Oncology, Collegium Medicum, Nicolaus Copernicus University, Poland

² Department of Brachytherapy, Centre of Oncology, Bydgoszcz, Poland

The proceedings from the 3rd Congress of the Polish Society of Radiation Oncology. Technical, Biological, and Clinical Advances in Radiotherapy, 13–16 October 2004, Bydgoszcz.

Background	Summary
Aim	HDR brachytherapy has been employed in the treatment of cancers in numerous locations around the body, however, few publications have dealt with primary carcinomas of the head and neck. To our knowledge, only one paper concerns the use of this technique in the treatment of cancers of the lower lip. Furthermore, the recommendations given by the American Association of Brachytherapy do not appear to elaborate on the subject.
Materials/Methods	To analyse the treatment of lower lip carcinoma by interstitial HDR brachytherapy. Retrospective analysis of the results of treatment was carried out among a group of 24 consecutive patients, of whom 18 were treated by brachytherapy alone while 6 others were treated after surgery. Fifteen patients were classified as T ₁ , nine patients as T ₂ . 23 patients were classified as N ₀ and one as N ₁ . Each patient had histologically confirmed squamous cell carcinoma. Radiotherapy involved interstitial, high dose rate brachytherapy with an iridium-192 source. Post-operative brachytherapy was indicated in cases of microscopically incomplete excision. The dose was determined using the Paris method, the reference dose being 80% or at a point 3–5 mm from the macroscopic lesion or tumour bed. The mean total dose was 35 Gy, the mean number of fractions was 7, and the mean fraction dose was 5.7 Gy. The total treatment time was 12 days, on average, whereas the mean follow-up was 32 months.
Results	Local control was obtained after 24 months in 21 patients (87.5%). All patients developed a severe early reaction. Three patients with mouth corner infiltration (100%) failed to show complete regression. Two of these patients underwent additional irradiation to the residual lesion, resulting in cures. The third patient underwent successful surgical treatment. The cosmetic and functional effect was very good.
Conclusions	Interstitial HDR brachytherapy is an effective and safe method for the treatment of carcinoma in the lower lip.
Key words	brachytherapy • HDR • lower lip cancer
Full-text PDF:	http://www.rpor.pl/pdf.php?MAN=7840
Word count:	1241
Tables:	—
Figures:	7
References:	7
Author's address:	Andrzej Lebioda, The Centre of Oncology, Romanowskiej 2 Str., 85-796 Bydgoszcz, Poland, e-mail: lebiadaa@co.bydgoszcz.pl

BACKGROUND

HDR brachytherapy has been employed in the treatment of cancers in numerous locations around the body, however, few publications have dealt with primary carcinomas of the head and neck. To our knowledge, only one paper concerns the use of this technique in the treatment of cancers of the lower lip [1]. Furthermore, the recommendations given by the American Association of Brachytherapy do not appear to elaborate on the subject [2]. As the parameters for radiation therapy of squamous carcinomas of the lower lip have not been well-defined, we present the results of studies dedicated to the elucidation of this problem.

MATERIALS AND METHODS

In a retrospective study, we investigated the results of treatment in 24 consecutive cases, wherein patients underwent definitive treatment between January 1998 and December 2000. Exclusive brachytherapy was administered to 18 patients and the remaining 6 were treated after previous non-radical surgery. Fifteen patients were classified as T1 and nine as T2. 23 patients were classified as N0 and one as N1 (Figure 1). The corner of the mouth was infiltrated in three patients. The mean lesion dimensions were 1.7 cm (± 1.1 cm) X 1.2 cm (± 0.8 cm). Each patient had histologically confirmed squamous cell carcinoma. G3, G2 and G1 were found in 10, 5 and 9 patients, respectively. The average age of the patients was 65 years, ranging between 43 and 83 years. Of the 24 patients, 4 were women (16%) and 20 were men (84%). One patient also suffered from lung cancer while two had previous cancers of the larynx. One patient had suffered a cerebral stroke. According to recommendations, post-operative brachytherapy was indicated in the cases of microscopic non-radical surgical treatment, or where information was lacking regarding the features of the margin (three patients out of 6).

Radiation treatment involved interstitial, high dose rate brachytherapy with the use of an iridium-192 source. The dose was determined by the Paris method, the reference dose being 80% or at points 3–5 mm from the macroscopic lesion or tumour bed. Implantation was carried out under local anaesthesia (1% ligocaine along the predicted paths of the interstitial needles). The mean total dose was 35 Gy (range: 15–51 Gy), the mean number of fractions was 7 (range: 1–15), the mean fractional dose was 5.7 Gy (range: 3–15 Gy). The average number of needles was 2 (range:

1–5) (Figure 2). The duration of fractions did not exceed 3 minutes and was dependent on the volume of the implant, the number of needles and the activity of the source. Total treatment time was, on average, 12 days (range: 1–40 days) and the mean and median follow-up periods were 32 and 35 months respectively.

Local control was defined as being no evidence of the disease at 24 months and was the clinical end-point of our study.

RESULTS

Complete remission was achieved by the 24th month in 23 patients. In all cases, a severe acute reaction was observed, which initially manifested itself as erythema followed by epitheliolysis around the lesion (Figure 3). Similarly, the primary tumour was desquamated within 2–3 weeks after the completion of the treatment. Infiltration of the corner of the mouth involves the risk of topographical errors, observed in all three patients with this condition. A complete response was not achieved in two cases. The dose to the residual lesion in these cases was increased and control was obtained (Figure 4). The decision to apply additional irradiation was usually taken three weeks after the healing of severe reactions (regression of epitheliolysis) and involved the administration of a dose of 12 Gy in four fractions, carried out in the 4th week, leading to complete remission. The third patient was effectively treated surgically, with no serious late complications.

Late effects such as fibrosis, skin retraction, hypo- and hyper-pigmentation and ulceration were not observed. The cosmetic and functional results were very good (Figure 5). The only cosmetic defects were the loss of a small degree of tissue at the point of primary infiltration and telangiectasia, which developed in two patients. There were no complications, such as bleeding or infection, associated with implantation (Figure 6).

DISCUSSION

Lower lip carcinomas are effectively treated by surgery and irradiation. Treatment results, in the early stages of lower lip cancer, are good. More than 90% of cases achieve 3-year local control. However, the results are less satisfactory (23%) in cases of mandibular infiltration [3,4]. The results of brachytherapy treatment, primarily concerning the LDR method, have not been extensively published. Beauvois [5] reviewed a group

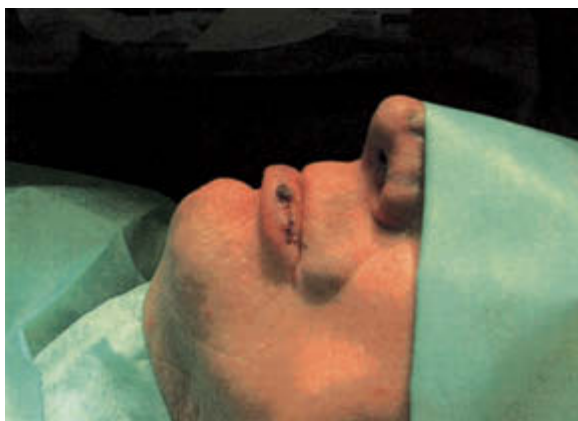

Figure 1. A typical T1N0M0 patient with squamous cancer of the lower lip.

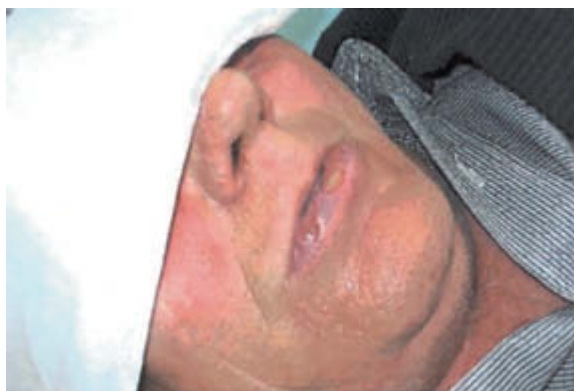

Figure 4. Extensive epitheliolysis of a tumour 14 days after the completion of treatment.

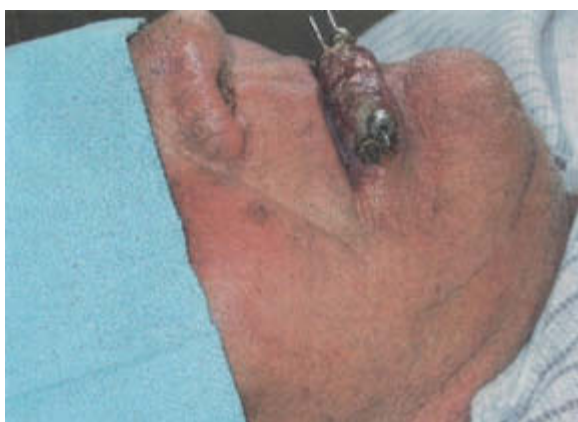

Figure 2. The plane of interstitial implants.

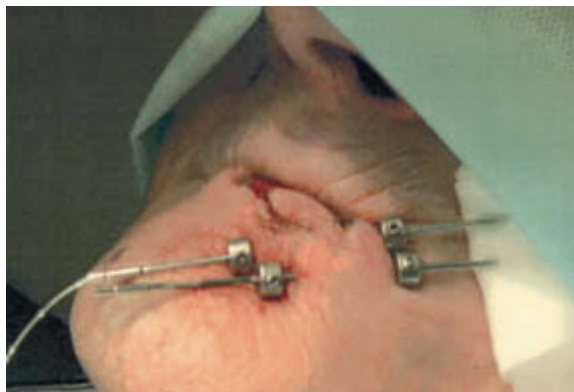

Figure 5. The implant covering the remaining infiltrate in the area below the corner of the mouth, the tumour pole above the corner has disappeared.

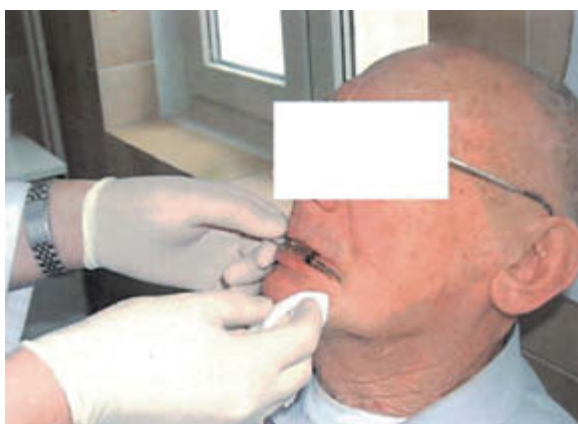

Figure 3. Control of the proper implant geometry between fractions (day 8).

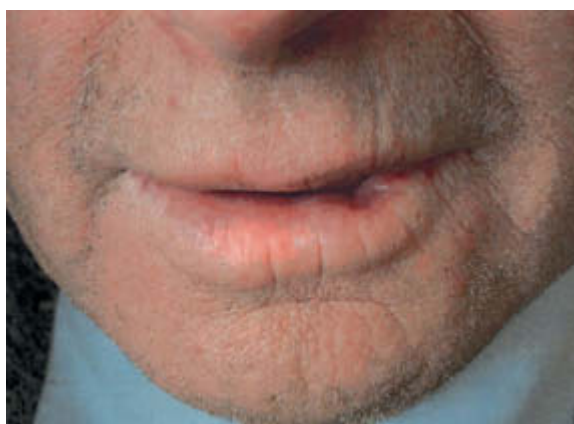

Figure 6. Effect of treatment after 24 months. Only a small loss of tissue at the primary tumour site is observed. No telangiectasia or fibrosis is detected.

of 237 patients, treated with the LDR technique in the period 1972–1991, in which local control was achieved in 95% of cases at 5 years and, by applying salvage surgery, this figure has now risen to as much as 99% of all cancer patients. The risk of late complications depended on the size

(thickness) of the area under treatment, the critical dimension being 1.4 cm. Tombolini [6] described a group of 57 patients in whom local control was achieved in 90% of cases at 3-years (up to 94% with salvage surgery) with very good functional and cosmetic effects. Similarly, Orecchia

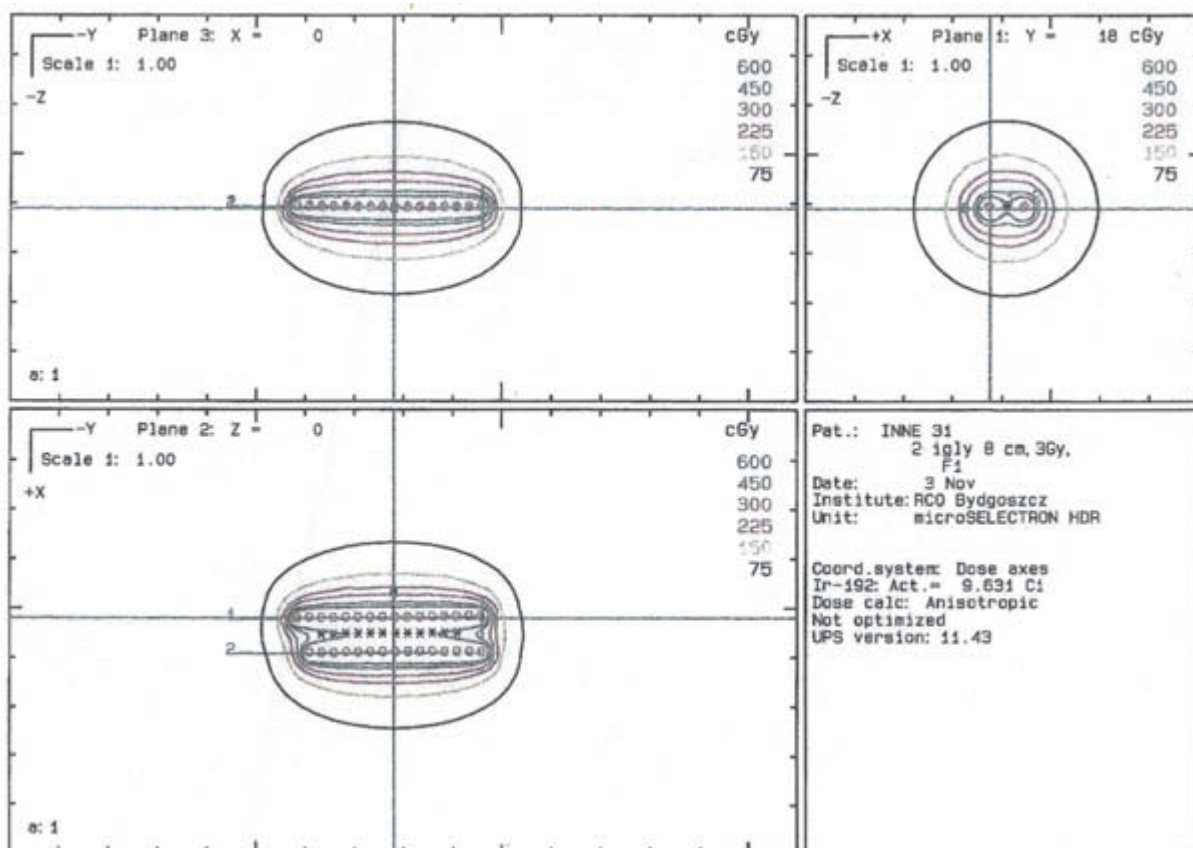


Figure 7. Coronal, sagittal and horizontal planes of isodose distribution for two needle implants.

[7] reported 93% local control in a group of 47 patients, and effective salvage surgery in two out of three failures. He also achieved an excellent cosmetic effect in 91% of all cases.

We have found only one paper reporting the interstitial HDR technique. The study, by Guinot [1], comprised a group of 39 patients, including 4 cases treated by previous surgery. He achieved 88% local control after 3-years in this group (21/21, 5/6 and 9/12 patients classified into disease stages of T_1 , T_2 , and T_4 , respectively). The following treatment plans were employed: 5.5 Gy \times 8 fractions, 5.3 Gy \times 8 fractions and 4.5 Gy \times 10 BID fractions. These treatment plans were different from those used in our department. We did not treat patients with T_3 or T_4 tumours. We started our therapy with a plan of 6 \times 6 Gy and weekly intervals. Very good tolerance of acute reactions permitted a reduction of the total treatment time. Also, in order to neutralize the potential threat of late complications, we lowered the fractional dose to 3 Gy, while at the same time increasing the total dose to 51 Gy, thereby compensating for the loss of radiobiological effectiveness. Doses were

administered once, twice or three times daily as necessary, so as to maintain the minimum 6-hour interval between the fractions over two weeks. As a rule, implants were applied two or three times, which, in our opinion, reduced the risk of underestimation of the dose. Guinot applied the implant only once and used, on average, three needles (maximum 9 needles), making it possible to employ a 90% reference isodose. In our case, an average of 2 needles and an 80% reference isodose were used (Figure 7). We observed inflammation of the mucous membranes, and ulceration, in all of our patients, but this was cured in a maximum of two months. No active bleeding or infections were noted. The implant did not affect the proper functioning of the lip or mouth.

CONCLUSIONS

1. Interstitial HDR brachytherapy is a safe and effective method for the treatment of carcinomas of the lower lip.
2. Mouth corner infiltration does not lend itself to interstitial treatment.

REFERENCES:

1. Guinot JL, Arribas L, Chust ML et al: Lip cancer treatment with high dose rate brachytherapy. *Radiother Oncol*, 2003; 69: 113–5
2. Nag S, Cano E, Demanes J et al: The American Brachytherapy Society: Recommendations for High Dose Rate brachytherapy for head and neck carcinoma. *Int J Radiat Oncol Biol Phys*, 2001; 50: 1190–8
3. A Lo Russo D, Agostini V, Frosini P: Carcinoma of the lip: a retrospective study of 86 cases. *Acta Otorhinolaryngol Ital*, 1991; 10: 447–51
4. Fongione S, Signor M, Beorchia A: Interstitial brachytherapy in carcinoma of the lip. Case histories and results. *Radiol Med (Torino)*, 1994; 88: 657–60
5. Beauvois S, Hoffstetter S, Peiffert D et al: Brachytherapy for lower lip epidermoid cancer: tumoral and treatment factors influencing recurrences and complications. *Radiother Oncol*, 1994; 33: 195–203
6. Tombolini V, Bonanni A, Valeriani M et al: Brachytherapy for squamous cell carcinoma of the lip. The experience of the Institute of Radiology of the University of Rome “La Sapienza”. *Tumori*, 1998; 84: 478–82
7. Orecchia R, Rampino M, Gribaudo S et al: Interstitial brachytherapy for carcinomas of the lower lip. Results of treatment. *Tumori*, 1991; 77: 336–8