

# ASSESSMENT OF EARLY TOXICITY OF CONCOMITANT RADIO-CHEMOTHERAPY IN THE TREATMENT OF LOCALLY ADVANCED CERVICAL CANCER

Andrzej Wieczorek<sup>1</sup>, Piotr Kędzierawski<sup>1</sup>, Jolanta Smok-Kalwat<sup>2</sup>,  
Paweł Banatkiewicz<sup>1</sup>

<sup>1</sup>The Holycross Cancer Centre in Kielce, Department of Radiotherapy and <sup>2</sup>Department of Clinical Oncology

Received July 6<sup>th</sup>, 2001; received in a revised form January 25<sup>th</sup>, 2002; accepted February 7<sup>th</sup>, 2002

## SUMMARY

**Introduction:** The aim of this paper was to assess early toxicity and feasibility of concomitant radio-chemotherapy in the treatment of locally advanced cervical cancer in daily routine clinical practise.

**Material and methods:** Between 1<sup>st</sup> of May 2000 and 15<sup>th</sup> of November 2000, twenty one patients suffering from stage IIB and IIIB (FIGO classification) cervical carcinoma were treated in the Radiotherapy Department of the Holycross Cancer Centre by concomitant radio-chemotherapy. Early toxicity of the skin, the lower gastrointestinal system and the genitourinary system was assessed according to acute radiation morbidity scoring criteria EORTC/RTOG. Leukopenia, thrombocytopenia, anemia, nausea, vomiting and nephrotoxicity were scored according to the WHO scale.

**Results:** There were no treatment-related deaths and no treatment breaks in radiotherapy due to acute toxicity. Only 48% of patients completed all 6 courses of cis-platin. The main causes of withdrawals from consecutive cycles of chemotherapy were: leucopenia - grade 2 or 3, thrombocytopenia - grade 3 and patient refusal. One patient developed acute renal failure. Other adverse effects did not exceed grade 2.

**Conclusions:** Concomitant radio-chemotherapy in the treatment of locally advanced cervical cancer was feasible and featured acceptable toxicity. Haematologic adverse effects were the main reasons of discontinued chemotherapy. Radiotherapy was well tolerated and all patients completed the whole course.

**Key words:** early toxicity, concomitant radio-chemotherapy, locally advanced cervical cancer.

## INTRODUCTION

Cervical cancer is the second most frequent cancer among women in Poland [1]. Despite screening programmes the rate of locally advanced stage patients is still high in our country, amounting to about 30% of all treated women. Concomitant radio-chemotherapy in the treatment of locally advanced cervical cancer was implemented in the Holycross Cancer Centre as a result of better outcome obtained in randomised III-phase trials published in 1999 [2,3,4,5,6]. The weekly intravenous infusion of cis-platin concomitant with radiotherapy was chosen because it proved to be less toxic than multiagent chemotherapy [2,7]. The aim

of this paper was to assess early toxicity and feasibility of this method of treatment in daily routine clinical practise.

## MATERIAL AND METHODS

Between 1<sup>st</sup> of May 2000 and 15<sup>th</sup> of November 2000 twenty one patients suffering from an advanced stage cervical carcinoma were treated in the Radiotherapy Department of the Holycross Cancer Centre with concomitant radio-chemotherapy. There were 12 IIB and 9 IIIB patients (FIGO classification). Qualification and stage assessment were made by a multidisciplinary team of physicians consisting of: a radiation oncologist, gynaecologist and clinical oncologist. In the first

phase of the treatment teloradiotherapy was combined with cis-platin 40 mg/m<sup>2</sup> administered intravenously on 1,8,15,22, 29,36 days of therapy. Chemotherapy was carried out along with standard adjunctive treatment (antiemetic prophylaxis and hydration with forced diuresis). Treatment with cis-platin was discontinued if the leucocyte count dropped below 3000 per cubic millimetre, or the platelet count dropped below 100 000 per cubic millimetre or creatinine level above 1.5 mg/dl. Teleradiotherapy was delivered with the standard four field isocentric box technique with 15-MV photons with patients lying prone. The pelvic field extended from the upper margin of L5 to the lower portion of the obturator foramen or the lowest level affected by the disease, with 3-cm margin, and laterally, 1.5-2 cm beyond the lateral margins of the bony pelvic wall. For the lateral fields, the anterior border was the midsymphysis of the pubic bone and the posterior border was the space between S2 and S3. Fractions of 1.8 Gy were delivered five days a week with a total dose of 50.4 Gy (calculated at a reference point according to ICRU 50). LDR/MDR (Cs-137) brachytherapy was performed in two or three intracavitary applications, 7 to 14 days after the completion of pelvic radiotherapy. The total dose was calculated at point A and varied from 25.31 Gy to 45.08 Gy, depending on the dose given to the organs at risk (bladder and rectum). The brachytherapy fractions were delivered in one a week intervals. Early toxicity of the skin, the lower gastrointestinal system and the genitourinary system was assessed according to acute radiation morbidity scoring criteria EORTC/RTOG. Leukopenia, thrombocytopenia, anaemia, nausea, vomiting and nephrotoxicity were scored according to the WHO scale.

## RESULTS

There were no treatment-related deaths and no treatment breaks in radiotherapy due to acute toxicity. Ten patients completed all 6 courses of cis-platin (48%), 4 patients received 5 cycles (19%), two patients had 4 cycles (9%), two patients had 3 cycles (9%), one patient had two

cycles (5%) and two patients received only one cycle (9%) (Fig. 1). The main causes of withdrawals from a consecutive cycles of chemotherapy were: leucopenia- grade 2 or 3 in 9 patients (42%) (Fig. 2), thrombocytopenia- grade 3 in 2 patients (10%) and patient's refusal of the next course of chemotherapy in 2 cases (10%). In 4 patients with leucopenia, growth factors were used after the 3<sup>rd</sup>, 4<sup>th</sup>, 5<sup>th</sup> and 6<sup>th</sup> course of cis-platin respectively. Anaemia grade 3 occurred in one patient (5%) but she had an episode of bleeding from the tumour during treatment which required blood transfusion. One patient developed acute renal failure after the 1<sup>st</sup> cycle of cis-platin, but she continued radiation without chemotherapy. Nausea and vomiting were observed, but they were grade 1 and did not effect the treatment breaks. The adverse effects in the gastrointestinal and genitourinary systems were grade 1 and 2 and were observed in 11 (51%) and 9 (42%) patients respectively. The early skin toxicity was grade 1 and was noticed only in two patients in the perineal region in women who had their field border below the obturator foramen.

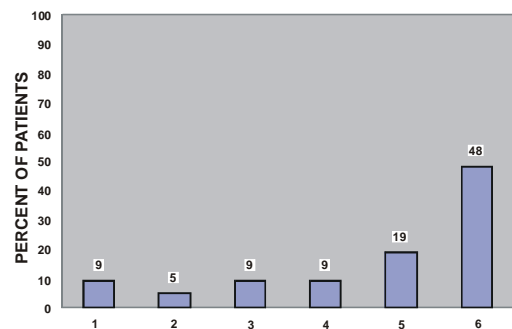


Fig. 1. Number of chemotherapy courses given to patients.

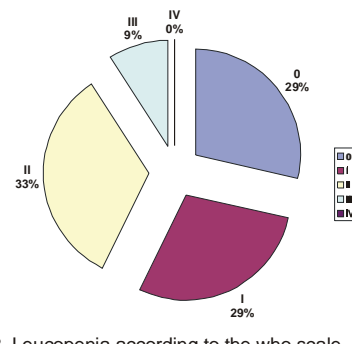


Fig. 2. Leucopenia according to the who scale.

## DISCUSSION

Combined radiotherapy and chemotherapy that include cisplatin improve the clinical outcome in women with locally advanced cervical cancer [2,3,4,5,6,7,8]. Also, the addition of cisplatin-based chemotherapy to adjuvant irradiation significantly improves the survival for high-risk, early stage patients who undergo radical hysterectomy and pelvic lymphadenectomy for carcinoma of the cervix [9]. Such an intensification of the treatment compared with the previously used standard radiotherapy carries a higher risk of severe toxicity which may question the feasibility of the combine treatment in the Polish population. In our group of patients we did not observe treatment-related deaths and all patients completed the whole course of radiotherapy. In a recently published series more than 90% of patients completed the whole course of irradiation [2,3,4,5,9]. Of 21 evaluated patients, 48% completed the whole six courses of cis-platin, which is similar to chemotherapy compliance reported in a randomised trial where the same chemotherapy regimen was used in an approximately same group of patients [2]. Only 76% of our patients completed four or more courses of chemotherapy, which is less successful than one of the published series where over 90% completed more than half of the chemotherapy [2,4], although we used growth factors in the treatment of the leucopenia in 4 of our patients in the second half of the treatment. We cannot find any reason to explain this fact, it may have happened because we were over-cautious and withheld cis-platin if the leukocyte and platelet count fell below the level higher than that used in a randomised setting [2]. Additionally, there were 10% of patients who refused to continue chemotherapy in the early stage of the treatment. The main reason of the discontinued chemotherapy and principal adverse effects was haematologic toxicity, mainly leucopenia grade 2 or higher, observed in 42% and in 49% of patients in our study and in the randomised study [2], respectively. Thrombocytopenia grade 2 or higher appeared less frequently and was observed in 9% of our

patients and 6% in the published study [2]. Using a similar regimen in the bulky stage IB, haematologic toxicity grade 2 or higher was observed in 57% of the patients [4]. The gastrointestinal (GI) and genitourinary (GU) grade 1 or 2 toxicity were observed in approximately half of our patients and did not cause any breaks of the treatment. In two randomised studies using the same cis-platin schedule, moderate GI toxicity was at the same level, the only difference was in the occurrence of life-threatening grade 3 and 4 in about 10% of all patients [2,4], which was not observed in our patients. The explanation of this fact may lie in the smaller average number of cis-platin courses received by our patients. The same cause may have led to the lack of severe GU toxicity in our study. The other toxicity was of a mild grade or, if severe, it appeared very rarely [2,4].

The cis-platin based concomitant radio-chemotherapy, despite enhanced toxicity, is feasible but about half of the patients failed to complete the whole course of treatment. Due to minor deviations from the treatment plan the use of growth factors in selective cases may have increased the rate of given cycles of the chemotherapy and lessened the haematologic toxicity. Another way to achieve this goal was to use a less intensive chemotherapy with the same survival benefit and less toxicity. In recently published preliminary results of a randomised trial using concomitant treatment with mitomycin C showed therapeutic enhancement compared with radiotherapy alone accompanied by very mild haematologic toxicity and no excess in the non-haematologic adverse effects [10].

## CONCLUSIONS

Concomitant radio-chemotherapy in the treatment of locally advanced cervical cancer was feasible and led to acceptable toxicity. Haematologic adverse effects constituted the main reasons of discontinued chemotherapy. Radiotherapy was well tolerated and all patients completed the whole course. Early toxicity presented in this paper was basically similar to the results published by other authors. It is necessary to continue

observation of the patients in order to assess late toxicity and long-term results of combined radio-chemotherapy treatment.

## REFERENCES

1. Zatoński W, Tyczyński J. Nowotwory złośliwe w Polsce w 1996. Centrum Onkologii Warszawa 1999.
2. Rose PG, Bundy BN, Watkins EB, Thigpen JT, Deppe G, Maiman MA, et al. Concurrent cisplatinbased radiotherapy and chemotherapy for locally advanced cervical Cancer. *N Engl J Med* 1999;15:1144-53.
3. Morris M, Eifel PJ, Lu J, Grigsby PW, Levenback C, Stevens RE, et al. Pelvic radiation with concurrent chemotherapy compared with pelvic and para-aortic radiation for high-risk cervical cancer. *N Engl J Med* 1999;15:1137-43.
4. Keys HM, Bundy BN, Stehman FB, Muderspach LI, Chafe WE, Suggs CL, et al. Cisplatin, radiation, and adjuvant hysterectomy compared with radiation and adjuvant hysterectomy for bulky stage IB cervical carcinoma. *N Engl J Med* 1999;15:1154-61.
5. Whitney CW, Sause W, Bundy BN, Malfetano JH, Hannigan EV, Fowler WC Jr, et al. Randomized comparison of fluorouracil plus cisplatin versus hydroxyurea as an adjunct to radiation therapy in stage IIB-IVA carcinoma of the cervix with negative para-aortic lymph nodes: a Gynecologic Oncology Group and Southwest Oncology Group study. *J Clin Oncol* 1999;5:1339-48.
6. Thomas GM. Improved treatment for cervical cancer- concurrent chemotherapy and radiotherapy. *N Engl J Med* 1999;15:1198-200.
7. Jassem J. Postępy w skojarzonym leczeniu nowotworów z udziałem radioterapii i chemioterapii. *Nowotwory* 2000;1:12-20.
8. Rose PG, Lappas PT. Analysis of the cost effectiveness of concurrent cisplatin-based chemoradiation in cervical cancer: implications from five randomised trials. *Gynecol Oncol* 2000;1:3-6.
9. Peters III WA, Liu PY, Barrett II RJ, Stock RJ, Monk BJ, Berek JS, et al. Concurrent chemotherapy and pelvic radiation therapy compared with pelvic radiation therapy alone as adjuvant therapy after radical surgery in high-risk early-stage cancer of the cervix. *J Clin Oncol* 2000;8:1606-13.
10. Roberts KB, Urdaneta N, Vera R, Gutierrez E, Aguilar Y, Ott S, et al. Interim results of a randomised trial of mitomycin C as an adjunct to radical radiotherapy in the treatment of locally advanced squamous-cell carcinoma of the cervix. *Int J Cancer* 2000;4:206-23.