

Supplementary material

Dyrbuś M, Pyka Ł, Kurek A, et al. Stroke after implantable cardioverter-defibrillator shocks in patients with heart failure. Kardiol Pol. 2024.

Please note that the journal is not responsible for the scientific accuracy or functionality of any supplementary material submitted by the authors. Any queries (except missing content) should be directed to the corresponding author of the article.

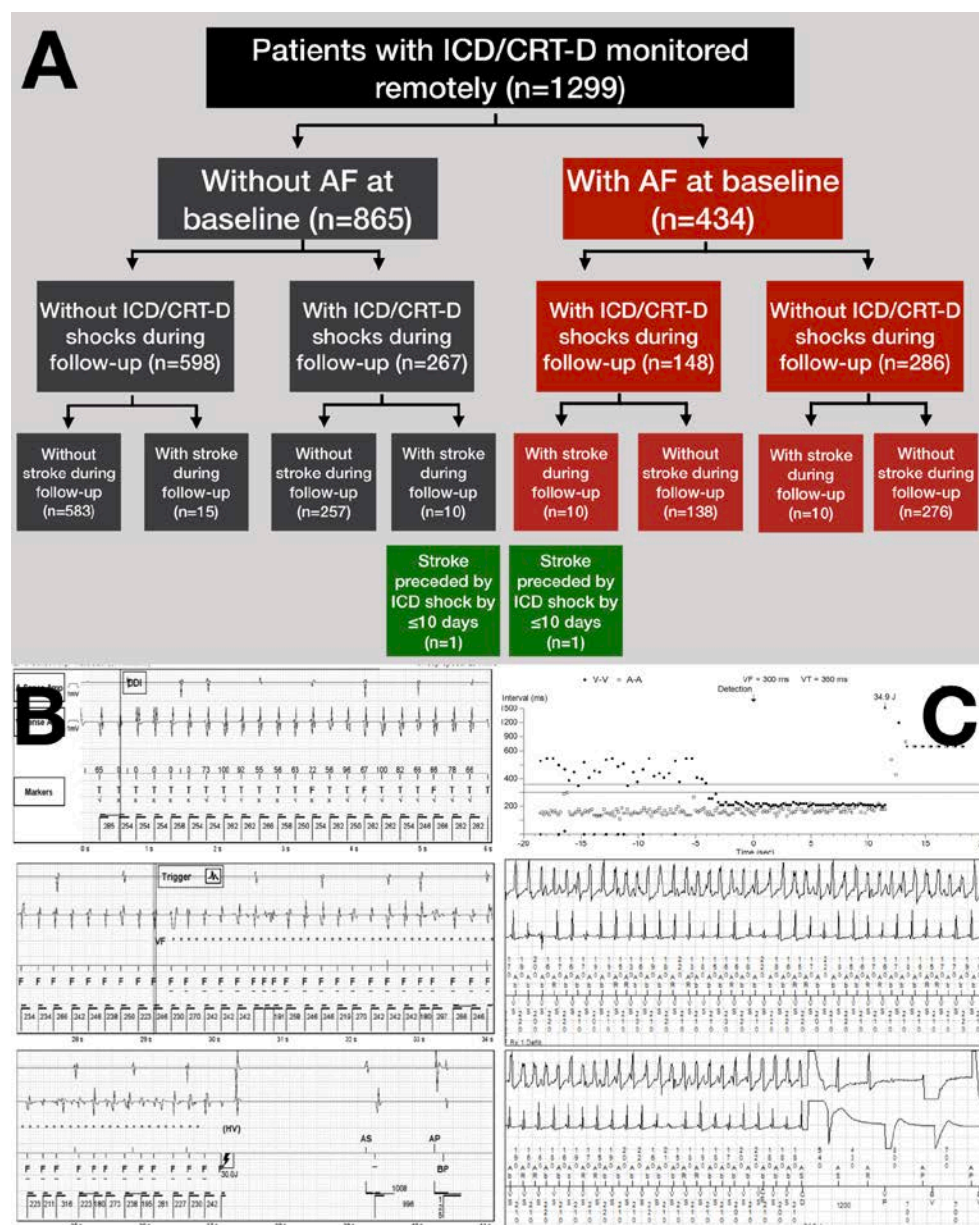


Figure S1. A. Flowchart presenting the analysed population. There were total of 45 strokes during follow-up, of which 25 occurred in patients without AF, and 20 in patients with AF. **B.** The intracardiac electrogram presenting onset of ventricular tachycardia, and an appropriate

high-voltage therapy, which was followed by stroke by less than 24 hours in a patient without AF. C. The intracardiac electrogram presenting an appropriate therapy for VF in a patient with paroxysmal AF, which was followed by stroke by less than 24 hours

Abbreviations: AF, atrial fibrillation; CRT-D, cardiac resynchronization therapy with defibrillator; ICD, implantable cardioverter-defibrillator; VF, ventricular fibrillation