

Supplementary material

Krakowski G, Kuniewicz M, Kacprzyk M, et al. Catheter ablation of persistent ventricular tachycardia in a patient with Left Ventricular Assist Device (LVAD): Electrophysiological challenge. Kardiol Pol. 2023.

Please note that the journal is not responsible for the scientific accuracy or functionality of any supplementary material submitted by the authors. Any queries (except missing content) should be directed to the corresponding author of the article.

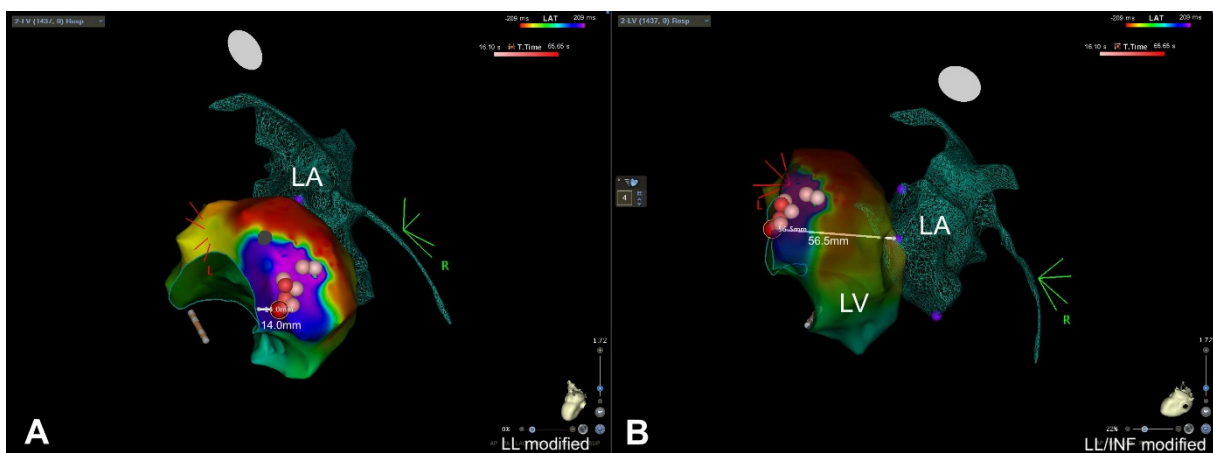


Figure S1. A. The distance between RF applications (red dots) to inflow cannula marked based on fluoroscopy control at the early stage of LV mapping process (LL modified view projection) **B.** The distance from RF points and mitral valve (LL/INF modified view projection)
Abbreviations: INF, inferior; LL, left lateral; LV, left ventricular; RF, radiofrequency