

Supplementary material

Kolakowski K, Jaworski K, Farkowski MM, Pytkowski M. A 3D transesophageal echo-facilitated diagnosis and cryoballoon ablation of paroxysmal atrial fibrillation in a patient with cor triatriatum sinister. Kardiol Pol. 2023.

Please note that the journal is not responsible for the scientific accuracy or functionality of any supplementary material submitted by the authors. Any queries (except missing content) should be directed to the corresponding author of the article.

Table S1. Details of the cryoballoon ablation

LSPV: 240 s with nadir temperature -53° C and an elective pull down maneuver at 65 s and bonus application of 120 s

LIPV: 240 s with nadir temperature -45° C after pull down maneuver

RIPV: 240 s with nadir temperature -48° C after pull down maneuver

RSPV: 180 s with nadir temperature -56° C

Abbreviations: CB, cryoballoon; LSPV, left superior pulmonary vein; LIPV, left inferior pulmonary vein; RIPV, right inferior pulmonary vein; RSPV, right superior pulmonary vein

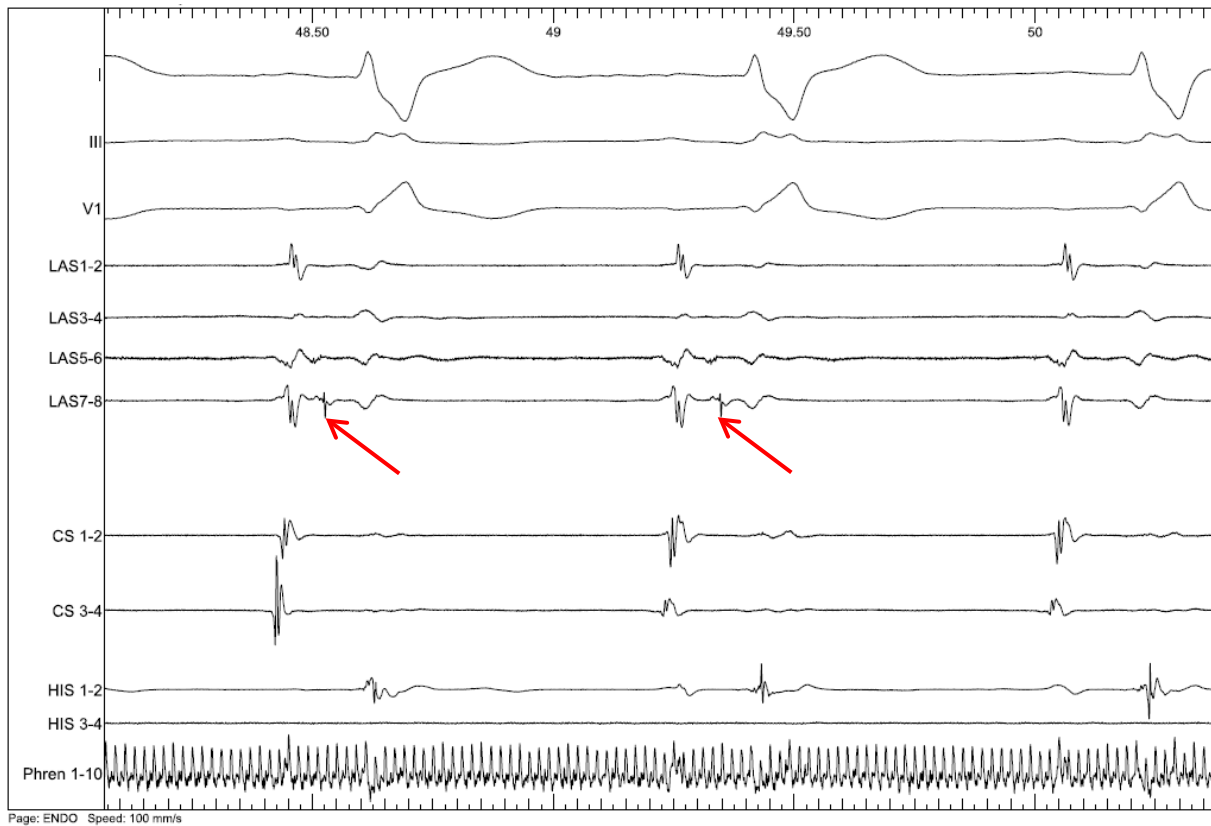


Figure S1. Isolation of the left superior pulmonary vein (arrow indicates pulmonary vein potential)

Video S1. A standard 2D TEE view of the left atrium membrane

Video S2. A 3D TEE view of the left atrium membrane with mitral valve leaflets in the background

Video S3. A 3D TEE view of the transeptal sheath and guide wire (foreground) over the left atrial membrane and mitral valve (background)