

Supplementary material

Legutko J, Kleczyński P, Guzik B, et al. Intracoronary and left ventricular thrombi in a 29-year-old COVID-19 convalescent with ST-segment elevation myocardial infarction. Kardiologia Pol. 2022.

Please note that the journal is not responsible for the scientific accuracy or functionality of any supplementary material submitted by the authors. Any queries (except missing content) should be directed to the corresponding author of the article.

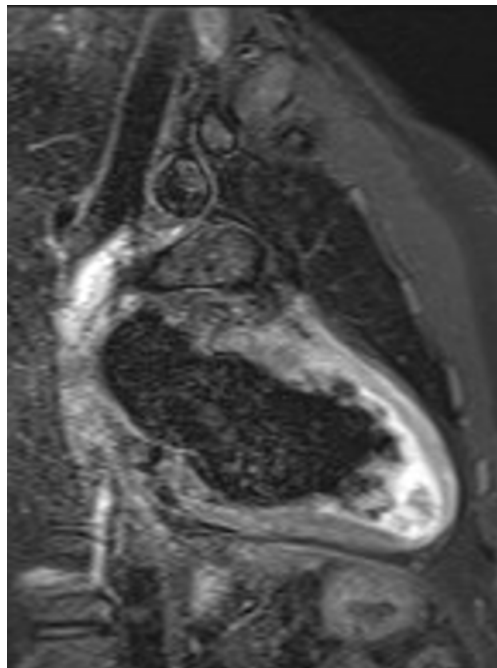


Figure S1.