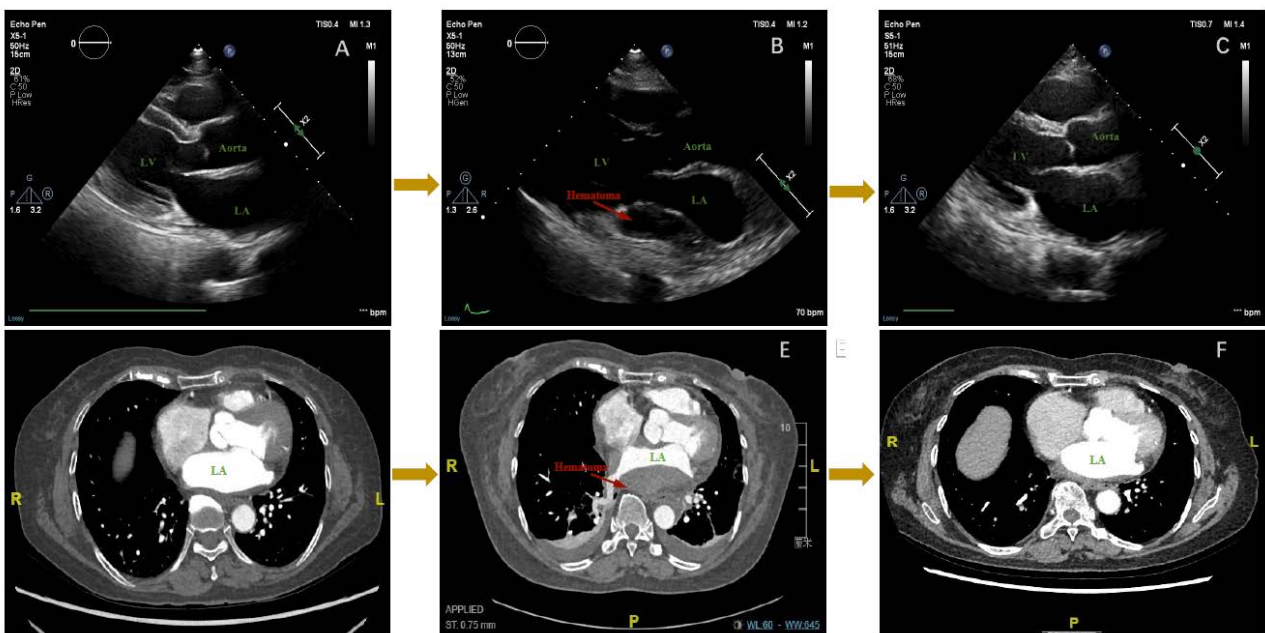


## Supplementary material

Deng Y, Li Q, Zhou F, et al. Intramural left atrial hematoma after transcatheter radiofrequency ablation of atrial fibrillation. *Kardiol Pol.* 2022.

Please note that the journal is not responsible for the scientific accuracy or functionality of any supplementary material submitted by the authors. Any queries (except missing content) should be directed to the corresponding author of the article.



**Figure S1.** **A.** The preoperative transthoracic echocardiographic image. **B.** The postoperative transthoracic echocardiographic parasternal long-axis view showed a hematoma (indicated by arrowhead) in the posterior wall of the left atrium. **C.** The transthoracic echocardiographic image one month after the ablation. **D.** The preoperative CTA of the left atrium. **E.** Postoperative CTA of the intramural hematoma (indicated by arrowhead). **F.** The CTA of left atrium two months after the ablation