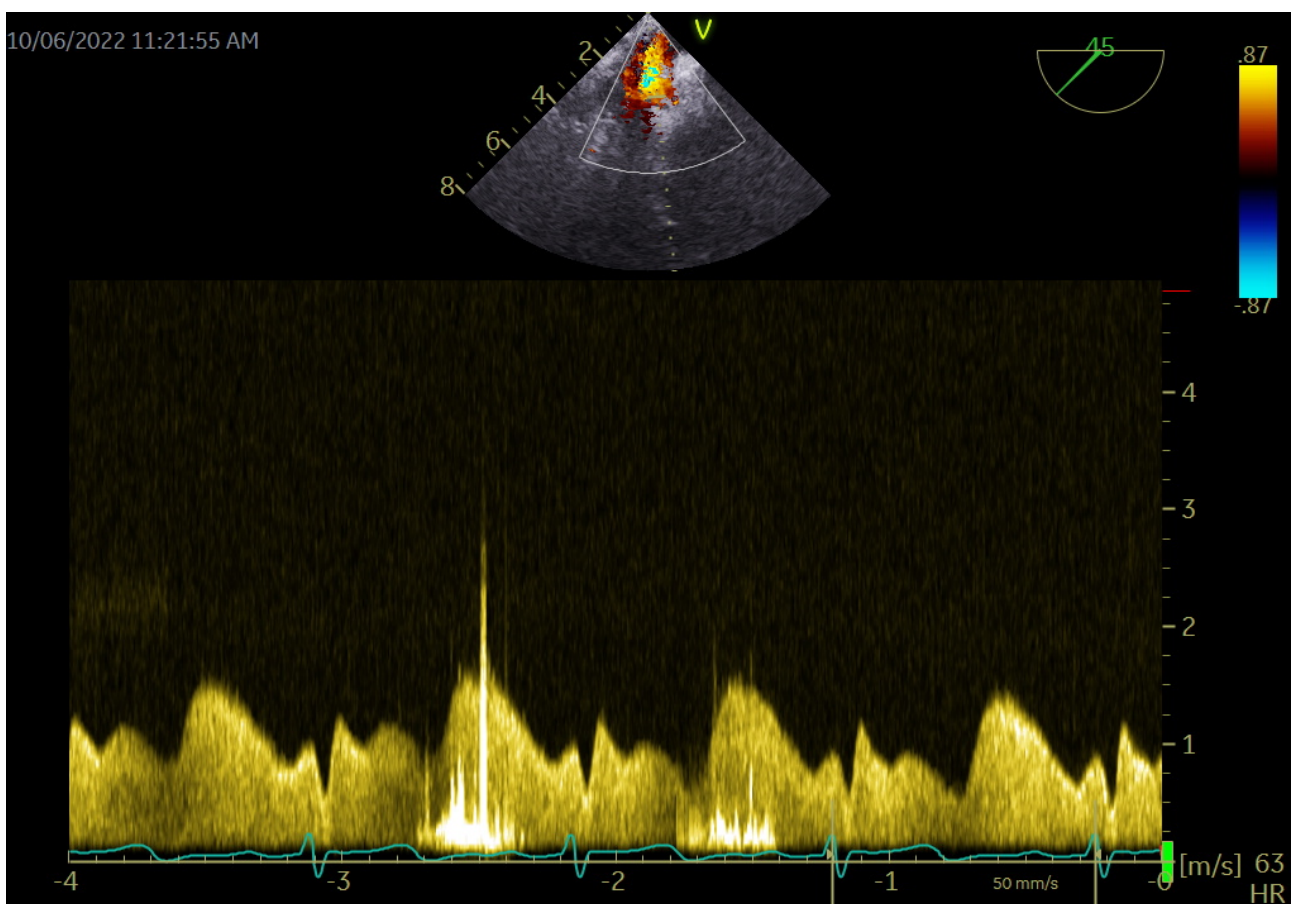


## Supplementary material

*Ślawiński G, Kochańska A, Fijałkowska J, et al. A rare but challenging iatrogenic complication after radiofrequency ablation of atrial fibrillation could be worse than the original disease: The role of multimodal imaging. Kardiol Pol. 2022.*

Please note that the journal is not responsible for the scientific accuracy or functionality of any supplementary material submitted by the authors. Any queries (except missing content) should be directed to the corresponding author of the article.



**Figure S1.** Significantly decreased flow velocity in CW in right upper pulmonary vein immediately after stenting procedure (TEE)