

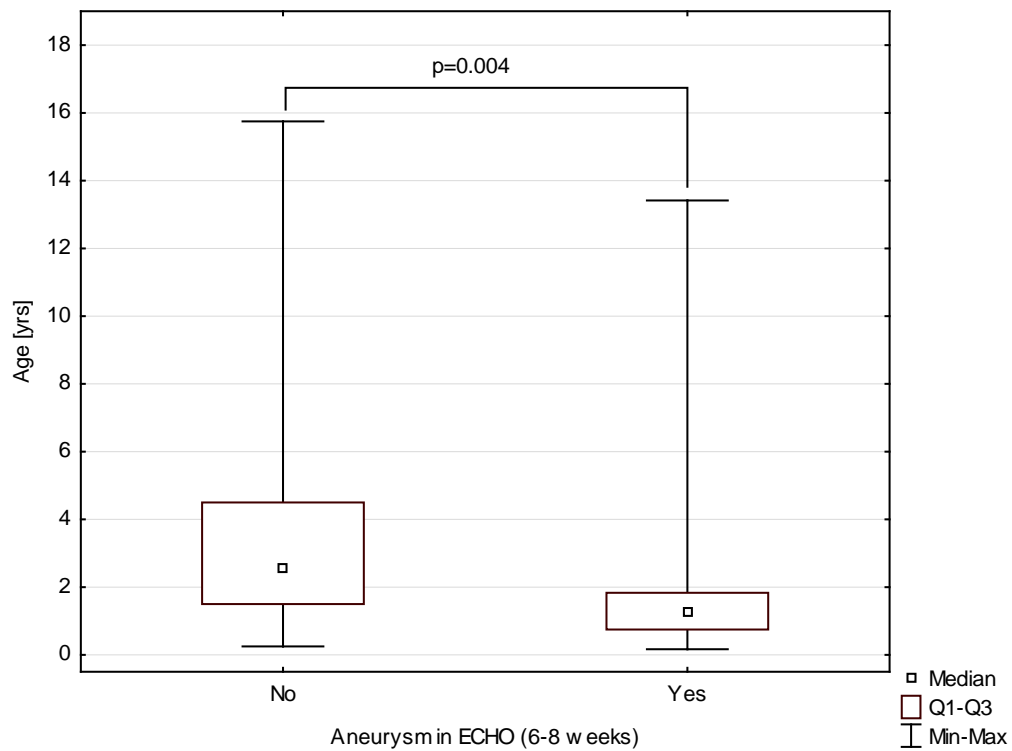
*Supplementary material*

---

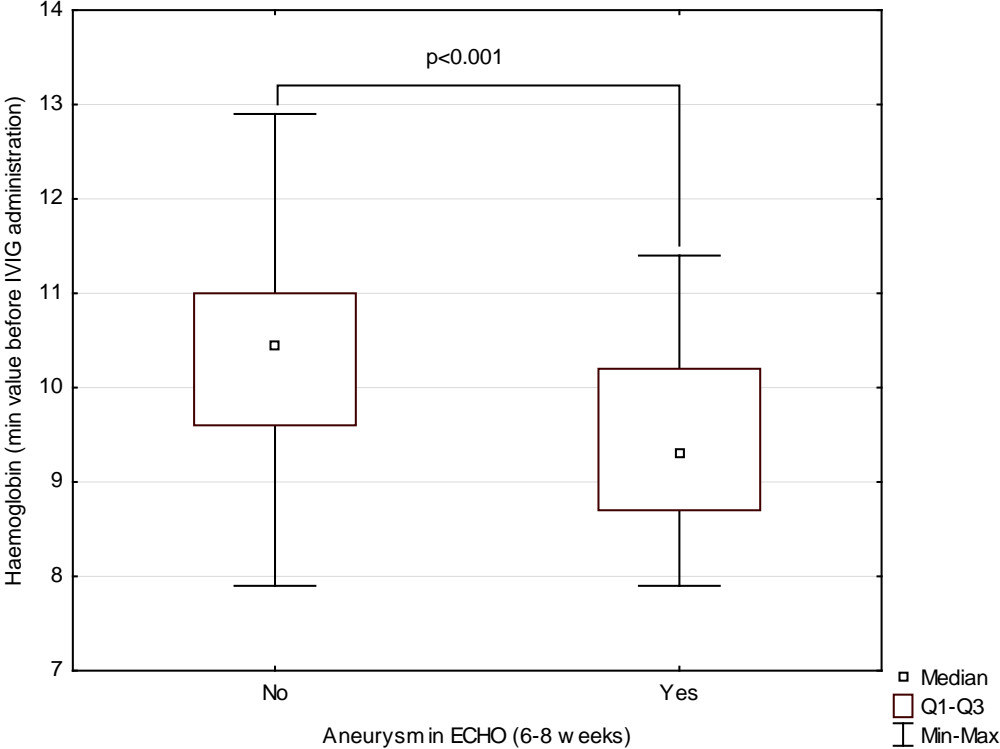
*Smorzewska-Kiljan A, Marszał M, Friedman-Gruszczyńska J, et al. Clinical characteristics of Kawasaki disease in Polish children: A retrospective study. Kardiol Pol. 2022.*

Please note that the journal is not responsible for the scientific accuracy or functionality of any supplementary material submitted by the authors. Any queries (except missing content) should be directed to the corresponding author of the article.

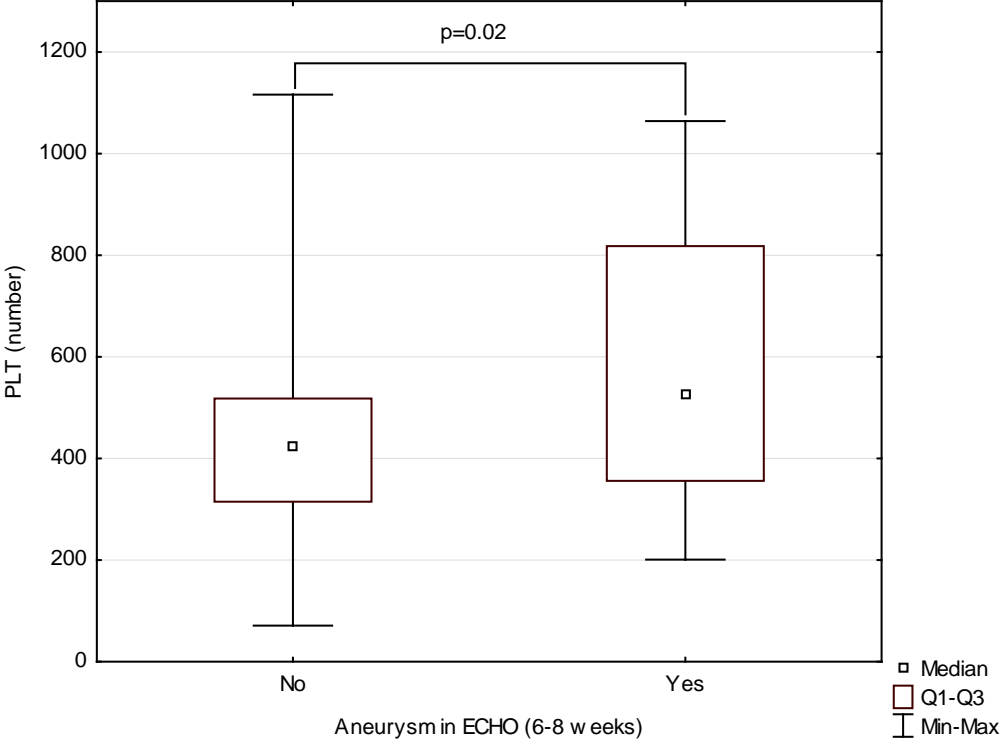
**Figure S1.** Coronary lesions (z-score >2.5) in 6-8 weeks by age



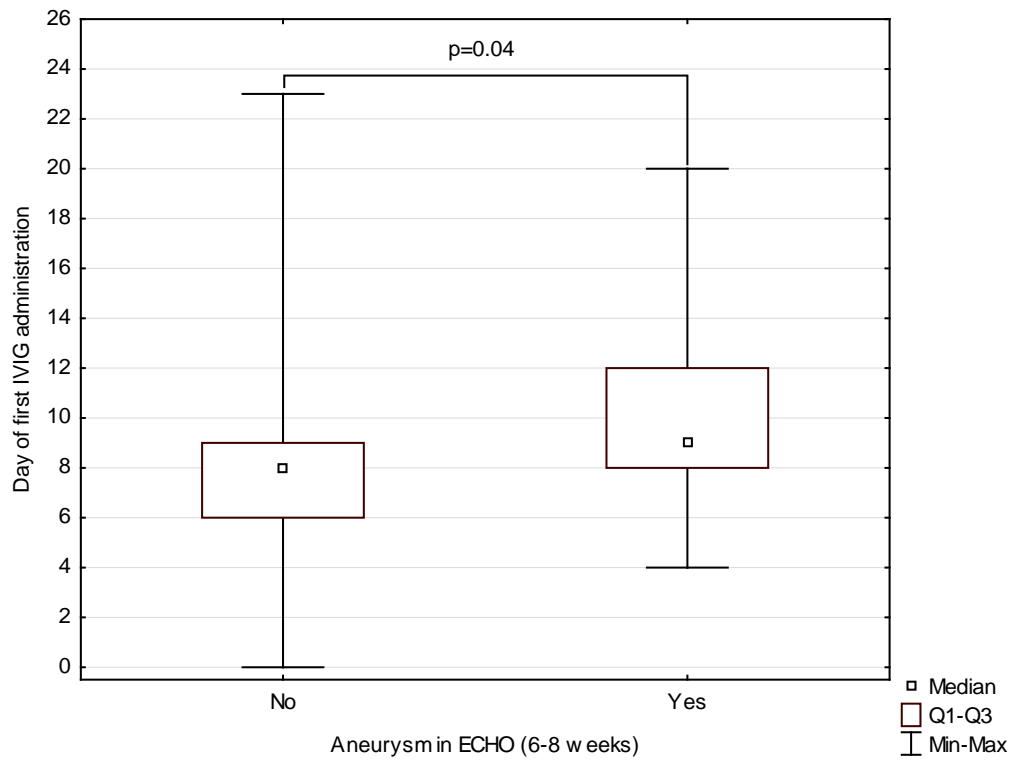
**Figure S2.** Coronary lesions (z-score >2.5) at 6–8 weeks by Hb value



**Figure S3.** Coronary lesions (z-score >2.5) at 6–8 weeks by PLT value



**Figure S4.** Coronary lesions (z-score >2.5) at 6–8 weeks by day of treatment



**Figure S5.** Coronary lesions (z-score >2.5) at 6–8 weeks by present of changes in ECHO at day of diagnosis

