

Pawlik A, Januszek R, Rzeszutko Ł, Bartuś S. Percutaneous coronary intervention combining rotational atherectomy and intravascular lithotripsy in two vessels with edge restenosis assisted by percutaneous left ventricular pump support. Kardiologia Polska. 2022.

Please note that the journal is not responsible for the scientific accuracy or functionality of any supplementary material submitted by the authors. Any queries (except missing content) should be directed to the corresponding author of the article.

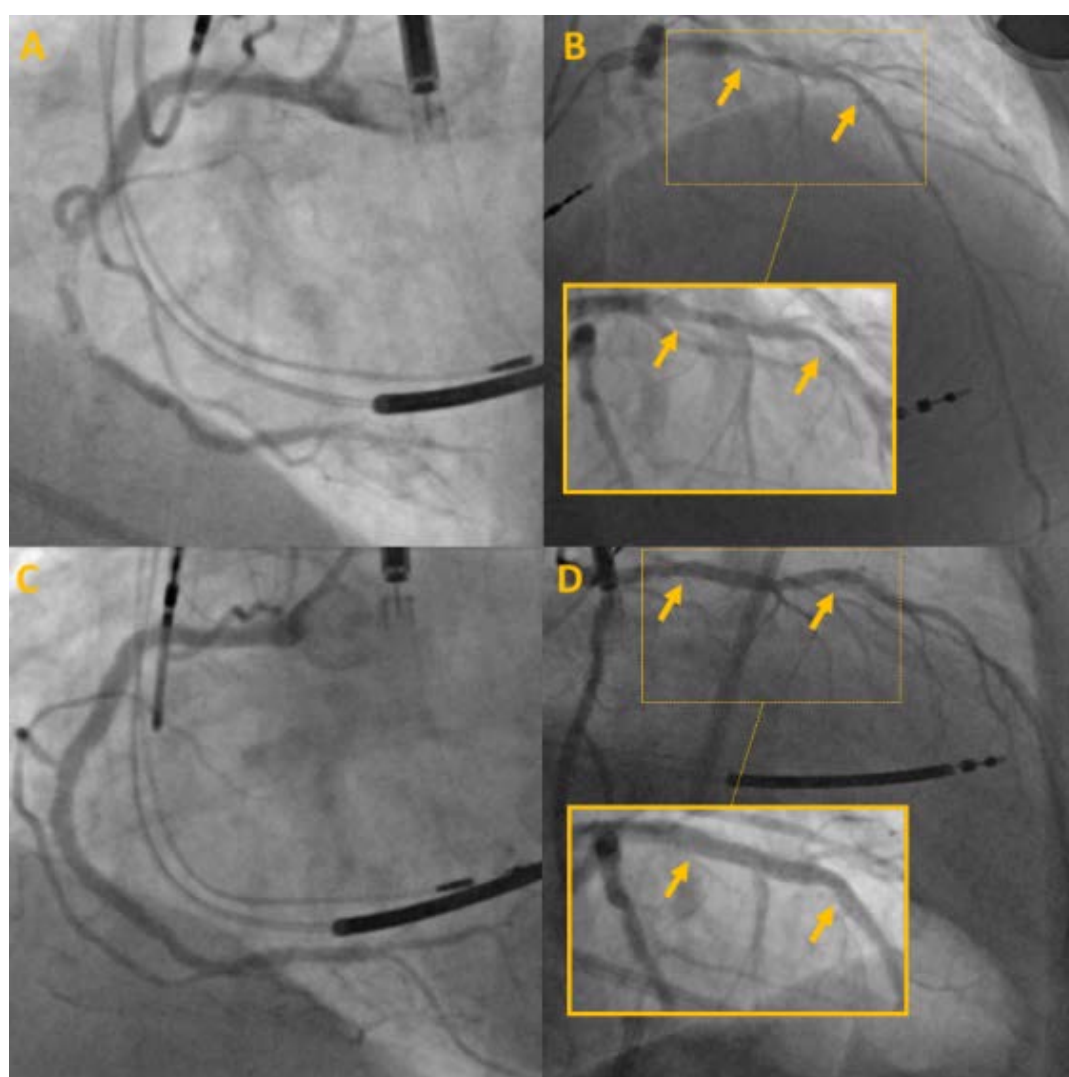


Figure S1. **A.** Critical stenoses in second and third segments of the RCA. **B.** Long calcified lesion expanding between proximal segment of the LAD to the proximal edge of previously implanted stent (arrows). **C.** Final result of PCI RCA. **D.** Final angiographic effect of PCI LAD with good stents expansion despite massive calcifications (arrows)