

## Supplementary material

*Cybulska M, Sajdok M, Bednarek J, et al. Stereotactic arrhythmia radioablation in recurrent ventricular tachyarrhythmias — do not miss the forest for the trees. Kardiol Pol. 2022.*

Please note that the journal is not responsible for the scientific accuracy or functionality of any supplementary material submitted by the authors. Any queries (except missing content) should be directed to the corresponding author of the article.

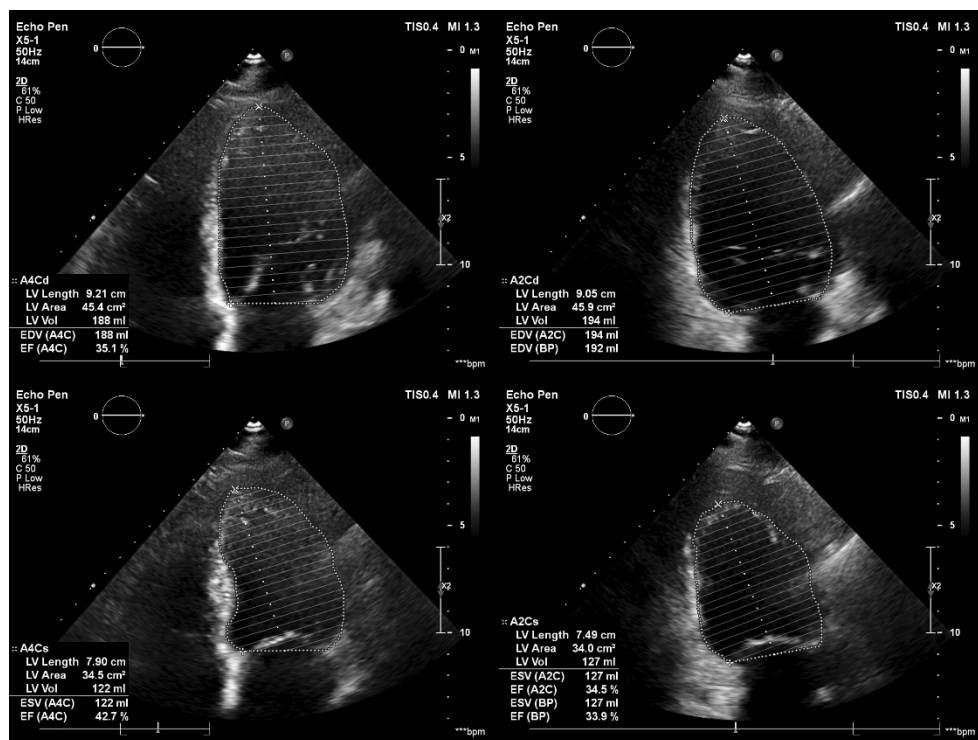
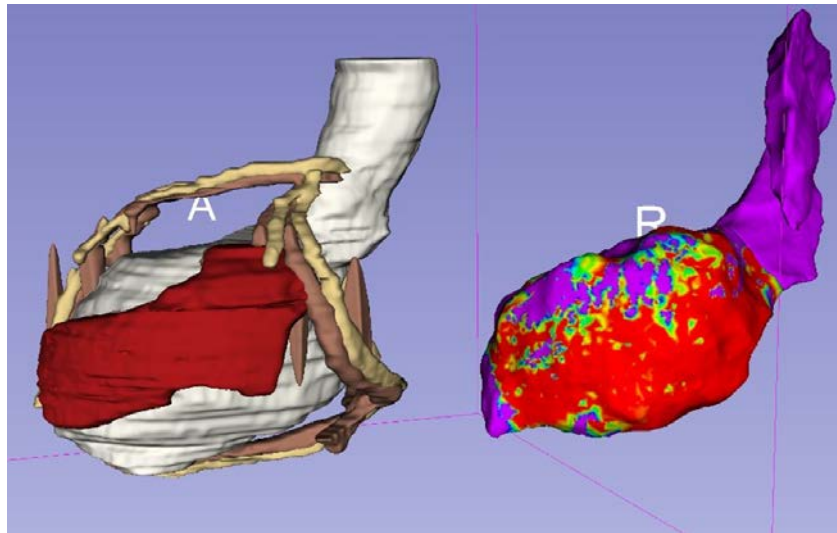
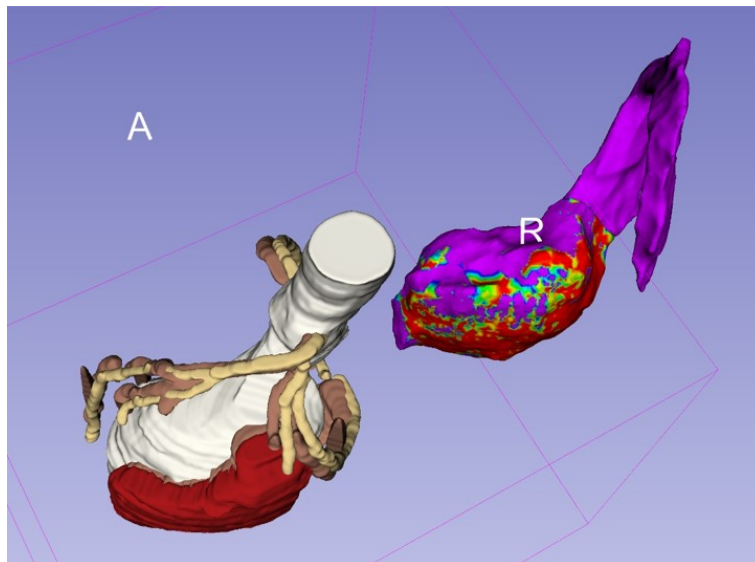


Figure S1. ECHO EF on admission



*Figure S2.* Fusion imaging CT \_ EPS



*Figure S3.* Fusion imaging CT \_ EPS

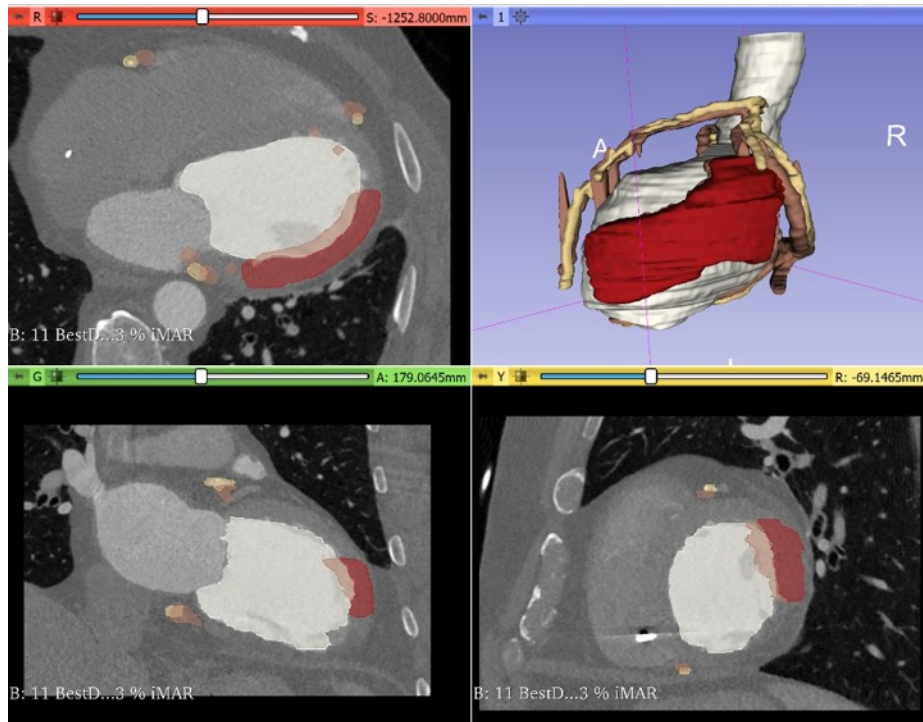


Figure S4.

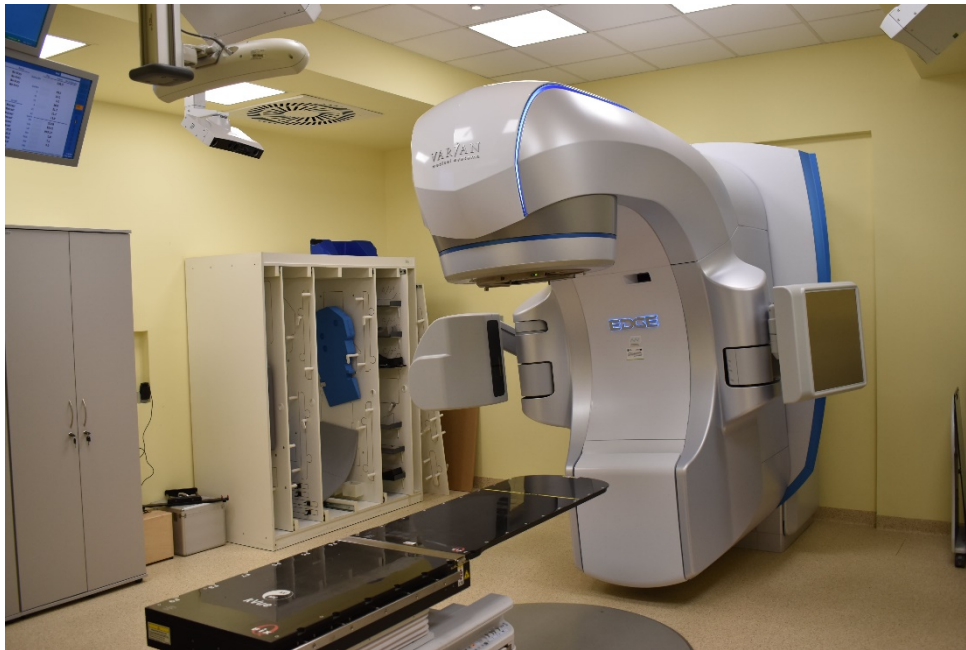

Figure S5. Varian Edge



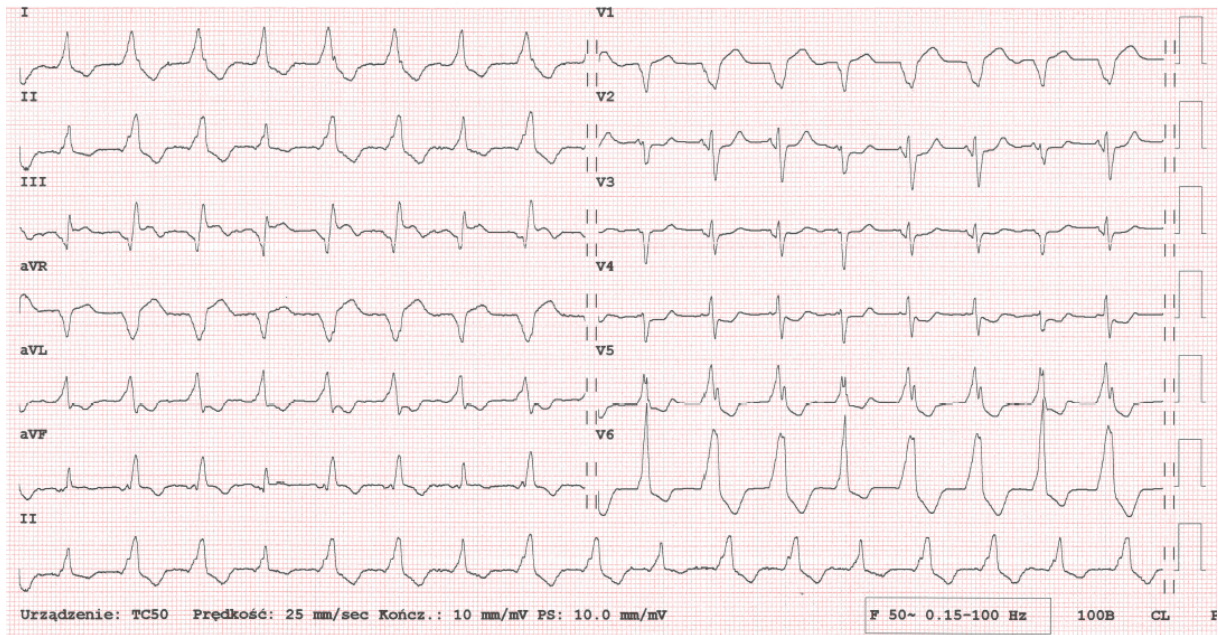


Figure S6. RVOT-VT

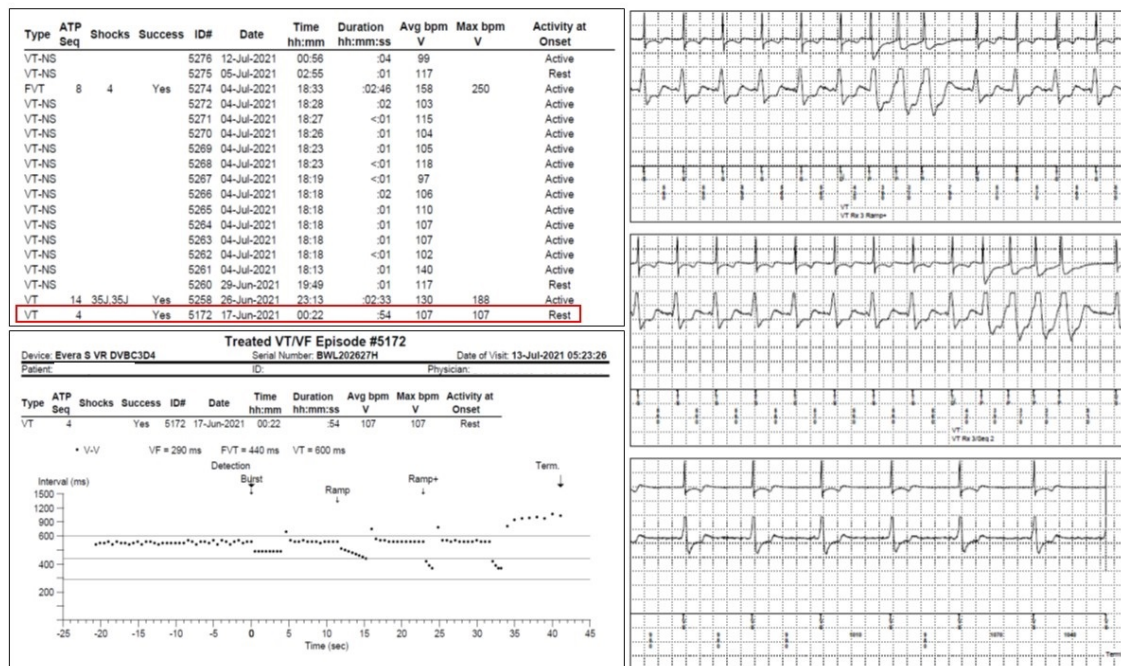


Figure S7. VT with successful ATP

**Treated VT/VF Episode #5170**

Device: Evera S VR DVBC3D4

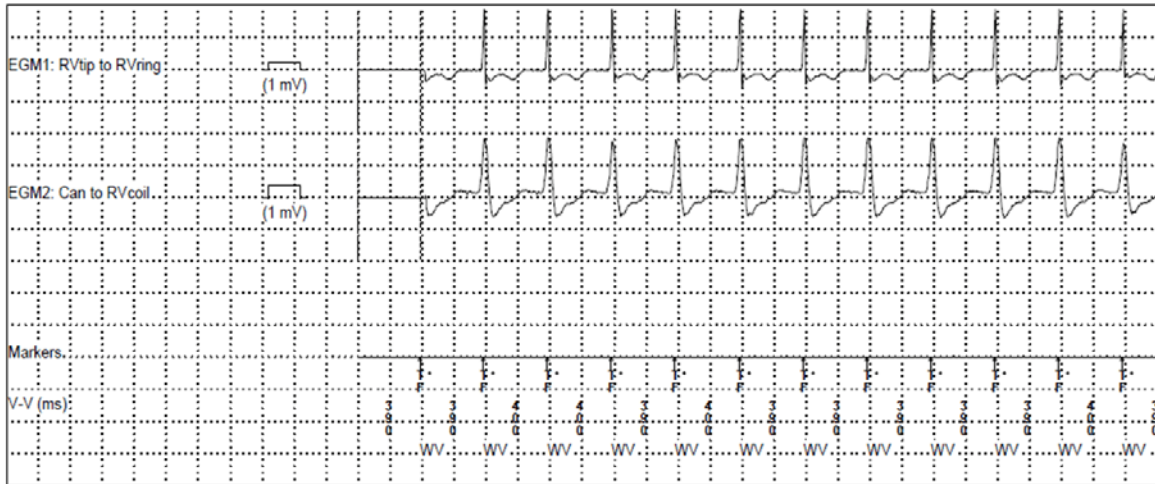Serial Number: BWL202627H

Date of Visit: 13-Jul-2021 05:23:26

Patient:

ID:

Episode #5170 - FVT Chart speed: 25.0 mm/sec



**Unsaved Frozen Strip**

Device: Evera S VR DVBC3D4

Serial Number: BWL202627H

Date of Visit: 16-Jul-2021 04:18:03

Patient:

ID:

Physician:

Collected: 16-Jul-2021 08:51:07

25.0 mm/sec

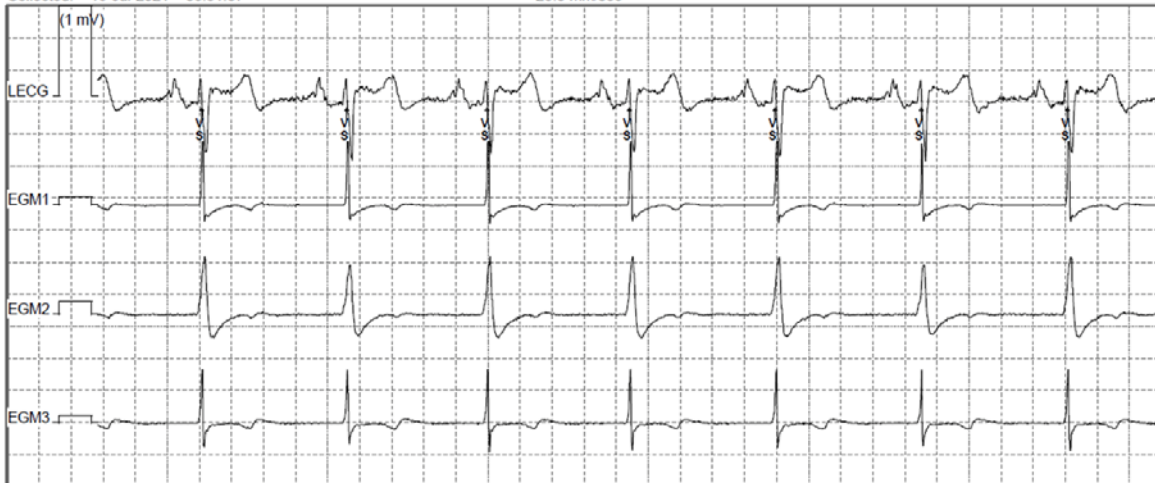

Figure S8. SVT and sinus morphology

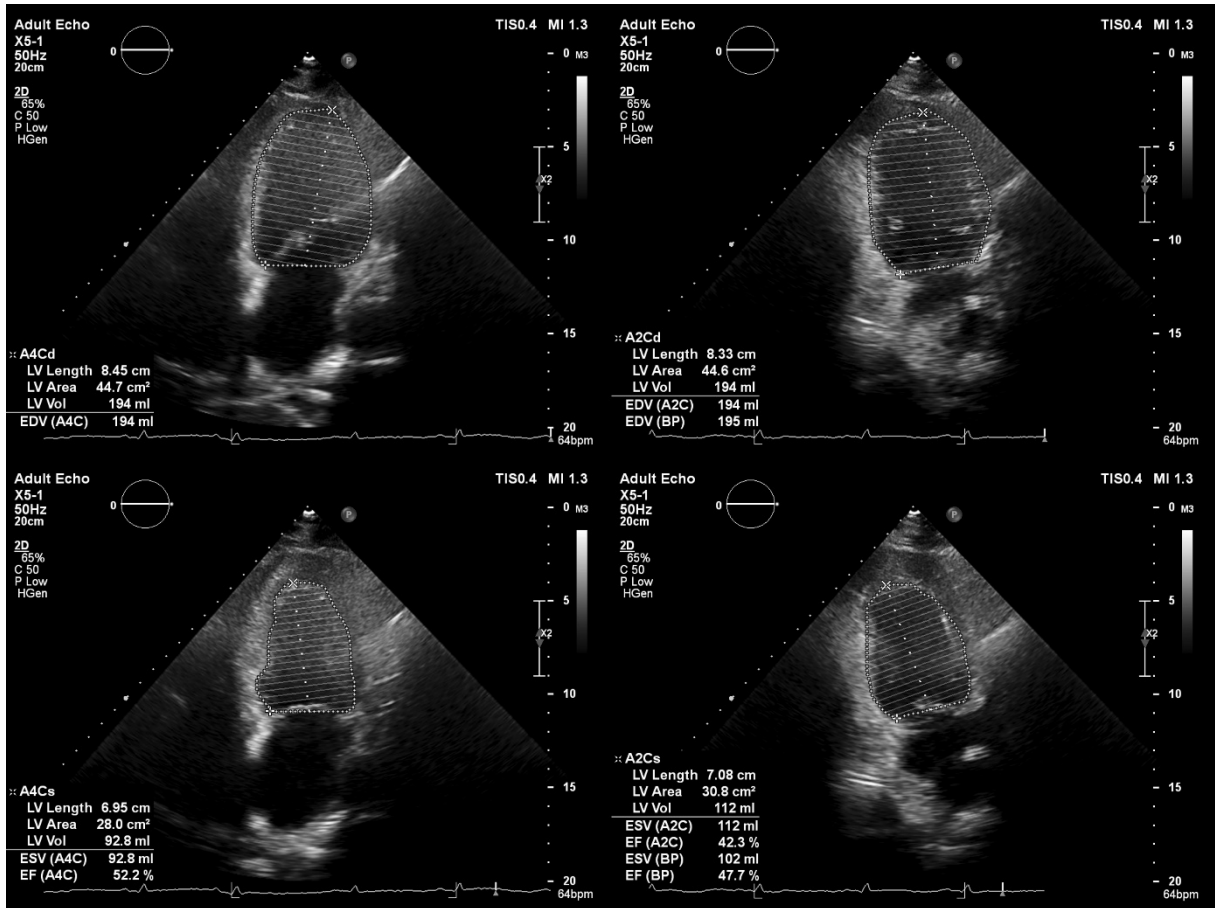


Figure S9. ECHO EF during follow up

Video S1. Rotational angiography

Video S2. EPS map