

Supplementary material

Li Q, Li L, Wan X, Chang D. Successful left bundle branch pacing in a patient with dextrocardia using a modified sheath. Kardiol Pol. 2021; 79: 87-88. doi:10.33963/KP.15700

Please note that the journal is not responsible for the scientific accuracy or functionality of any supplementary material submitted by the authors. Any queries (except missing content) should be directed to the corresponding author of the article.

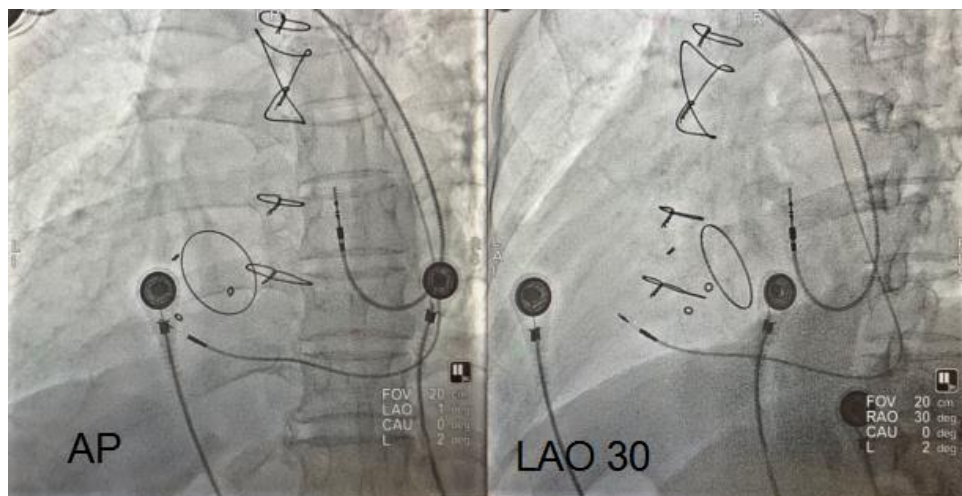


Figure S1. Fluoroscopy, AP- Anteroposterior, LAO-Left anterior oblique.

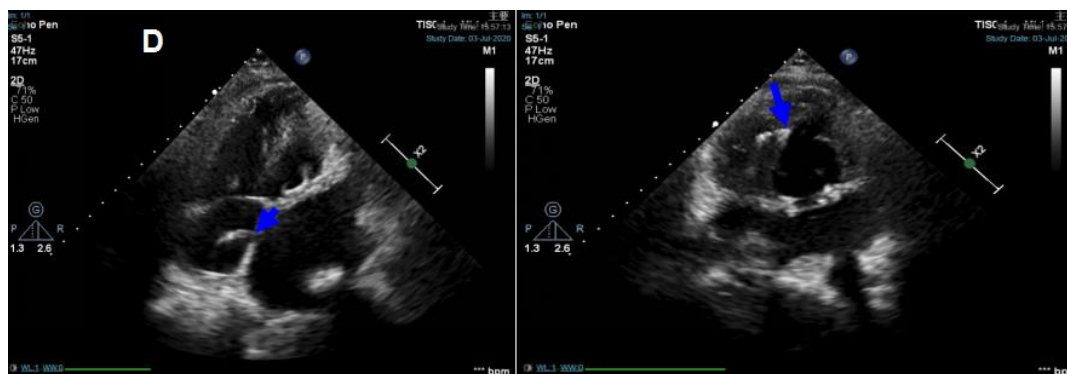


Figure S2. Image (left) showed the atrial lead in atrial septum (blue arrow), the arrow points to the tip of lead (type 5076, Medtronic Inc, Minneapolis, MN, USA). Image (right) showed the lead in left ventricular septal subendocardium (blue arrow), the arrow points to the tip of lead (type 3080, Medtronic Inc, Minneapolis, MN, USA).