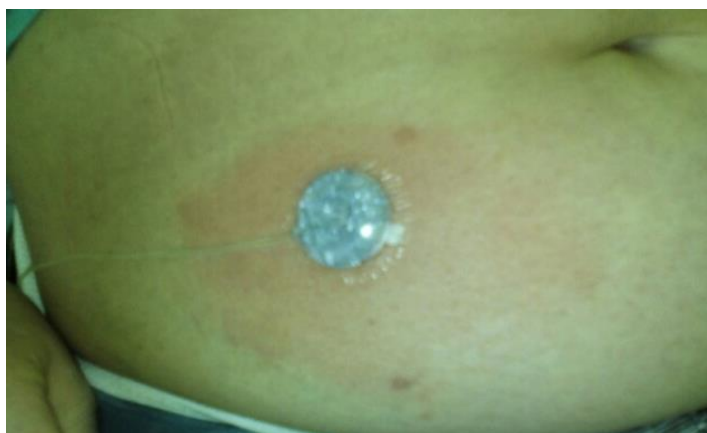

## Supplementary material

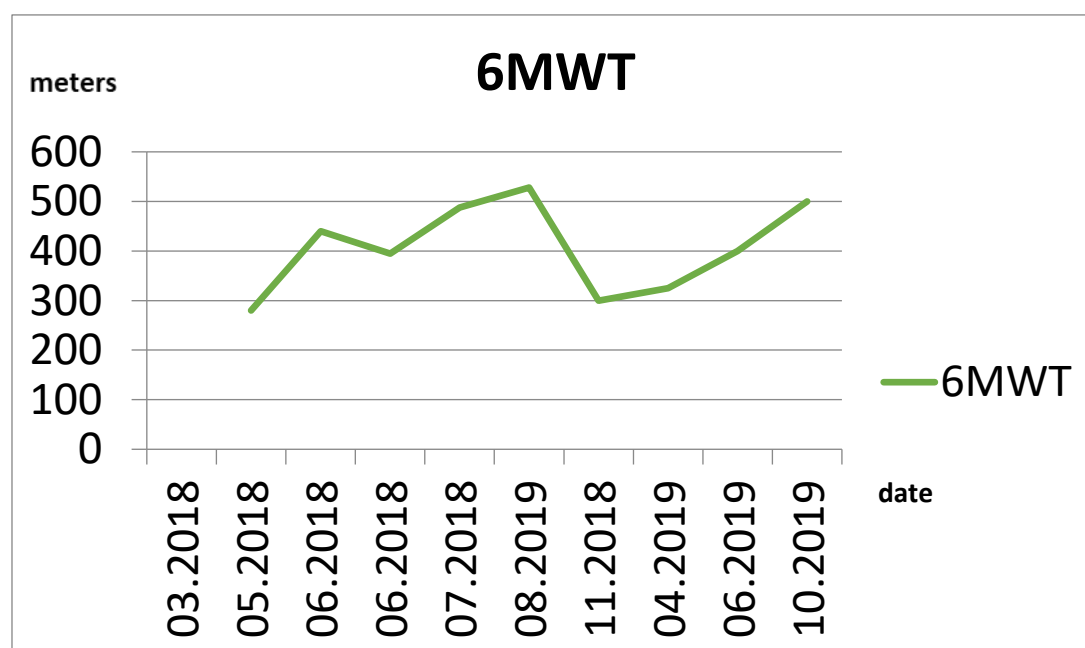
Zielska M, Lewandowski M, Widecka K, et al. Uncommon complication of pulmonary arterial hypertension treatment with the parenteral use of treprostinil. *Kardiol Pol.* 2021; 79: 79-80. doi:10.33963/KP.15672

Please note that the journal is not responsible for the scientific accuracy or functionality of any supplementary material submitted by the authors. Any queries (except missing content) should be directed to the corresponding author of the article.



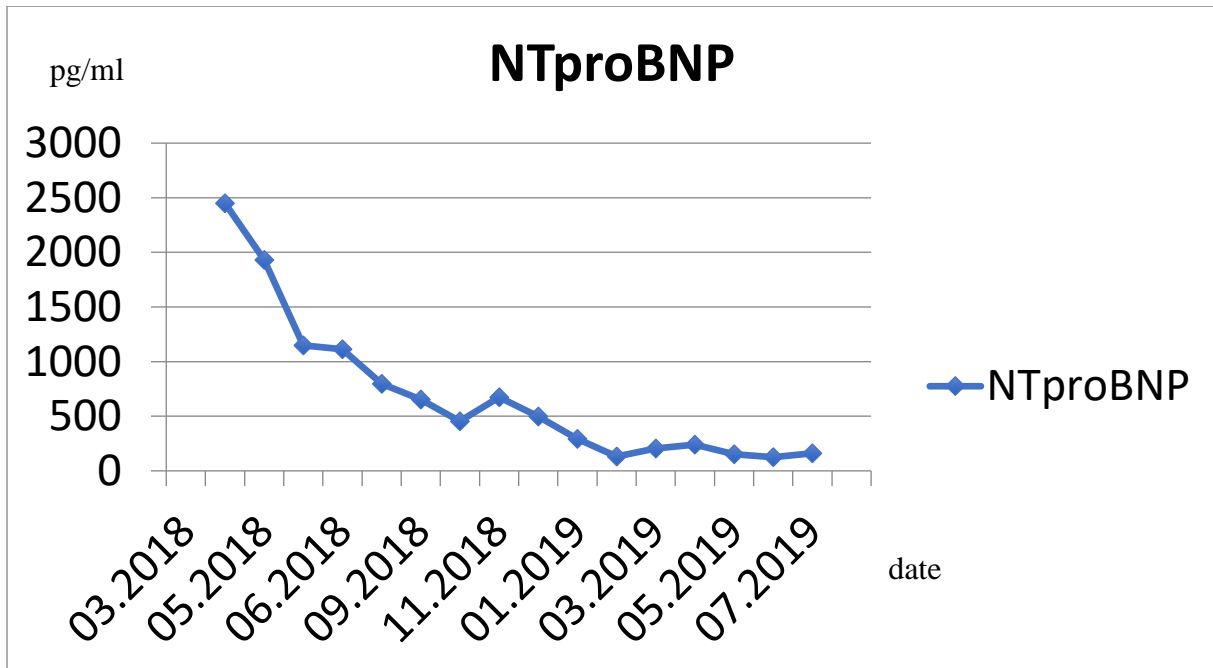
**Figure S1** Erythema on the abdomen around the injection site for treprostinil infusion

**Figure S2** Changes in the distance during 6-minute walk test (6MWT)



11.2018 implantation of the Lenus Pro pump

**Figure S3** Changes in the concentration of *N-terminal* pro-B-type natriuretic peptide (NT-proBNP)



11.2018 implantation of the Lenus Pro pump