

Supplementary material

Dziekiewicz M, Makowski K. Surgical approach to carotid sinus syndrome and carotid body tumor. *Kardiol Pol.* 2021; 79: 69-71. doi:10.33963/KP.15709

Please note that the journal is not responsible for the scientific accuracy or functionality of any supplementary material submitted by the authors. Any queries (except missing content) should be directed to the corresponding author of the article.

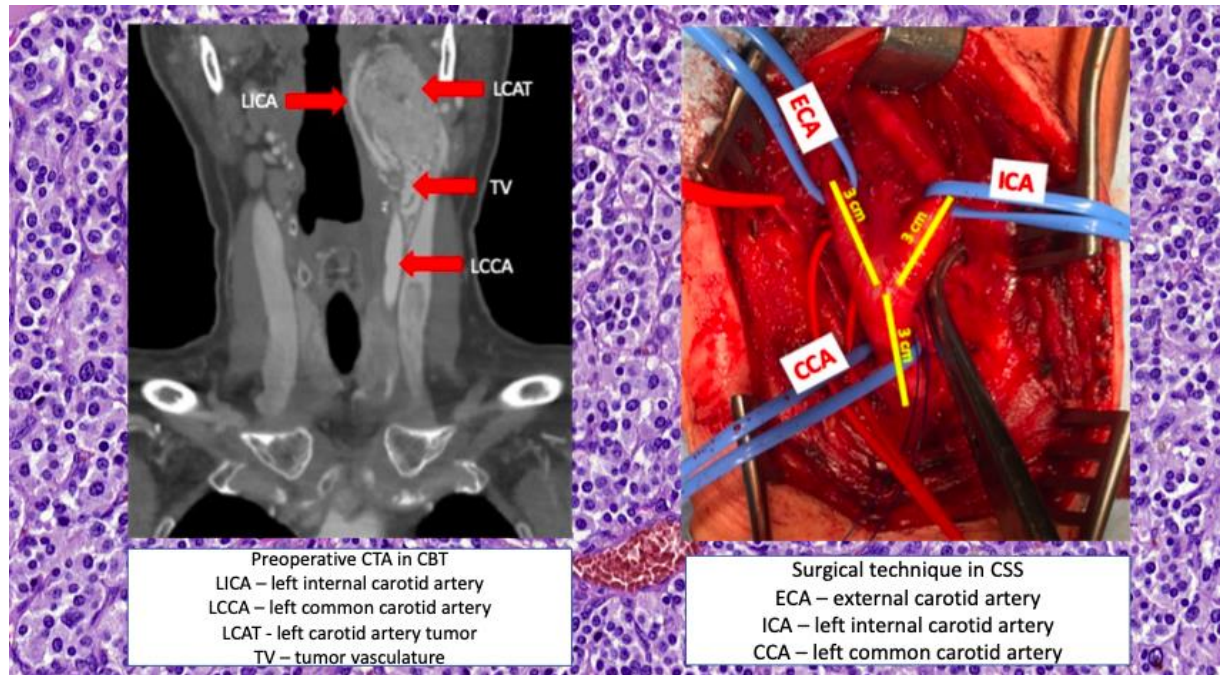


Figure S1. Surgical technique - own approach¹.

Abbreviations

LICA = left internal carotid artery

LCAT = left carotid artery tumor

TV = tumor vasculature

LCCA = left common carotid artery

TIA = thyroid ima artery (*in this case, the blood supply of the paraganglioma originated from the thyroid ima artery directly from the aortic arch, anastomosed with the inferior thyroid artery arising from the left external carotid artery).

¹ A total of 9 carotid denervation procedures were performed in the CSS “alone”. Three patients with symptoms of CSS accompanied by CBTs underwent simultaneous denervation of the carotid arteries and CBT excision. Sixteen patients underwent surgery because of a unilateral CBT.