

Supplementary material

Konishi T, Funayama N, Yamamoto T, et al. Acute anterior myocardial infarction complicated by takotsubo syndrome: the value of multimodality imaging. Kardiol Pol. 2020; 78: 1055-1056. doi:10.33963/KP.15492

Please note that the journal is not responsible for the scientific accuracy or functionality of any supplementary material submitted by the authors. Any queries (except missing content) should be directed to the corresponding author of the article.

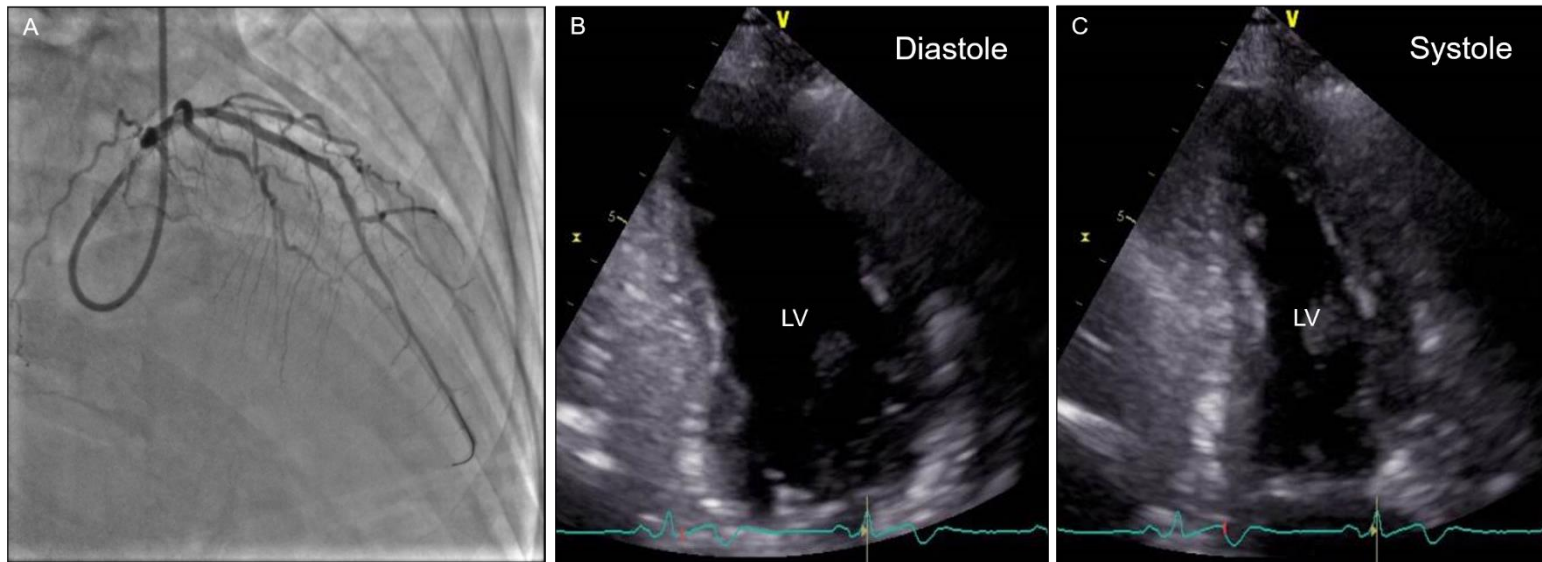


Figure S1.

A. Final coronary angiography after stent implantation. **B** and **C.** Transthoracic echocardiography in diastole (**B**) and systole (**C**) on Day 14 showing almost no asynergy of left ventricular wall. LV – left ventricle