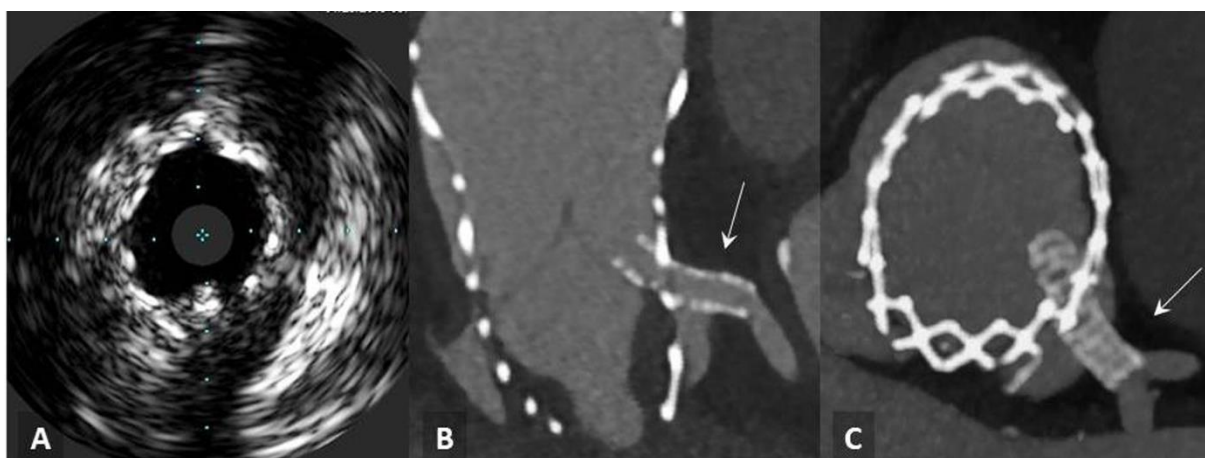


Supplementary material

Tyczyński P, Chmielak Z, Dąbrowski M, et al. Modified chimney / snorkel stenting of the left main coronary artery after transcatheter aortic valve implantation. Kardiol Pol. 2020; 78: 792-793. doi:10.33963/KP.15391

Please note that the journal is not responsible for the scientific accuracy or functionality of any supplementary material submitted by the authors. Any queries (except missing content) should be directed to the corresponding author of the article.



Supplementary Figure S1.

A) Intravascular ultrasonography after stenting; B, C) Computed tomography angiography four days after stenting. Visible coronary stent implanted into the left main coronary artery and crossing the leaflets of bioprosthesis and the cell of scaffolding (white arrows).