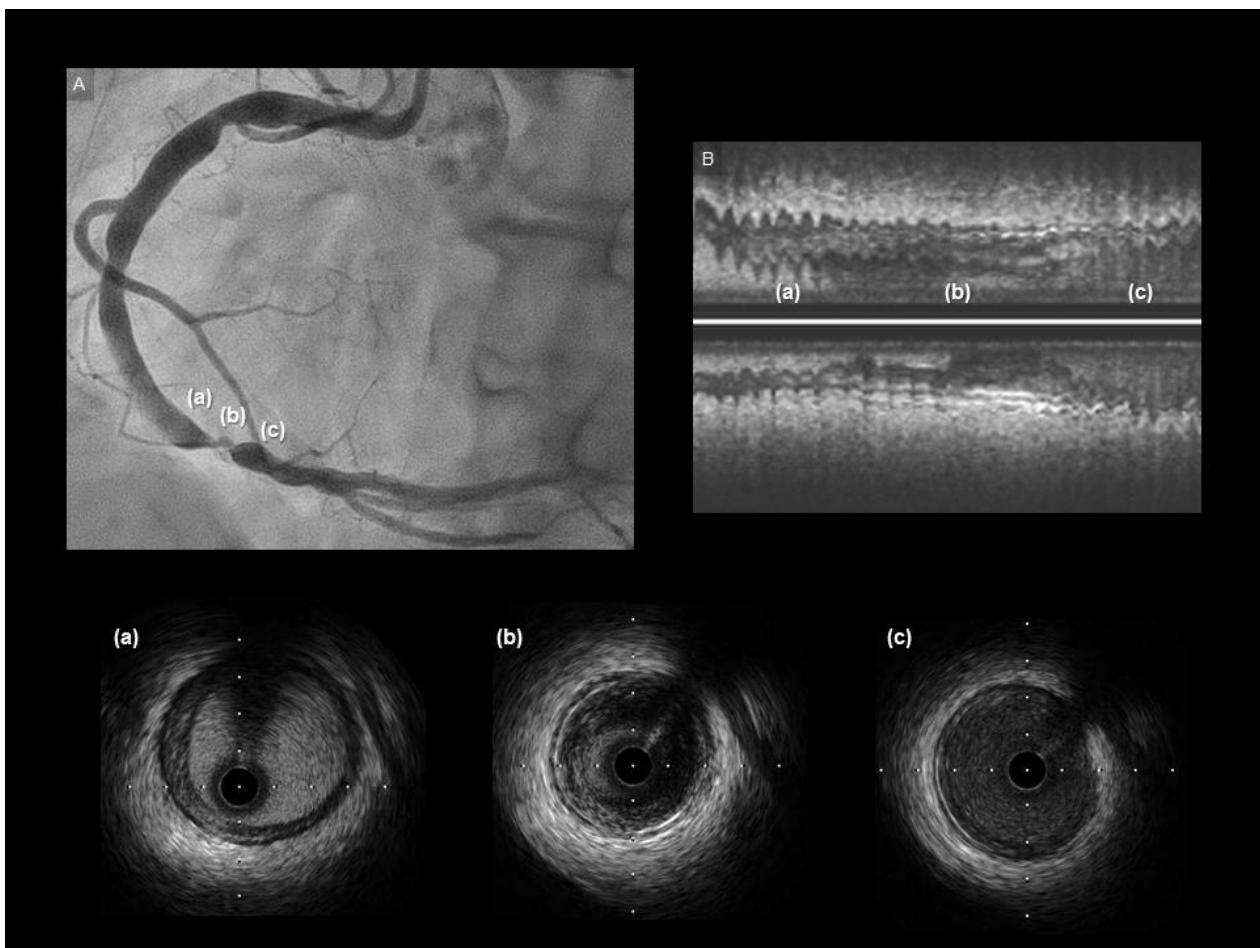


Supplementary material

Nakajima A, Mitomo S, Demir OM, Nakamura S. Sneaking hematoma beyond the stent implanted for focal stenosis of the right coronary artery: insight from intravascular ultrasound. Kardiol Pol. 2020; 78: 790-791. doi:10.33963/KP.15389

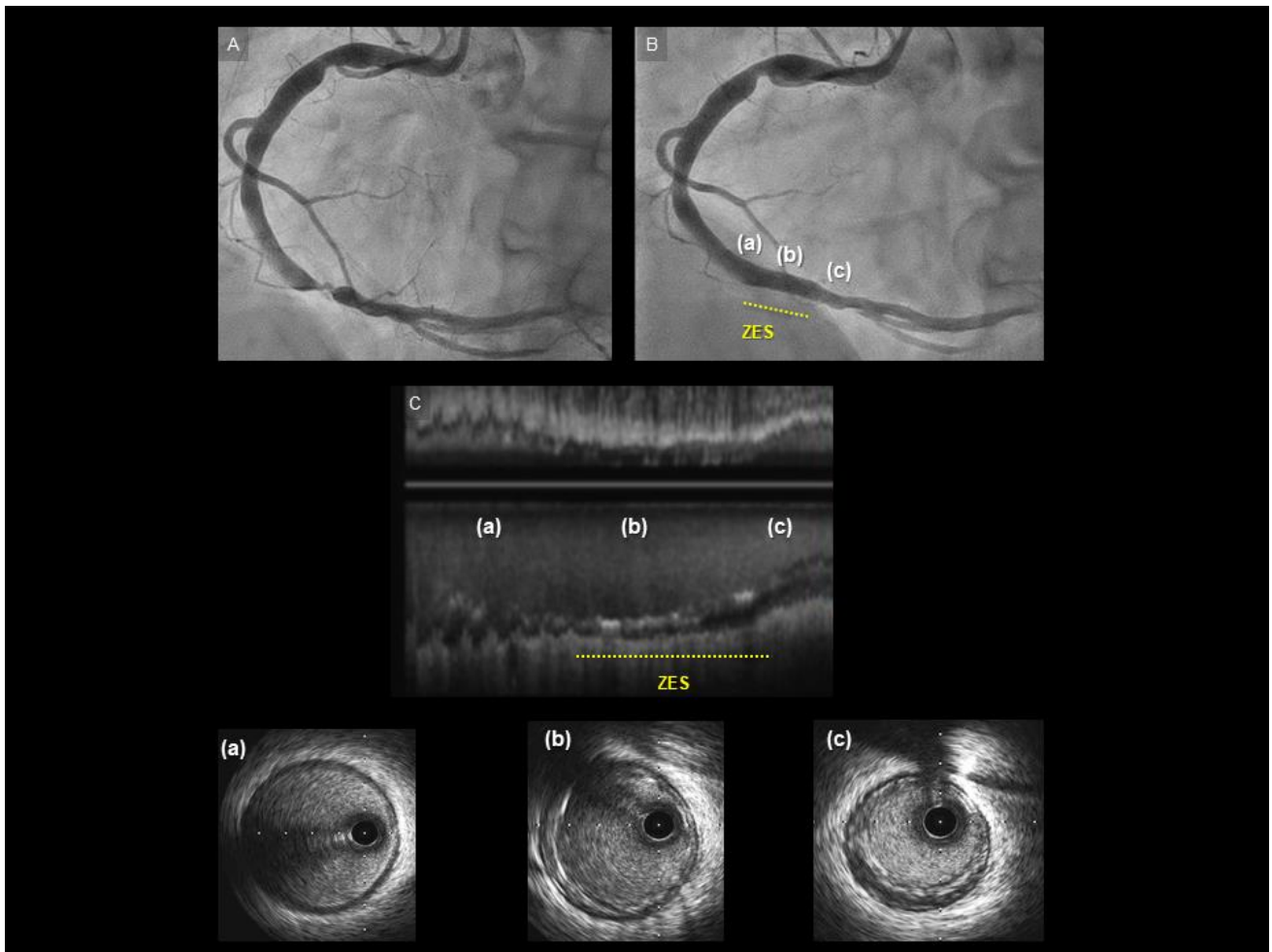
Please note that the journal is not responsible for the scientific accuracy or functionality of any supplementary material submitted by the authors. Any queries (except missing content) should be directed to the corresponding author of the article.



Supplemental figure S1. Baseline CAG and IVUS

A: Baseline CAG.

B: Baseline IVUS at the index procedure. IVUS showed a concentric fibro-fatty plaque without calcification, and slight negative remodeling (a: proximal, b: mid, c: distal).



Supplemental figure S2. CAG and Final images at index PCI

A: Baseline CAG.

B: Final angiography at index procedure.

C. Final IVUS at the index procedure. IVUS confirmed complete stent apposition without edge dissection (a: proximal to the stent, b: stented segments, c: distal to the stent).