

Supplementary material

Basavarajaiah S, Kalkat H, Watkin R. A golden tube following bioresorbable scaffold implantation. Kardiol Pol. 2020; 78: 782-783. doi:10.33963/KP.15355

Please note that the journal is not responsible for the scientific accuracy or functionality of any supplementary material submitted by the authors. Any queries (except missing content) should be directed to the corresponding author of the article.

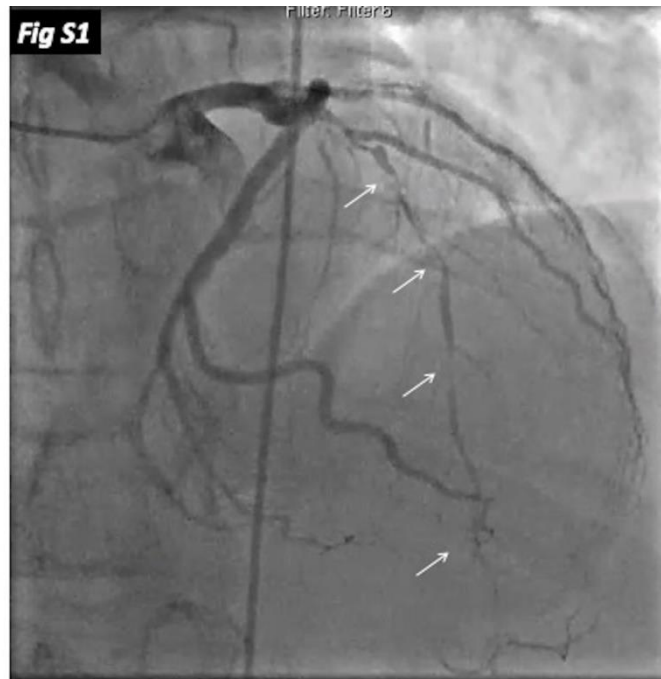


Figure S1: Severe diffuse lesion in the LAD involving a large first-diagonal

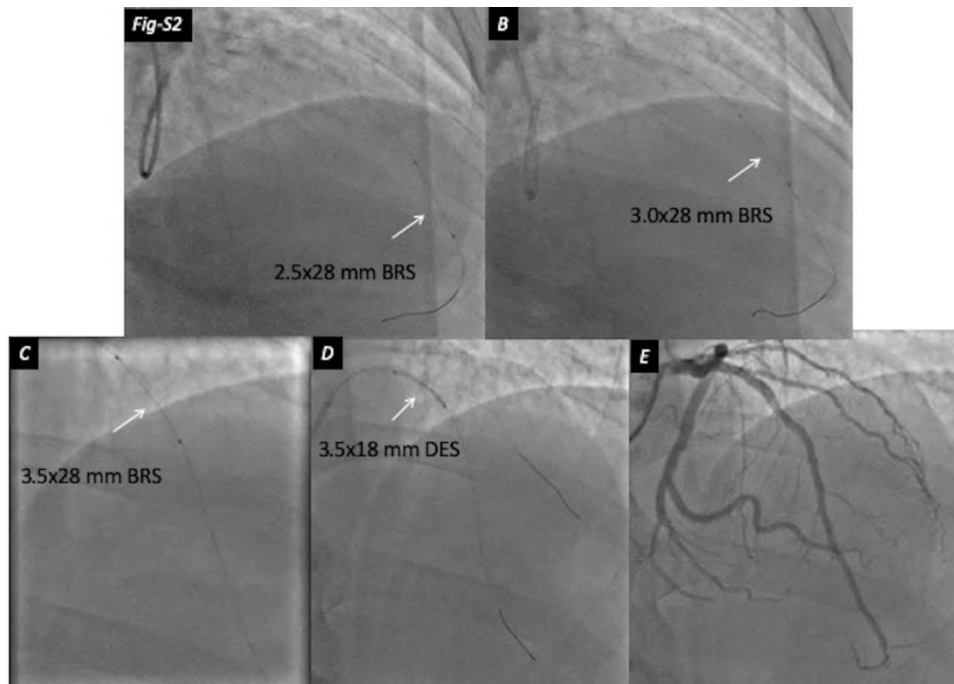


Figure S2: Deployment of BRS and DES

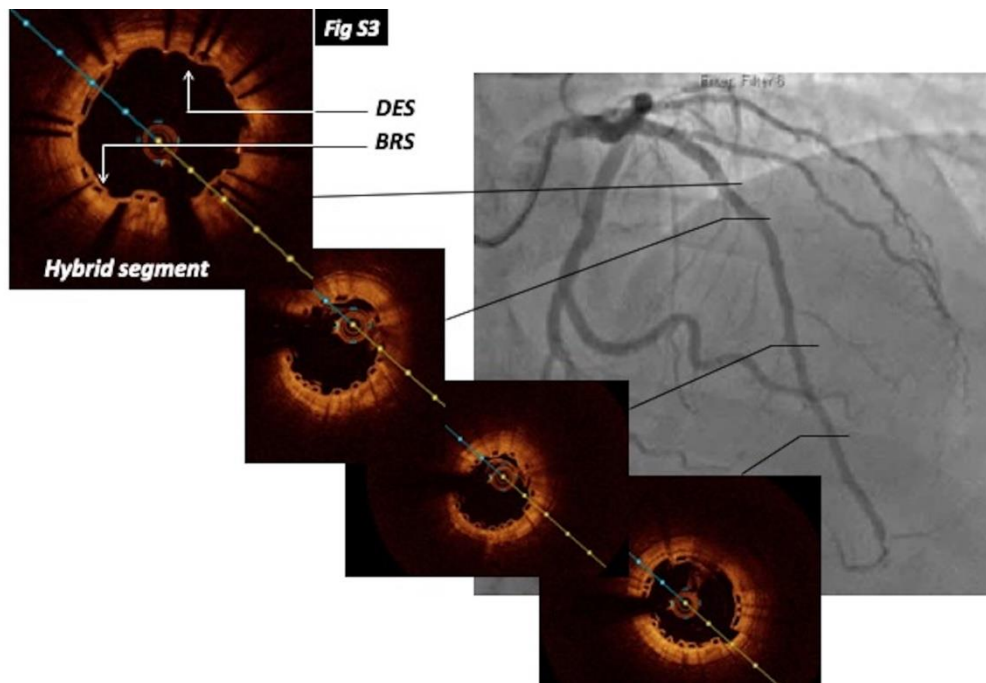


Figure S3: Angiogram and OCT demonstrating well apposed scaffolds and stent struts including the hybrid-segment

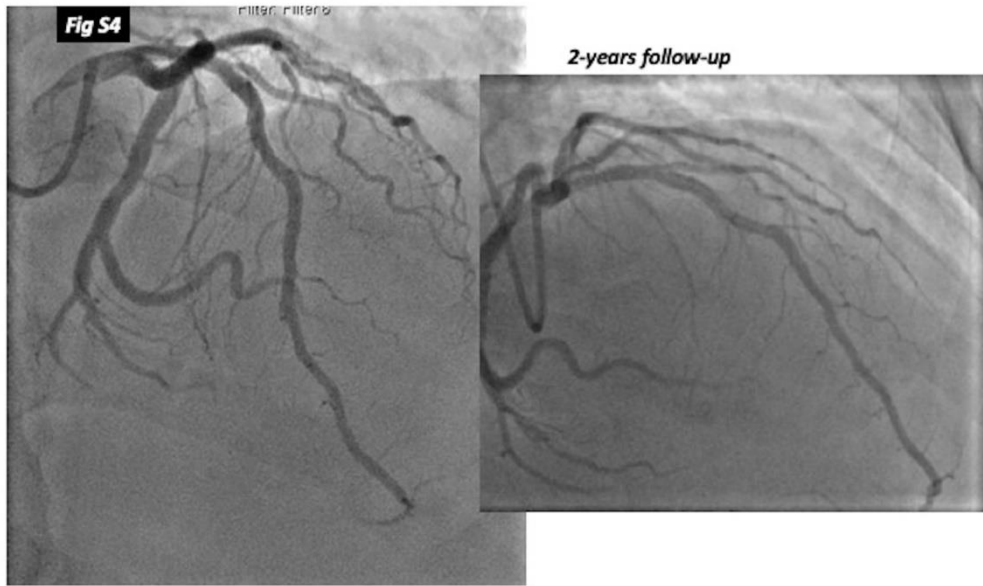


Figure S4: Angiogram at 2-years demonstrating continued good results

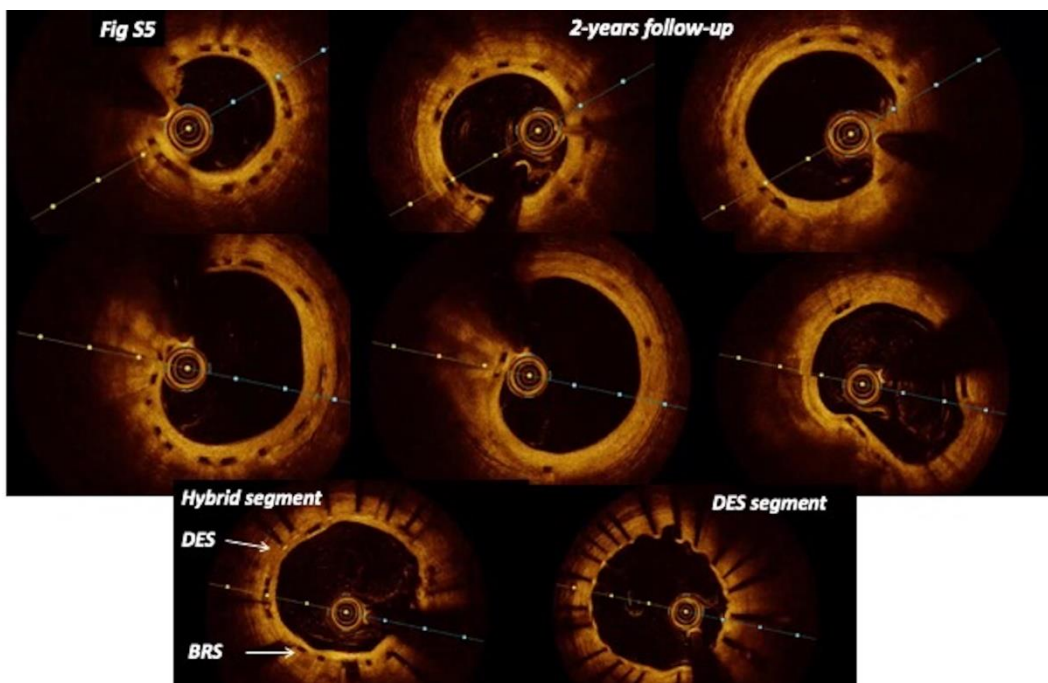


Figure S5: OCT at 2-years showing persisting scaffold, but fully endothelialized

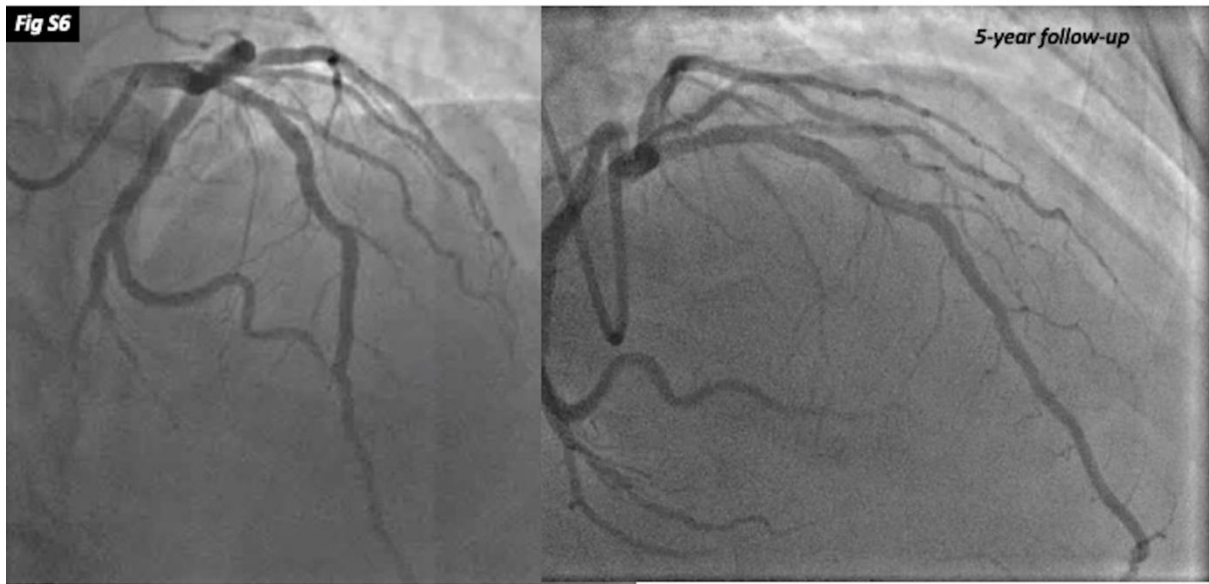


Figure S6: Angiogram at 5-years demonstrating continued good results

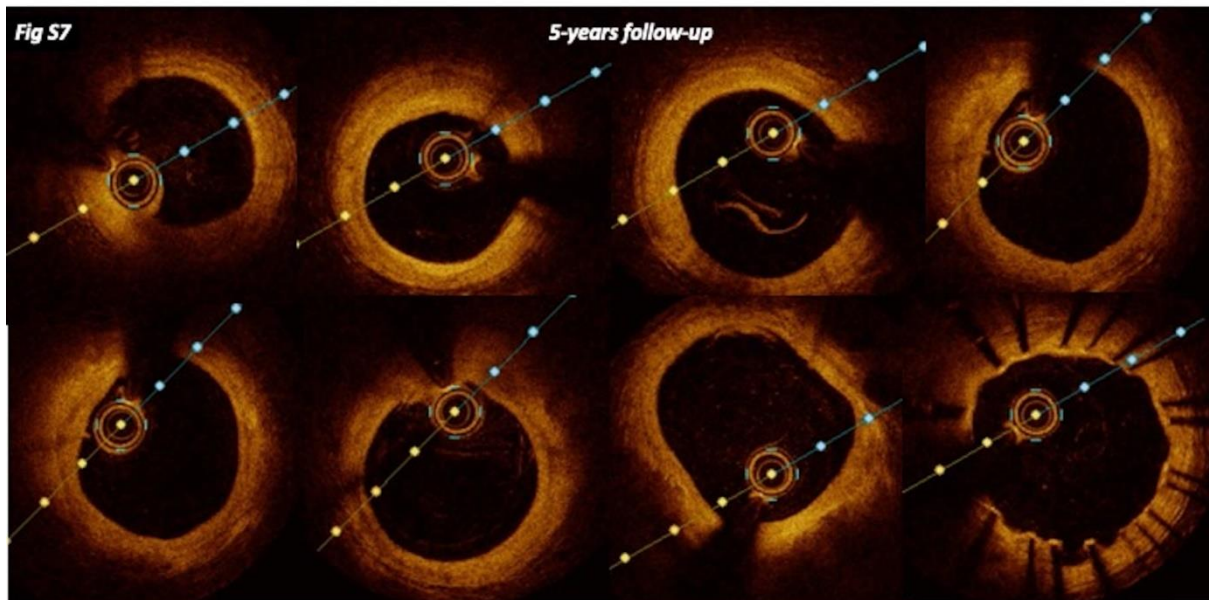


Figure S7: OCT at 5-years demonstrating complete resorption of scaffolds

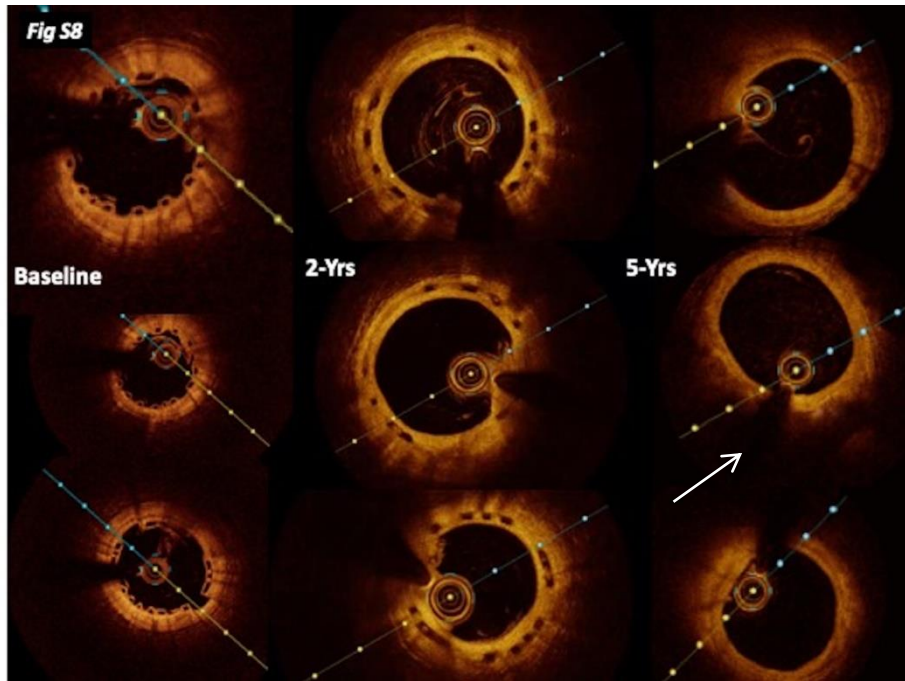


Figure S8: OCT comparison at 6-months, 2-years and 5-years