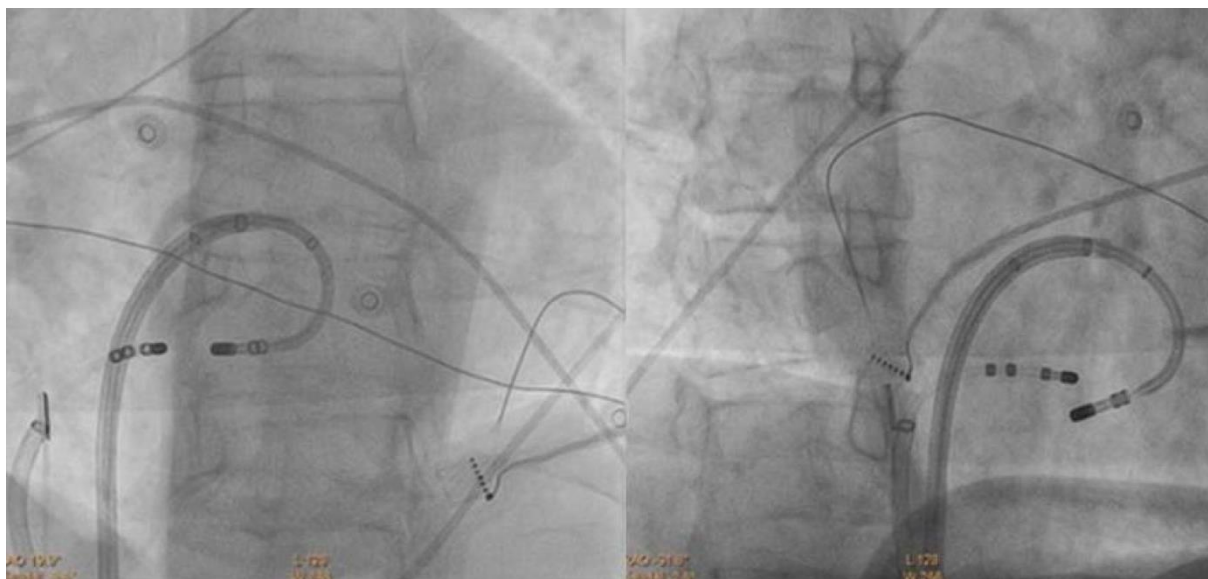


## **Supplementary material**

---

*Baran J, Piotrowski R, Sikorska A, Kułakowski P. Bipolar ablation of a posteroseptal accessory pathway in a patient without a typical coronary sinus ostium. Kardiol Pol. 2020; 78: 476-477. doi:10.33963/KP.15266*

Please note that the journal is not responsible for the scientific accuracy or functionality of any supplementary material submitted by the authors. Any queries (except missing content) should be directed to the corresponding author of the article.



**Supplementary Figure S1-** Fluoroscopic presentation of active and passive electrodes during ablation. Passive catheter is located on tricuspid annulus and active catheter is positioned on mitral annulus. Both catheters were introduced to the heart throughout long sheaths to stabilize their position during ablation. Left-hand side – left anterior oblique view, right-hand side – right anterior oblique view.