

Supplementary material

Głowacki J, Jackowska Z, Nożyński J, et al. Coral reef aorta involving the proximal part of the descending aorta. Kardiol Pol. 2019; 77: 486-487. doi:10.33963/KP.14798

Please note that the journal is not responsible for the scientific accuracy or functionality of any supplementary material submitted by the authors. Any queries (except missing content) should be directed to the corresponding author of the article.

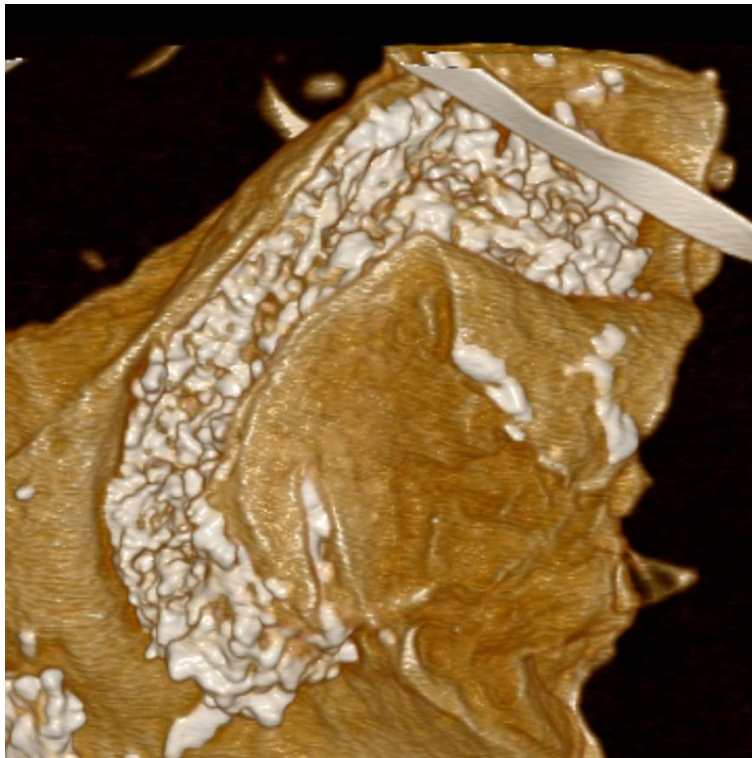


Figure S1 Computed tomography reconstruction showing a calcified lesion in the proximal part of descending aorta

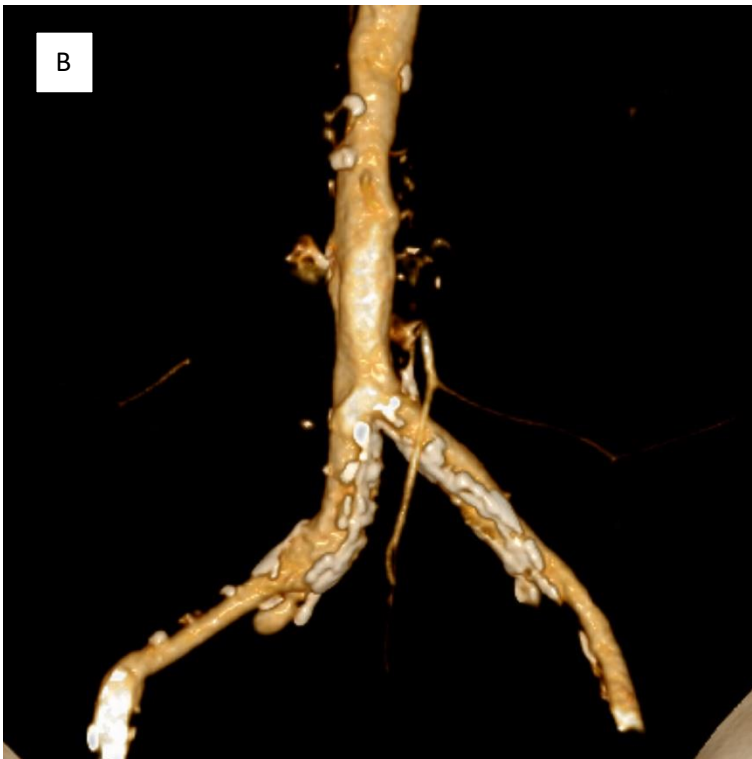
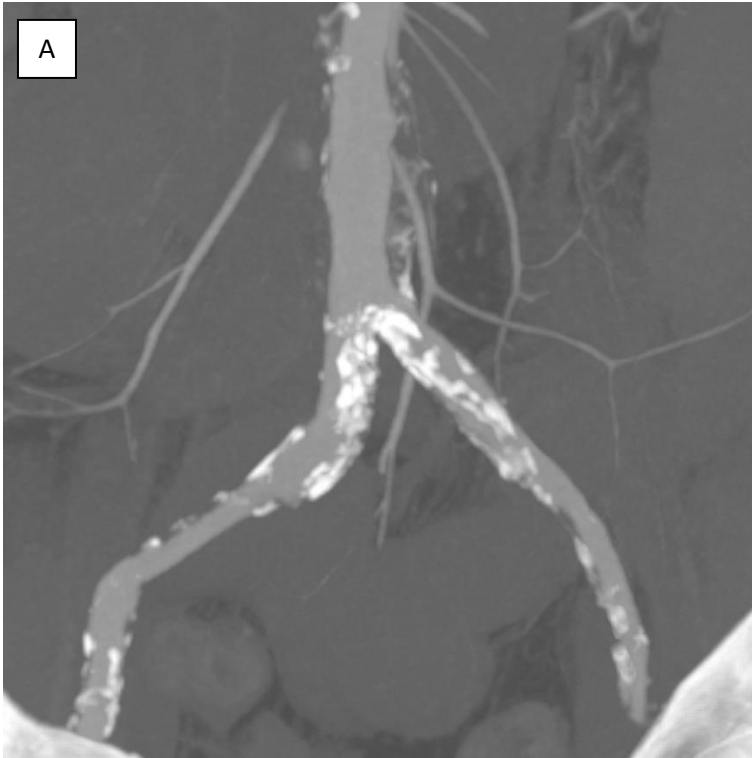

Figure S2 Computed tomography (A) and computed tomography reconstruction (B) showing the lesion in the aortic bifurcation