

## Supplementary material

Zbroński K, Sabiniewicz R, Scisło P, et al. Percutaneous retrograde paramitral leak closure through a mechanical aortic valve. *Kardiol Pol.* 2019; 77: 482-483. doi:10.33963/KP.14799

Please note that the journal is not responsible for the scientific accuracy or functionality of any supplementary material submitted by the authors. Any queries (except missing content) should be directed to the corresponding author of the article.

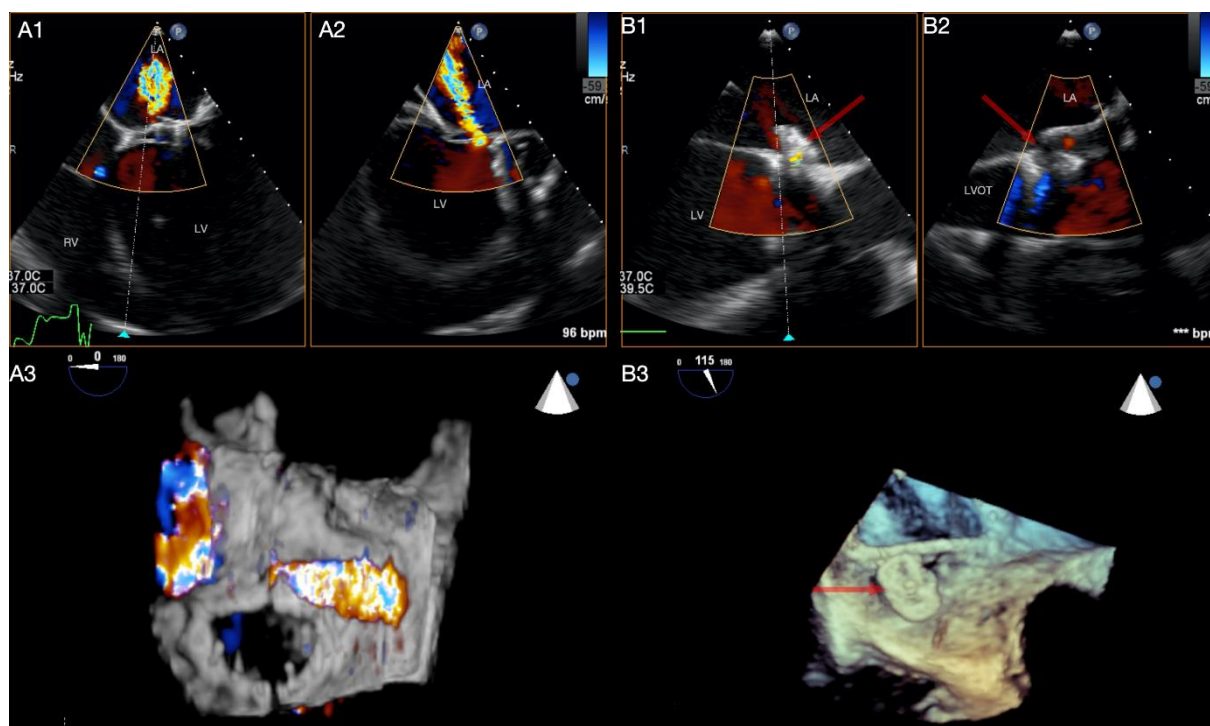


Figure S1. Panel A1-A3. TEE, modified mid-esophageal view. Para-ring mitral regurgitation through perforation of anterior mitral leaflet. Panel B1-B3. TEE, modified mid-esophageal view. Significant reduction of para-ring mitral regurgitation due to the device implantation.