

Supplementary material

Kaufmann D, Nowak R, Meyer-Szary J, et al. Double trouble: The rare coexistence of double-chambered left ventricle with hypertrabeculation. Pol Heart J. 2024.

Please note that the journal is not responsible for the scientific accuracy or functionality of any supplementary material submitted by the authors. Any queries (except missing content) should be directed to the corresponding author of the article.

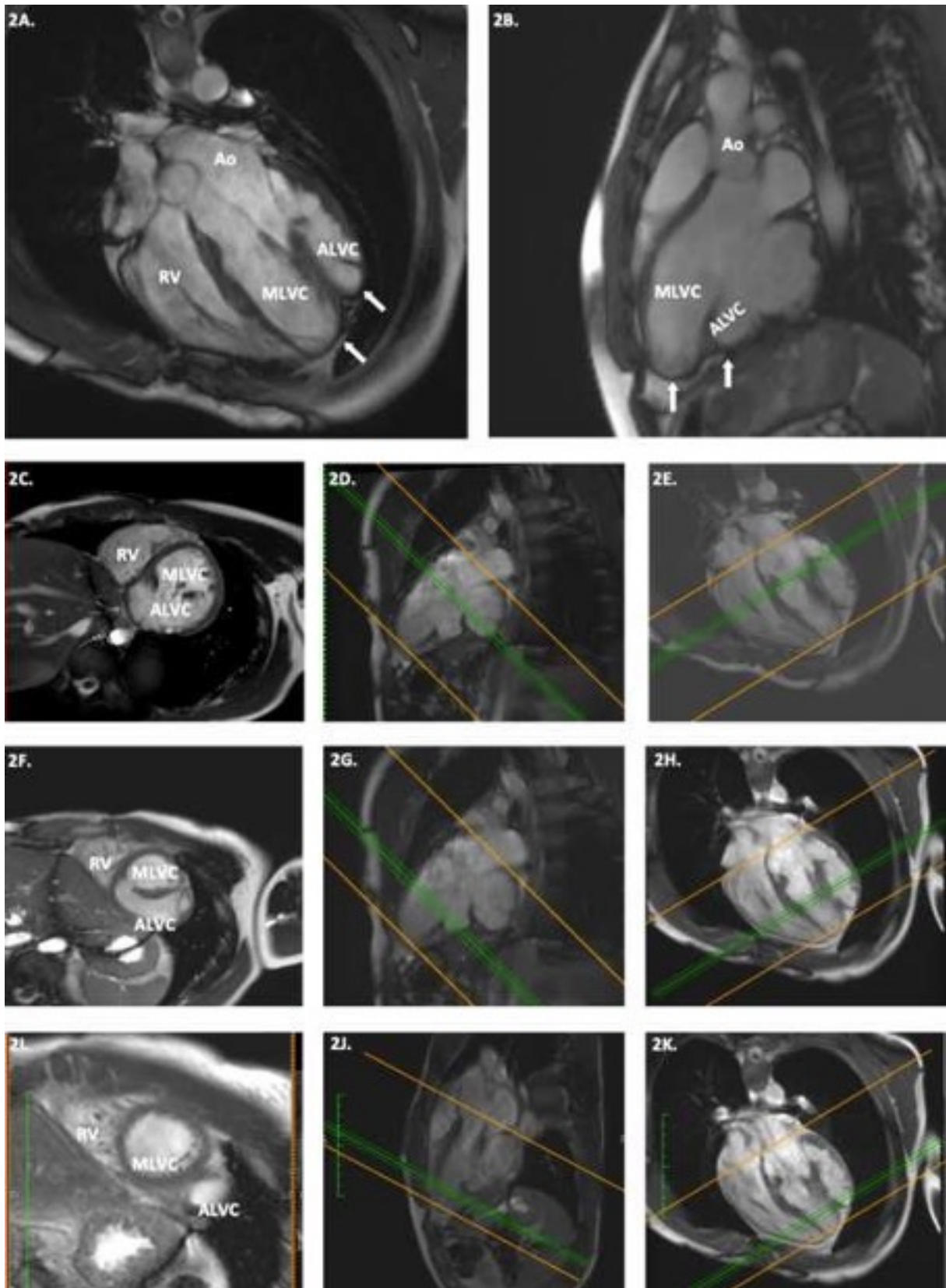


Figure S1. Cardiac magnetic resonance shows irregularly-shaped LV with double apex (2 A, B; white arrows). 2C-2K presents short-axis cross-section views of the respective ventricular levels marked with the green bar on two perpendicular long axis planes