

Supplementary material

Siregar MNI, Wahidji VH. A rare case of posterolateral ST-elevation myocardial infarction in Brugada syndrome: A double trouble beyond mimicking. Pol Heart J. 2024.

Please note that the journal is not responsible for the scientific accuracy or functionality of any supplementary material submitted by the authors. Any queries (except missing content) should be directed to the corresponding author of the article.

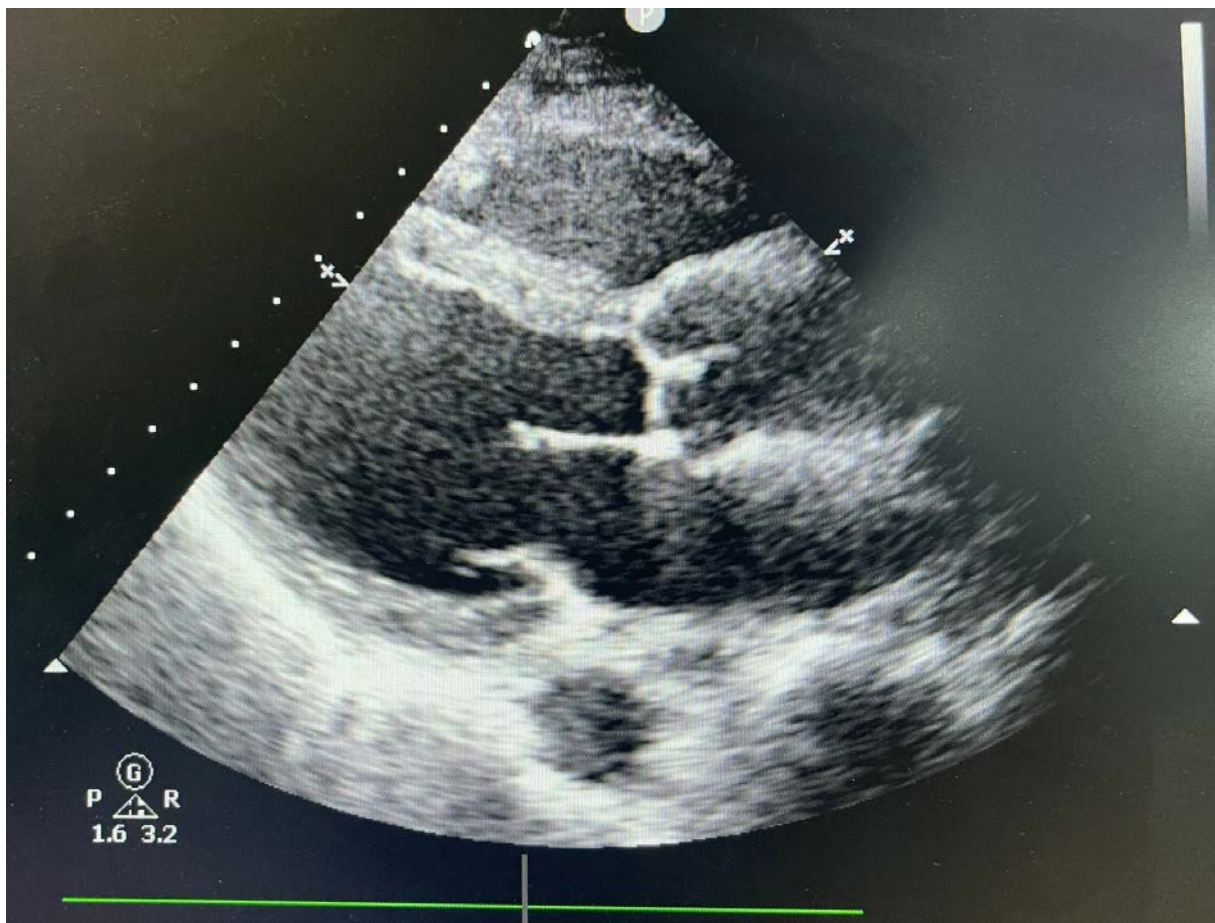


Figure S1.

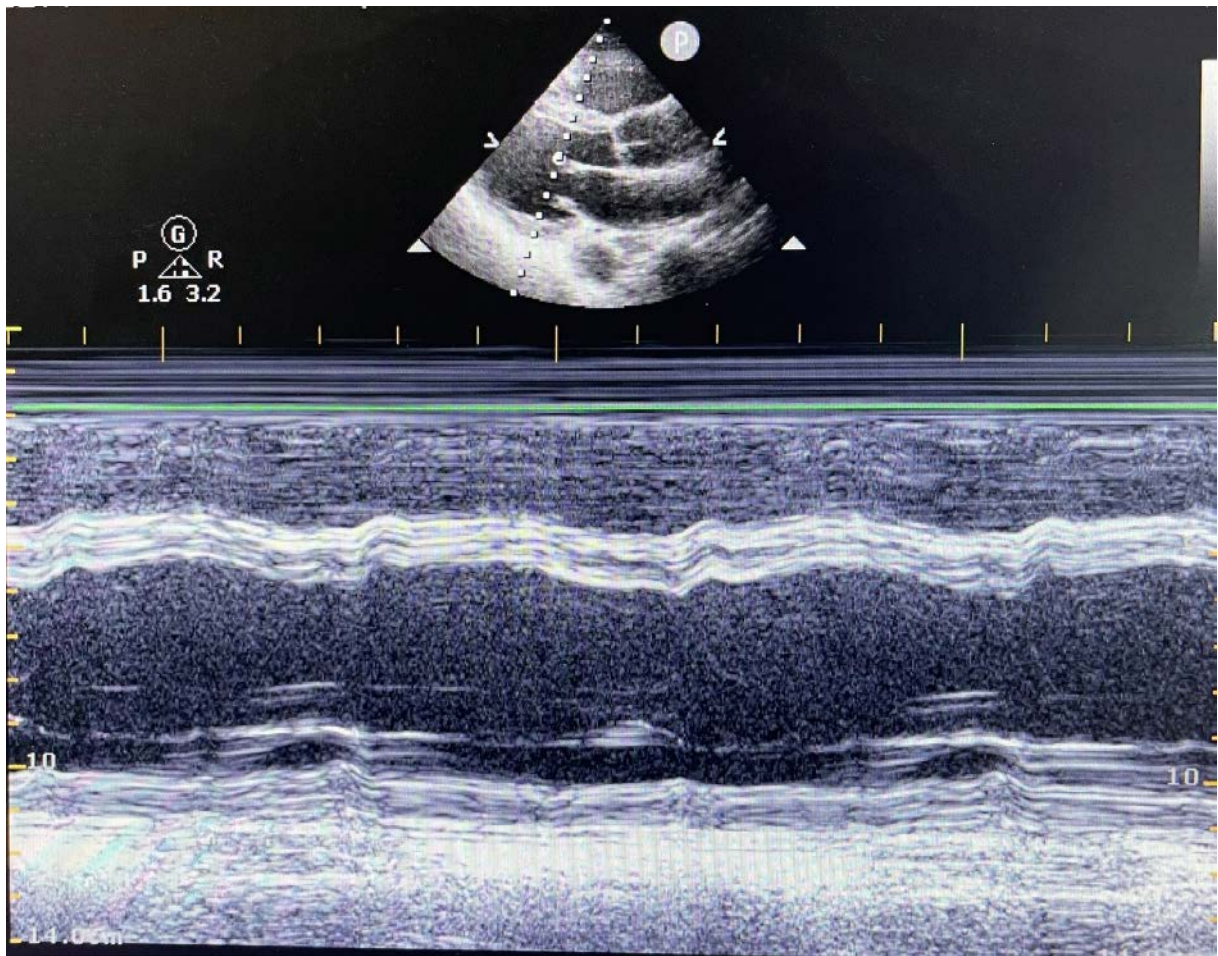


Figure S2.

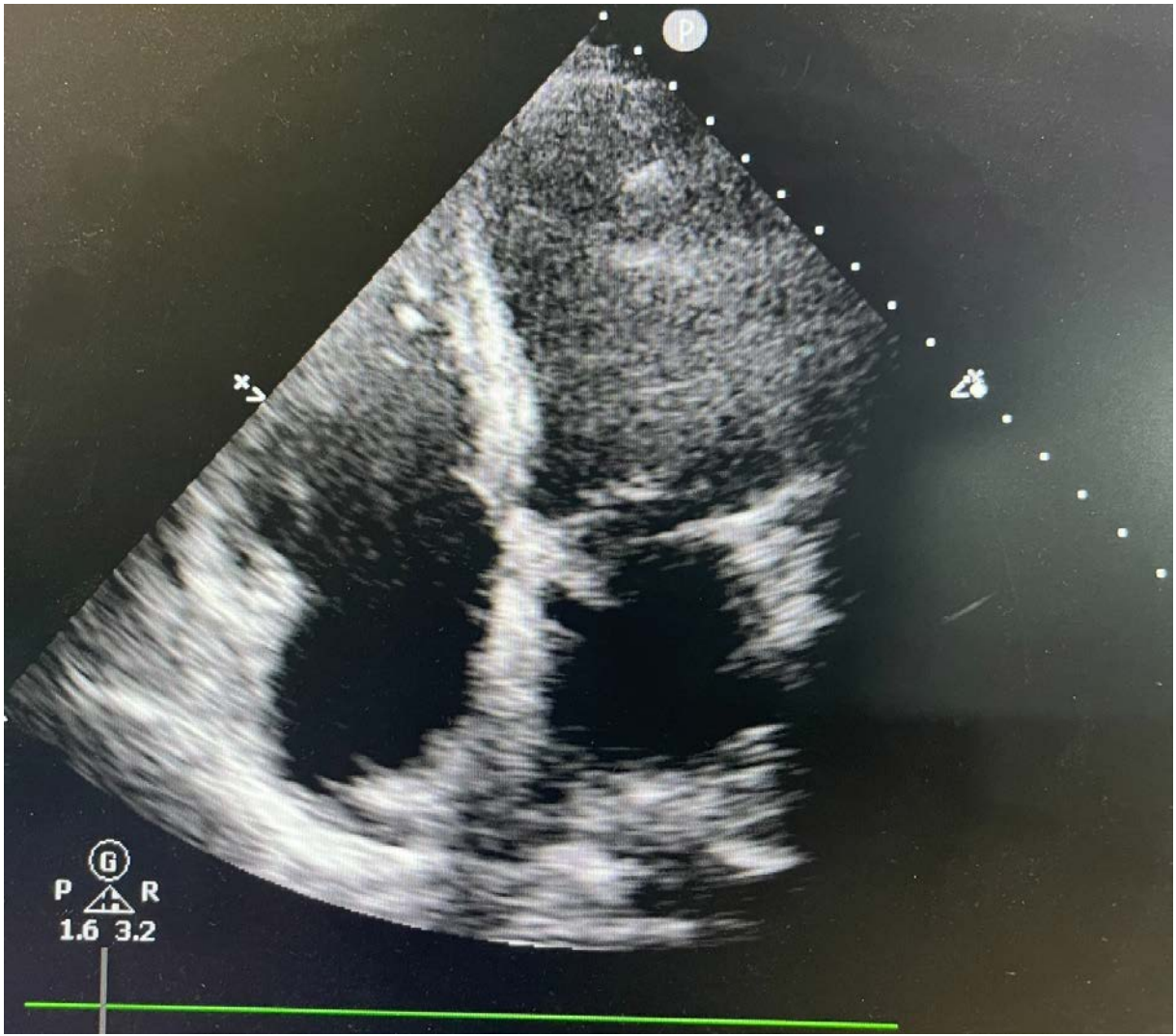


Figure S3.

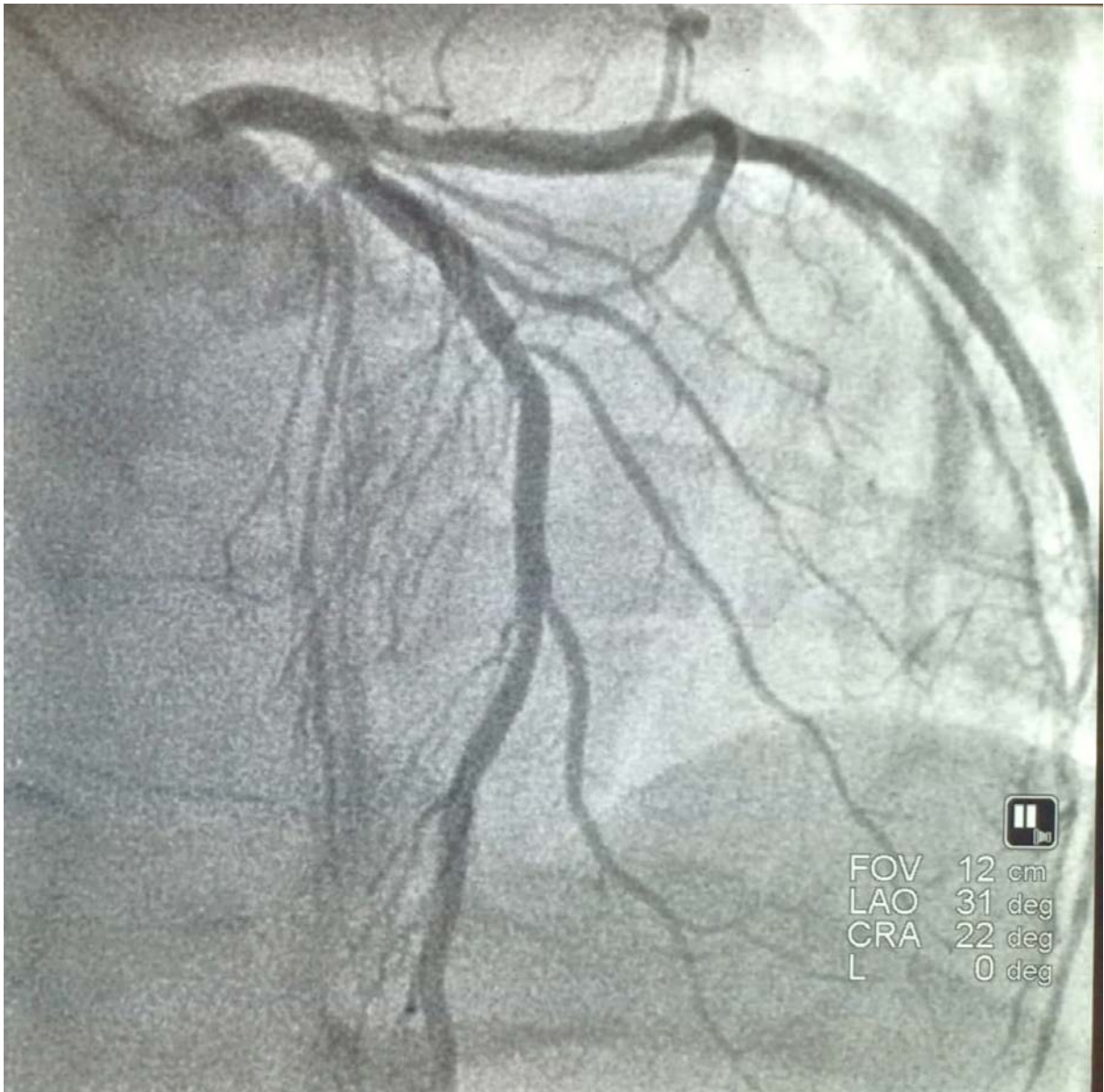


Figure S4.

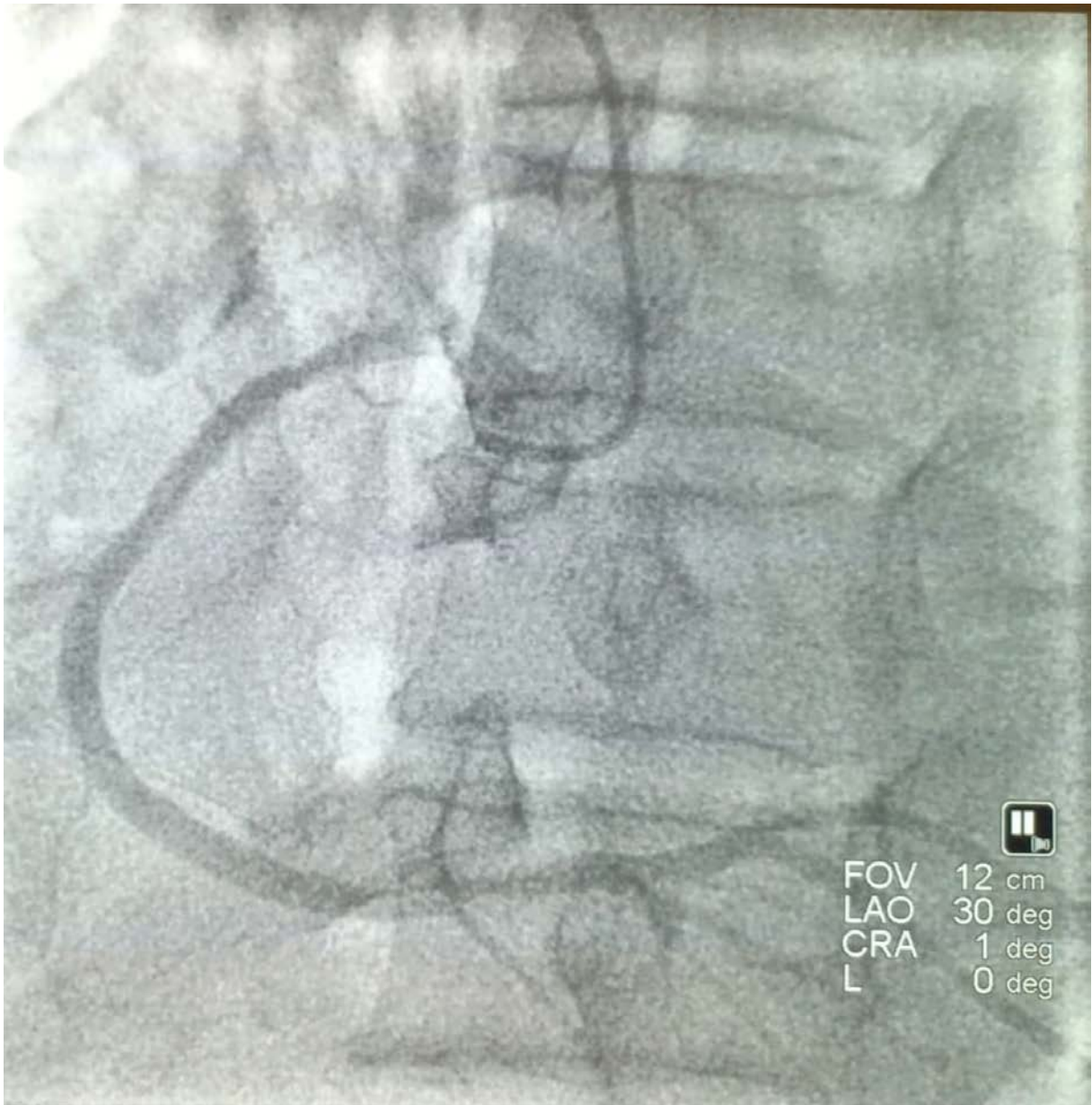


Figure S5.

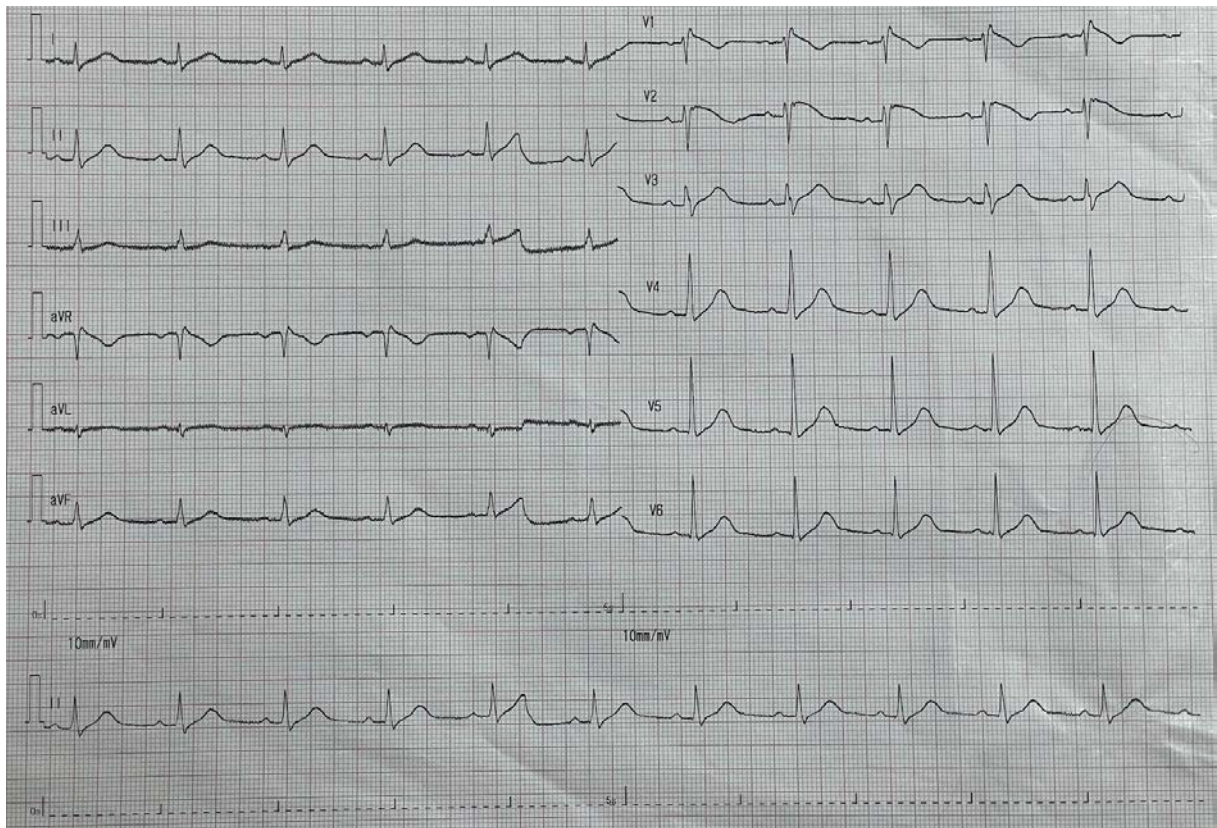


Figure S6.