

Supplementary material

Kuźma J, Buczyński M, Lim HY, et al. Saline agitated echocardiography in the diagnosis of cor triatriatum dexter: Case series and literature review. Pol Heart J. 2024.

Please note that the journal is not responsible for the scientific accuracy or functionality of any supplementary material submitted by the authors. Any queries (except missing content) should be directed to the corresponding author of the article.

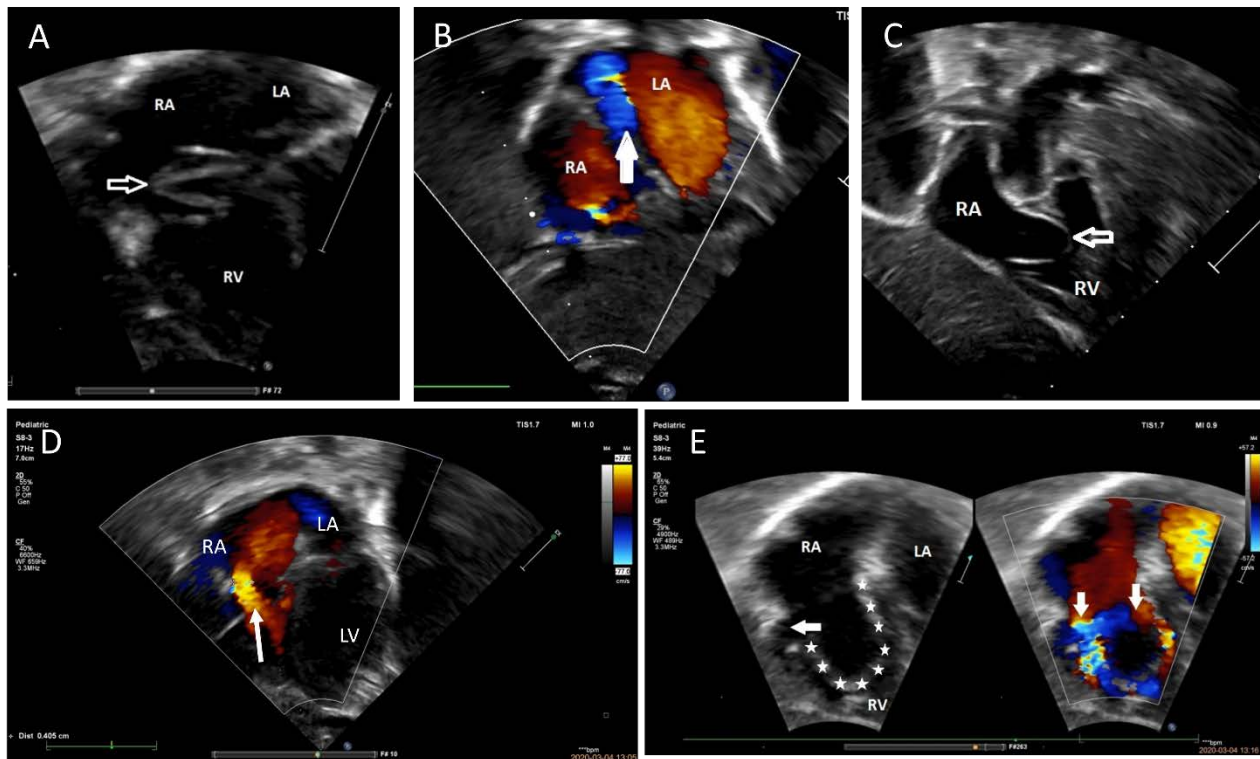


Figure S1. Cor triatriatum dexter with prominent EV obturating tricuspid valve and causing right-to-left shunting through the FO. **A.** TTE. Subcostal 4 chamber view showing prominent EV (white arrow) in systole above the tricuspid valve. **B.** TTE. Subcostal 4 chamber view with color Doppler flow showing right-to-left shunting through the FO (white arrow) with obstructed tricuspid valve. **C.** TTE. Subcostal projection with 2 dimensional view. A windsock of the EV (stars) during diastole with 2 narrow stenotic inflows (white arrows). **D.** TTE. Subcostal 4 chamber view with color Doppler flow in diastole revealing the obstructed inflow. **E.** TTE. Subcostal 4 chamber view with color Doppler flow showing a windsock of the EV (white stars) obstructing tricuspid inflow (white arrows)

Abbreviations: EV, Eustachian valve; FO, foramen ovale; LA, left atrium; LV, left ventricle; RA, right atrium; RV, right ventricle; TTE, transthoracic echocardiography