

Supplementary material

Kurnicka K, Cader T, Machowski M, et al. A large atrial septal aneurysm in a patient with atrial fibrillation: Is it just a structural deformation or a clinical problem? Pol Heart J. 2024.

Please note that the journal is not responsible for the scientific accuracy or functionality of any supplementary material submitted by the authors. Any queries (except missing content) should be directed to the corresponding author of the article.

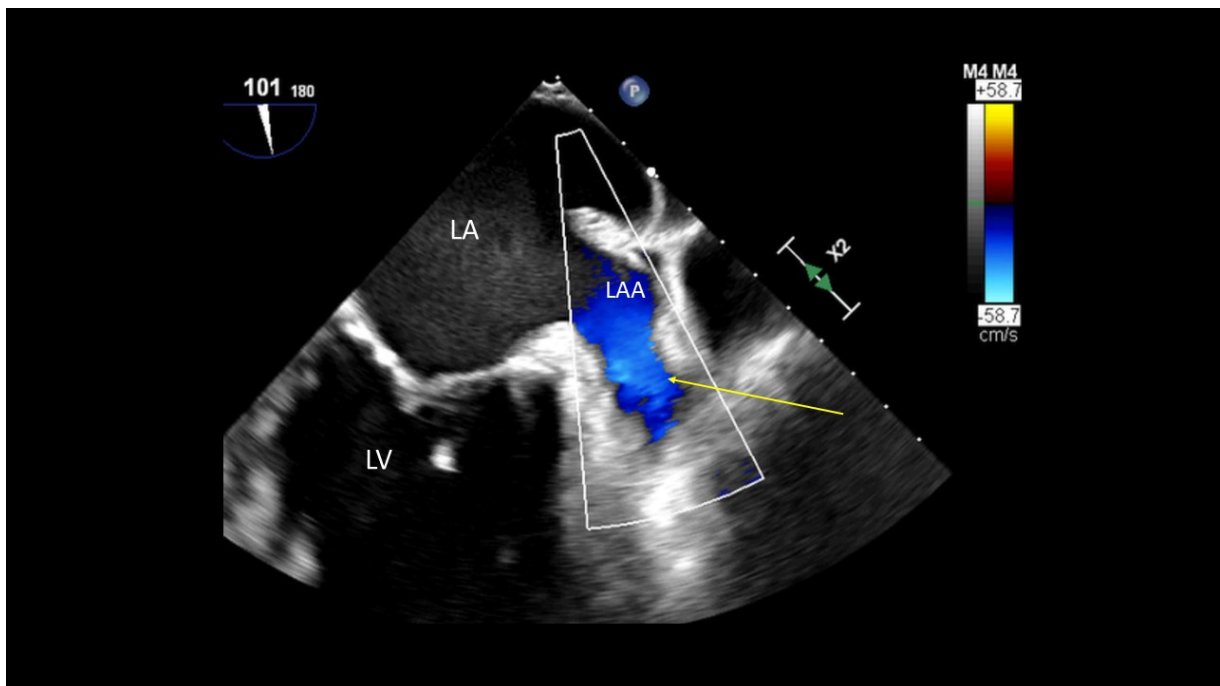


Figure S1. Left atrial appendage without a thrombus (arrow); 2-dimensional transoesophageal echocardiography, color Doppler

Abbreviations: LA, left atrium; LAA, left atrial appendage; LV, left ventricle

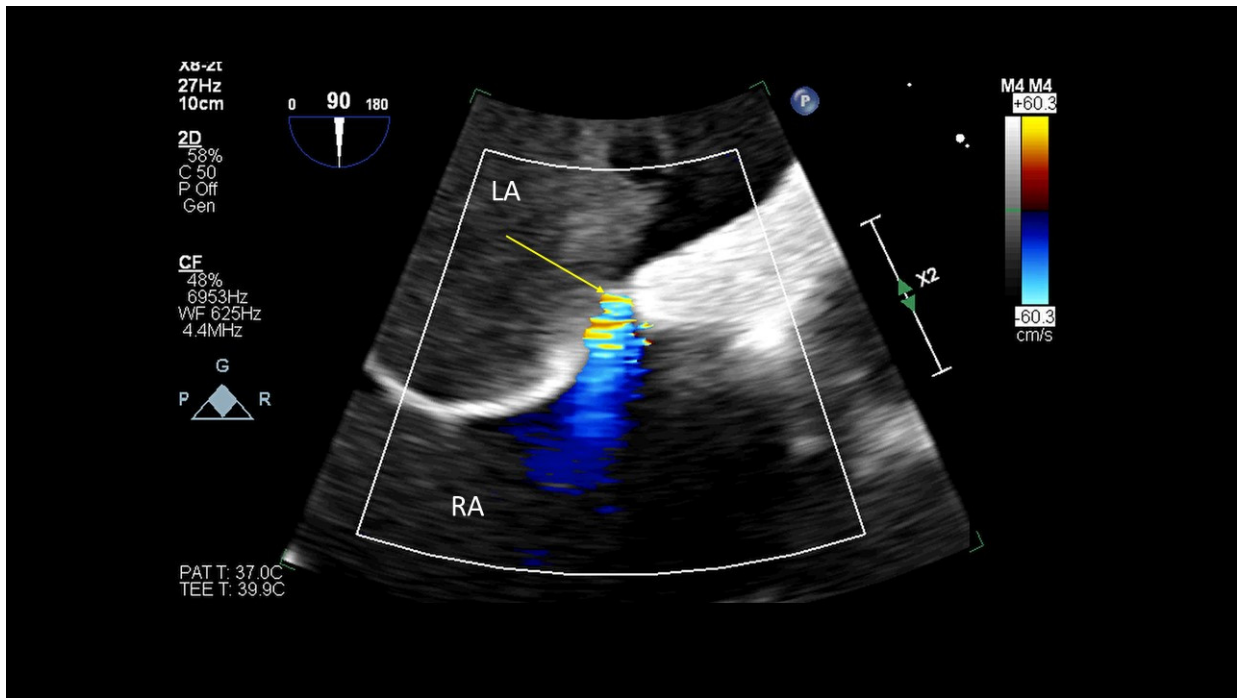


Figure S2. Follow-up: more pronounced left to right shunt through the PFO (arrow); 2-dimensional transoesophageal echocardiography, color Doppler

Abbreviations: LA, left atrium; RA, right atrium