

## Percutaneous treatment of right heart endocarditis

Jerzy Sacha<sup>1,2</sup>, Przemysław Lipski<sup>1</sup>, Jarosław Bugajski<sup>1</sup>, Maciej Marszałski<sup>3</sup>, Witold Gwóźdź<sup>4</sup>, Joanna Płonka<sup>1</sup>, Paweł Tomaszewski<sup>4</sup>, Marek Cisowski<sup>4</sup>, Marek Gierlotka<sup>1</sup>

<sup>1</sup>Department of Cardiology, University Hospital, Institute of Medical Sciences, University of Opole, Opole, Poland

<sup>2</sup>Faculty of Physical Education and Physiotherapy, Opole University of Technology, Opole, Poland

<sup>3</sup>Department of Anesthesiology, University Hospital, Institute of Medical Sciences, University of Opole, Opole, Poland

<sup>4</sup>Department of Cardiac Surgery, University Hospital, Faculty of Natural Sciences and Technology, University of Opole, Opole, Poland

### Correspondence to:

Jerzy Sacha, MD, PhD,  
Department of Cardiology,  
University Hospital in Opole,  
Institute of Medical Sciences,  
University of Opole,  
Al. Witosa 26, 45–401 Opole,  
Poland  
phone: +48 77 452 06 60,  
e-mail: sachaj@op.pl

Copyright by the Author(s), 2023

DOI: 10.33963/KPa.2023.0176

### Received:

April 29, 2023

### Accepted:

July 10, 2023

### Early publication date:

August 4, 2023

Right heart endocarditis (RHE) is a significant issue among drug addicts [1]. Intravenous antibiotics serve as the primary treatment for RHE. However, in cases that are resistant or complicated with valve dysfunction, cardiac surgery may be necessary [2]. We present a case where the vegetation on the tricuspid valve was removed percutaneously using a vacuum-assisted device in a patient with recurrent RHE despite antibiotic treatment. The illness was successfully treated, and there was no relapse during the 12-month observation period.

A 22-year-old male drug addict was admitted for recurrent RHE. For a year, he had been treated three times for relapses of tricuspid endocarditis. Despite the temporary success of antibiotic therapy, the disease returned after a few months. During that period, echocardiography showed growing pedunculated vegetation (measuring finally 2.5 × 1.2 cm) attached to the anterior tricuspid leaflet, with only mild-to-moderate tricuspid regurgitation (Figure 1A, B, Supplementary material, Video S1).

Since valve function did not significantly deteriorate and after discussion with the Heart Team, we decided to remove the vegetation percutaneously as prophylaxis against recurrent endocarditis. To achieve this, we used the AngioVac system (AngioDynamics, Latham, NY, US), which consists of a venous drainage cannula and a re-infusion (venous return) cannula that are connected to the extracorporeal circuit and centrifugal pump [3, 4].

The AngioVac drainage cannula was inserted through the right internal jugular vein via the DrySeal 26F Sheath (Gore Medical, Newark, DE, US) (Figure 1C, Supplementary

material, Video S2), while the 18 F reinfusion cannula was inserted into the right femoral vein. The centrifugal pump (RotaFlow ECMO system, Maquet Cardiovascular, Wayne, NJ, US) generated a flow of up to 5 liters per minute, and the vegetation was successfully removed (Figure 1D–F, Supplementary material, Video S3).

The tricuspid regurgitation remained mild to moderate. Both jugular and femoral vascular access were percutaneously closed with Proglides. During the 12-month follow-up, the patient had no symptoms or signs of infection relapse. Furthermore, he received treatment at a drug addiction center and remained drug-free.

This case demonstrates that percutaneous removal of vegetation material is a safe and feasible option for right heart endocarditis in patients without significant valvular damage. It also highlights the effectiveness of percutaneous aspiration, making it a promising option for minimally invasive intracardiac material removal.

### Supplementary material

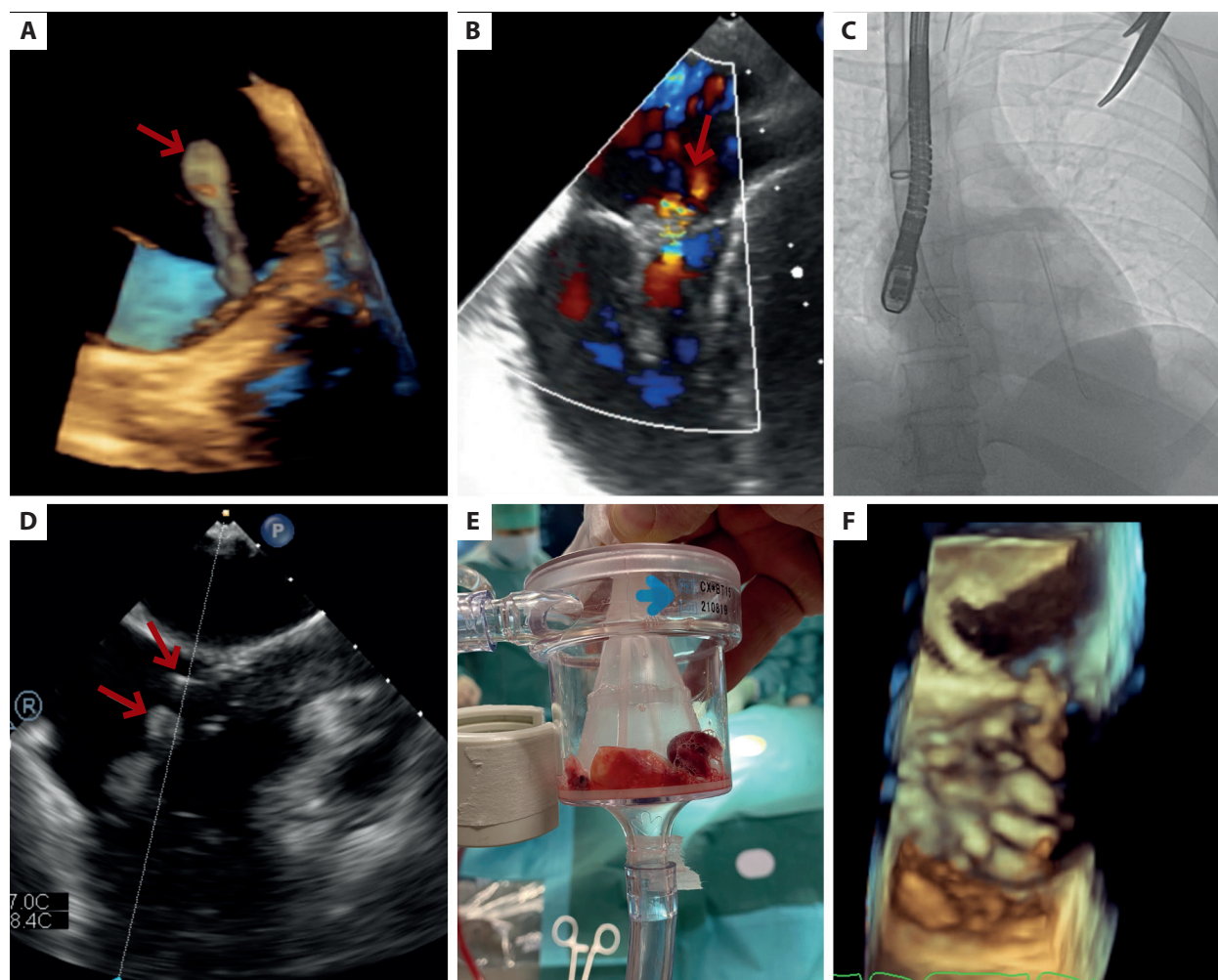
Supplementary material is available at [https://journals.viamedica.pl/kardiologia\\_polska](https://journals.viamedica.pl/kardiologia_polska).

### Article information

**Conflict of interest:** None declared.

**Funding:** None.

**Open access:** This article is available in open access under Creative Commons Attribution-Non-Commercial-No Derivatives 4.0 International (CC BY-NC-ND 4.0) license, which allows downloading and sharing articles with others as long as they credit the authors and the publisher, but without permission to change them in any way or use them commercially. For commercial use, please contact the journal office at [kardiologiapolska@ptkardio.pl](mailto:kardiologiapolska@ptkardio.pl).



**Figure 1.** **A.** 3D transesophageal echocardiography (TEE) shows large vegetation (arrow) attached to the anterior tricuspid leaflet — see Supplementary material, *Video S1*. **B.** TEE shows mild tricuspid regurgitation (arrow). **C.** The AngioVac drainage cannula is inserted into the right atrium, and the TEE probe is inserted into the esophagus — see Supplementary material, *Video S2*. **D.** The tip of the AngioVac cannula (white arrow) faces the vegetation (grey arrow) in the right atrium (TEE imaging) — see Supplementary material, *Video S3*. **E.** The vegetation removed from the tricuspid valve is caught by the AngioVac filter. **F.** 3D TEE shows the tricuspid valve without vegetation

## REFERENCES

1. Rudasill SE, Sanaïha Y, Mardock AL, et al. Clinical outcomes of infective endocarditis in injection drug users. *J Am Coll Cardiol.* 2019; 73(5): 559–570, doi: [10.1016/j.jacc.2018.10.082](https://doi.org/10.1016/j.jacc.2018.10.082), indexed in Pubmed: [30732709](https://pubmed.ncbi.nlm.nih.gov/30732709/).
2. Shmueli H, Thomas F, Flint N, et al. Right-Sided Infective Endocarditis 2020: challenges and updates in diagnosis and treatment. *J Am Heart Assoc.* 2020; 9(15): e017293, doi: [10.1161/JAHA.120.017293](https://doi.org/10.1161/JAHA.120.017293), indexed in Pubmed: [32700630](https://pubmed.ncbi.nlm.nih.gov/32700630/).
3. Moriarty JM, Rueda V, Liao M, et al. Endovascular removal of thrombus and right heart masses using the AngioVac system: results of 234 patients from the Prospective, Multicenter Registry of Angiovac Procedures in Detail (RAPID). *J Vasc Interv Radiol.* 2021; 32(4): 549–557.e3, doi: [10.1016/j.jvir.2020.09.012](https://doi.org/10.1016/j.jvir.2020.09.012), indexed in Pubmed: [33526346](https://pubmed.ncbi.nlm.nih.gov/33526346/).
4. Puślecki M, Stefaniak S, Katarzyński S, et al. AngioVac: The first in Poland percutaneous solid thrombus aspiration from the right atrium. *Kardiol Pol.* 2022; 80(1): 103–104, doi: [10.33963/KP.a2021.0128](https://doi.org/10.33963/KP.a2021.0128), indexed in Pubmed: [34643258](https://pubmed.ncbi.nlm.nih.gov/34643258/).