

Cyanotic patients require specific follow-up

Agnieszka Bartczak-Rutkowska, Sonia Nartowicz, Marta Kałużna-Oleksy, Aleksandra Cieplucha, Maciej Lesiak, Olga Trojnarśka

^{1st} Department of Cardiology, Poznan University of Medical Sciences, Poznań, Poland

Correspondence to:

Agnieszka Bartczak-Rutkowska, MD, PhD,
^{1st} Department of Cardiology, Poznan University of Medical Sciences, Długa 1/2, 61–848 Poznań, Poland, phone: +48 618 549 156, e-mail: aga.bartczak@gmail.com

Copyright by the Author(s), 2023

DOI: 10.33963/KPa.2023.0171

Received:

May 8, 2023

Accepted:

July 12, 2023

Early publication date:

July 31, 2023

A 34-year-old cyanotic woman (oxygen saturation, 79%) with pulmonary atresia, perimembranous outlet nonrestrictive ventricular septal defect, patent ductus arteriosus, and major aortopulmonary collaterals (MAPCAS) (Figure 1A–D) was admitted for the first time to the outpatient center for adults with congenital heart defects. On admission, her blood tests were performed (hemoglobin, 15 g/dl; hematocrit, 49%; ferritin, 2.3 ng/ml; transferrin saturation, 7.6%). She was disqualified from surgical correction in childhood due to complete pulmonary blood supply from the MAPCAS. At the age of 32 years, she suffered from right-sided hemiparesis and aphasia. Diagnostics performed at that time showed abnormal levels of hematocrit (53.1%) and hemoglobin (17.2 g/dl); a head computed tomography (CT) scan depicted ischemia of the left-sided lentiform and caudate nucleus (42 × 22 × 22 mm size) and hyperdense M2 segment of the left middle cerebral artery. A diagnosis of ischemic stroke was made. Due to the unknown time of symptom onset, fibrinolysis was not administered. Angiography of the left carotid artery showed obstructions of the left-sided middle and anterior cerebral arteries managed with mechanical thrombectomy (Penumbra System). During the follow-up, she fully recovered. Since then, the patient has been managed with enoxaparin and aspirin.

One year later, she was hospitalized for fever and constant headache that had lasted for seven days. On admission, head CT showed a hypodense area in the left frontal lobe with a hyperdense ring (25 × 20 × 19 mm size) and surrounding tissue edema. A brain abscess was diagnosed, and amoxicillin with clavulanic acid was initiated. The patient was transferred to the neurosurgical ward, and pharmacotherapy was changed to vancomycin, ceftriaxone, and metronidazole. The abscess

was confirmed on magnetic resonance imaging and neurosurgically removed (Figure 1E). The microbiological examination did not reveal any pathogen. Ultrasound examination of lower extremity veins showed a thrombus in the right posterior tibial and popliteal veins, and anticoagulation was changed from aspirin and enoxaparin to rivaroxaban.

Knowing the risk of thromboembolic complications due to relative anemia and the results from the patient's blood tests on admission to our outpatient clinic, we decided to administer oral iron therapy.

Cyanotic patients are amenable to cerebral injury, i.e., ischemic stroke or brain abscess formation [1]. The main reasons for ischemic stroke are hyperviscosity syndrome and iron deficiency. Reduced oxygen saturation triggers secondary erythrocytosis, the lower the oxygen saturation, the higher the hematocrit level as a result of adaptation [2]. In routine laboratory work-up, it is essential to check for iron deficiency, as it is the main prognostic factor in this population. Right-to-left shunting bypassing the pulmonary circulation enables bacteria to flow directly to cerebral vessels [1]. Also, hypoxemia, causing tissue hypoxia creates a suitable environment for brain abscess formation [3]. A new episode of headache in cyanotic patients requires comprehensive assessment and treatment. Head imaging is the first step in the diagnostic process. Cephalosporine, meropenem, or metronidazole should be initiated without delay as the recommended empirical therapy for brain abscess [4]. Surgical intervention is required if the abscess exceeds 1cm in diameter [4]. Our patient was treated both pharmacologically and surgically, and she fully recovered. Avoiding infections with proper oral hygiene is critical to prevent future life-threatening events [5].

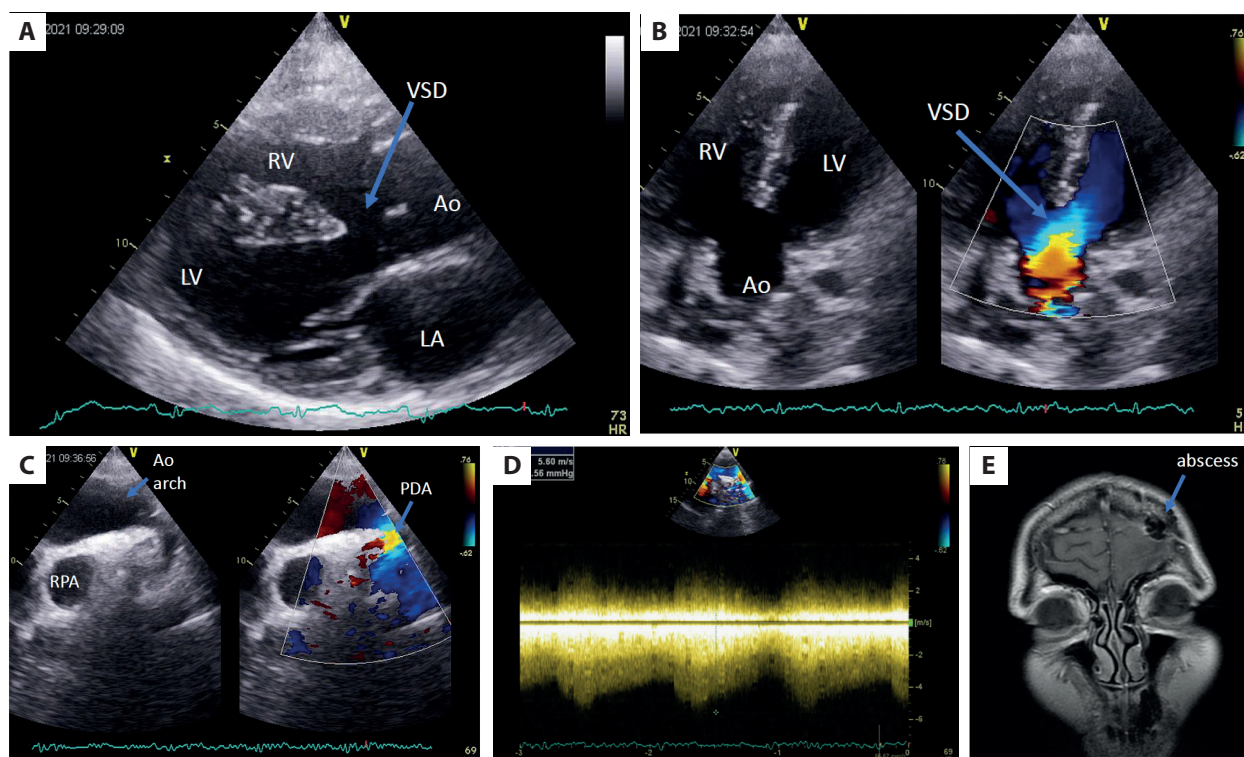


Figure 1. **A.** Transthoracic echocardiographic examination, parasternal long axis view, nonrestrictive perimembranous ventricular septal defect with bidirectional shunt. **B.** Transthoracic echocardiographic examination, five-chamber view, nonrestrictive perimembranous ventricular septal defect with bidirectional shunt. **C.** Transthoracic examination, suprasternal notch view, patent ductus arteriosus. **D.** Transthoracic examination, suprasternal notch view, continuous Doppler flow through the patent ductus arteriosus. **E.** Magnetic resonance examination of the brain, coronal plane, site of the abscess indicated with arrow

Abbreviations: Ao, aorta; Ao arch, aortic arch; LA, left atrium; LV, left ventricle; PDA, patent ductus arteriosus; RPA, right pulmonary artery; RV, right ventricle; VSD, ventricular septal defect

Article information

Conflict of interest: None declared.

Funding: None.

Open access: This article is available in open access under Creative Commons Attribution-Non-Commercial-No Derivatives 4.0 International (CC BY-NC-ND 4.0) license, which allows downloading and sharing articles with others as long as they credit the authors and the publisher, but without permission to change them in any way or use them commercially. For commercial use, please contact the journal office at kardiologiapolska@ptkardio.pl.

REFERENCES

- Oechslin E. Management of adults with cyanotic congenital heart disease. *Heart*. 2015; 101(6): 485–494, doi: [10.1136/heartjnl-2012-301685](https://doi.org/10.1136/heartjnl-2012-301685), indexed in Pubmed: [25301858](https://pubmed.ncbi.nlm.nih.gov/25301858/).
- Broberg CS. Risk and resiliency: thrombotic and ischemic vascular events, in cyanotic congenital heart disease. *Heart*. 2015; 101(19): 1521–1522, doi: [10.1136/heartjnl-2015-307849](https://doi.org/10.1136/heartjnl-2015-307849), indexed in Pubmed: [26194591](https://pubmed.ncbi.nlm.nih.gov/26194591/).
- Runkel BG, Drake WB, Raghuvver G. Brain Abscess and the Nonfenestrated Fontan Circulation. *JACC Case Rep*. 2020; 2(7): 1029–1032, doi: [10.1016/j.jaccas.2020.04.036](https://doi.org/10.1016/j.jaccas.2020.04.036), indexed in Pubmed: [34317408](https://pubmed.ncbi.nlm.nih.gov/34317408/).
- Brouwer MC, Tunkel AR, McKhann GM, et al. Brain abscess. *N Engl J Med*. 2014; 371(5): 447–456, doi: [10.1056/NEJMra1301635](https://doi.org/10.1056/NEJMra1301635), indexed in Pubmed: [25075836](https://pubmed.ncbi.nlm.nih.gov/25075836/).
- Gil KE, Jellis C, Griffin B. Unrecognized incomplete Shone's complex. Awareness is key in congenital heart disease. *Kardiol Pol*. 2022; 80(7-8): 859–860, doi: [10.33963/KP.a2022.0136](https://doi.org/10.33963/KP.a2022.0136), indexed in Pubmed: [35611930](https://pubmed.ncbi.nlm.nih.gov/35611930/).