

Severe mitral regurgitation complicating myocardial infarction: Adding fuel to the fire

Samir R Kapadia, Joseph Kassab, Serge C Harb

Department of Cardiovascular Medicine, Heart, Vascular & Thoracic Institute, Cleveland Clinic Foundation, Cleveland, OH, United States

Related article

by Ładziński et al.

Correspondence to:

Samir R Kapadia, MD, FACC, FAHA,
Chair, Department of
Cardiovascular Medicine,
Cleveland Clinic Foundation,
9500 Euclid Avenue, J2-3,
Cleveland, OH 44195,
phone: +216 444 6735,
e-mail: kapadis@ccf.org

Copyright by the Author(s), 2023

DOI: 10.33963/KPa2023.0114

Received:

April 24, 2023

Accepted:

April 24, 2023

Early publication date:

May 16, 2023

Ischemic mitral regurgitation (IMR) is a distinct form of valvular disorder, wherein the left ventricular abnormalities arising as a result of coronary artery disease (CAD) are the primary cause of valve dysfunction. Excluding cases of papillary muscle rupture, IMR is a secondary form of mitral regurgitation (MR) characterized by structurally normal leaflets, though with restricted motion and apical tethering causing displacement of the coaptation zone from the mitral annulus toward the apex of the left ventricle, and leading to incomplete systolic closure of the mitral valve [1].

In the study by Ładziński et al. [2], the authors present compelling evidence that severe MR following acute myocardial infarction (MI) is associated with a statistically significant increase in mortality and major adverse cardiovascular and cerebrovascular events (MACCE) in patients diagnosed with ST-segment elevation MI (STEMI) and non-ST-segment elevation MI (NSTEMI), during 12-month follow-up. Furthermore, severe MR was identified as an independent risk factor of all-cause death [2]. The incidence of severe MR in the current population is unknown. The study evaluated the prevalence and impact on prognosis of severe MR in a cohort of patients presenting with STEMI. Previously published studies also noted the adverse prognosis associated with MR following MI. Notably, Lamas et al. [3] demonstrated that, after a follow-up of 3.5 years, patients with IMR were more likely to experience cardiovascular mortality (29% vs. 12%; $P < 0.001$), severe heart failure (HF) (24% vs. 16%; $P = 0.015$), and the combined endpoint of cardiovascular mortality, severe HF, or recurrent MI (47% vs. 29%; $P < 0.001$).

The presence of MR was an independent predictor of cardiovascular mortality (relative risk [RR], 2.00; 95% confidence interval [CI], 1.28–3.04) [3]. Moreover, Grigioni et al. [4] showed that after 5 years, total and cardiac mortalities for patients with IMR ($62 \pm 5\%$ and $50 \pm 6\%$, respectively) were higher than for those without IMR ($39 \pm 6\%$ and $30 \pm 5\%$, respectively) (both $P < 0.001$). In multivariate analysis, independently of all baseline characteristics, the adjusted RRs of total and cardiac mortality associated with the presence of IMR were 1.88; $P = 0.003$, and 1.83; $P = 0.014$, respectively [4]. Nonetheless, despite the extensive evidence already available on the poor prognosis associated with IMR, Ładziński et al. [2] add to the growing body of literature by examining a large patient population ($n = 8062$) and categorizing them based on the type of myocardial infarction (MI) (STEMI vs. NSTEMI) and focusing solely on severe MR patients.

Interestingly, it is worth noting that in the NSTEMI subgroup, patients with severe MR were more likely to have HF, a previously implanted pacemaker, atrial fibrillation (AF), chronic kidney disease (CKD), and a history of CAD or coronary artery bypass graft (CABG). In the STEMI subgroup, severe MR patients were more likely to be older and have AF. When interpreting outcomes, it is crucial to consider that these variables are likely associated with increased mortality. Nonetheless, even when adjusting for ejection fraction (EF), age, and CKD by multivariate analysis, severe MR remained an independent factor for mortality.

It is important to also highlight the dynamic nature of IMR. Nishino et al. [5]

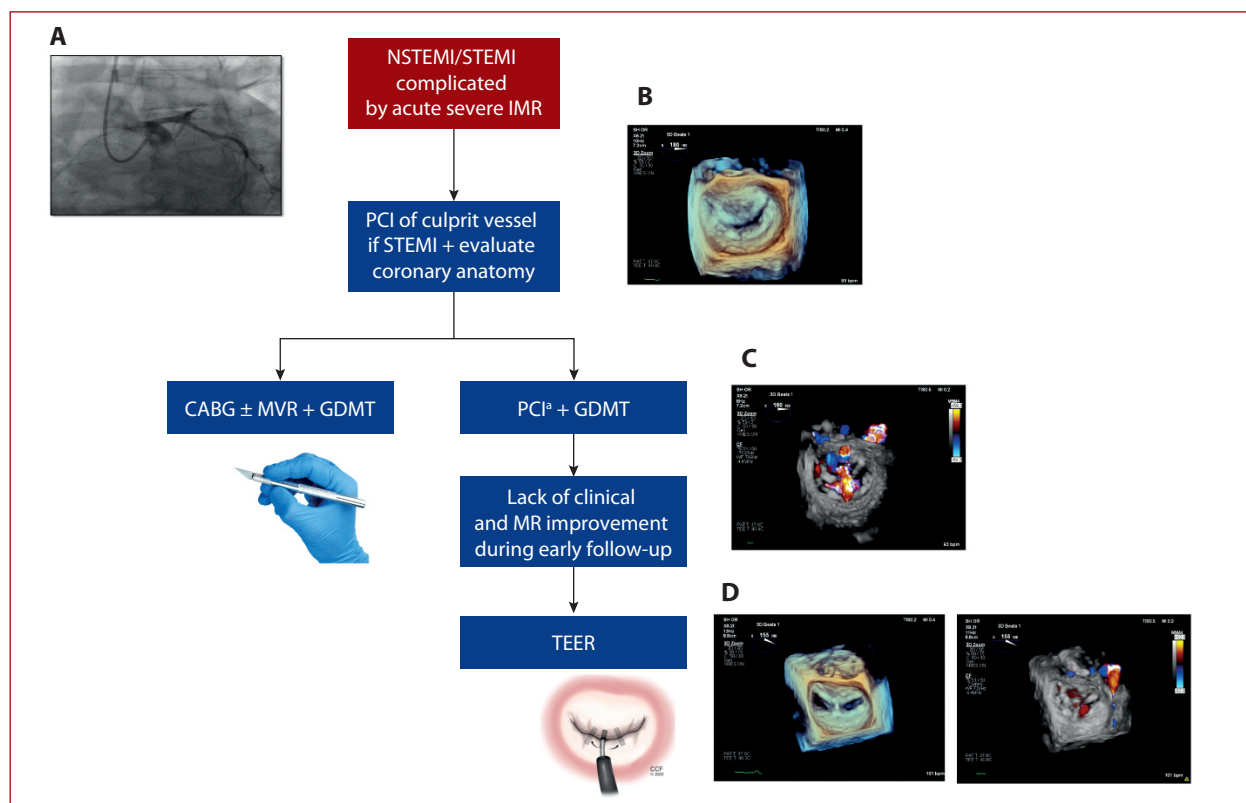


Figure 1. Proposed management for severe MR complicating acute myocardial infarction. **A.** Coronary angiography showcasing left anterior descending artery occlusion. **B.** Early transthoracic echocardiography showcasing severe ischemic MR. **C.** Follow-up transthoracic echocardiography showcasing unimproved severe ischemic MR. **D.** Post-TEER transthoracic echocardiography with improved mitral valve function *If further revascularization needed

Abbreviations, CABG, coronary artery bypass grafting; GDMT, guideline-directed medical therapy; IMR, ischemic mitral regurgitation; MR, mitral regurgitation; MVR, mitral valve repair/replacement; NSTEMI, non-ST-segment elevation myocardial infarction; PCI, percutaneous coronary intervention; STEMI, ST-segment elevation myocardial infarction; TEER, transcatheter edge-to-edge repair

evaluated the course of IMR in MI patients following PCI. They found that degrees of IMR changed in the early and chronic phases after primary PCI. Specifically, MR was identified in 193 of 546 (35%) patients upon arrival at the emergency room. Following PCI, in the acute phase, IMR showed improvement in 63 patients while it worsened in 78 patients. In the chronic phase (6–8 months later), IMR got better in 79 patients, while it got worse in 36 patients [5]. The considerable variability in MR severity makes drawing conclusions more challenging. Furthermore, detailed information on the management of the patients is of utmost importance. Kang et al. [6] compared outcomes in patients with MI and IMR who underwent PCI vs. CABG. For the 45 propensity score-matched pairs, the risk of cardiac events was significantly lower in the surgical group than in the PCI group (hazard ratio [HR], 0.499; 95% CI, 0.251–0.990; $P = 0.043$), though this was before the era of widespread use of transcatheter edge-to-edge repair (TEER). Compared with patients who underwent CABG alone, event-free survival rates were significantly higher in those who underwent additional mitral annuloplasty [6], suggesting that additional mitral intervention could be beneficial. However, this was disputed by Mihaljevic et al. [7] who found that, in patients with moderate/severe

IMR, CABG plus MV annuloplasty reduced postoperative MR and improved early symptoms compared to CABG alone but did not improve long-term functional status or survival.

Data show that revascularization on its own can decrease the severity of ischemic MR in patients experiencing an acute MI, and faster reperfusion time correlates with a more significant reduction in MR severity. However, IMR may persist or even worsen in conjunction with detrimental left ventricular remodeling, even when PCI is successful [8, 9]. Surgical management of IMR is controversial. Some studies suggest that adding mitral annuloplasty to CABG can improve functional capacity, LV reverse remodeling, and reduce MR severity [6, 10]. However, other studies have shown no significant difference in primary or secondary endpoints between CABG with or without mitral valve annuloplasty [7]. Data comparing approaches of MV repair and MV replacement (MVR) for IMR are largely limited to small, non-randomized retrospective studies. The only randomized trial data examining this issue indicated no difference in mortality between MVR and MV repair; however, MVR was consistently associated with higher rates of MR recurrence. Certain echocardiographic features have been reported to predict poor outcomes with MVR and

may help refine the selection of the surgical approach for individual patients [11, 12].

TEER and transcatheter mitral valve replacement (TMVR) are emerging, less-invasive methods for treating select patients with chronic mitral regurgitation. However, numerous recent reports have shown that transcatheter mitral valve repair is a viable option to manage acute severe mitral regurgitation and cardiogenic shock, including cases involving papillary muscle rupture [13–15]. Although surgical intervention is typically the primary treatment for acute severe mitral regurgitation, transcatheter repair has been proposed as a “rescue” procedure for patients with worsening condition following PCI [13–15].

Thus, it would be valuable to stratify patients depending on the management (PCI ± TEER or CABG ± mitral annuloplasty/replacement) as outcomes could differ.

Our proposed management for severe MR complicating acute myocardial infarction is presented in **Figure 1**.

In conclusion, Ładziński et al.'s [2] study adds valuable insights to our understanding of the impact of severe MR on STEMI and NSTEMI patients. The large patient cohort and stratification based on MI type provide a robust basis for the findings.

Article information

Conflict of interest: None declared.

Funding: None.

Open access: This article is available in open access under Creative Commons Attribution-Non-Commercial-No Derivatives 4.0 International (CC BY-NC-ND 4.0) license, which allows downloading and sharing articles with others as long as they credit the authors and the publisher, but without permission to change them in any way or use them commercially. For commercial use, please contact the journal office at kardiologiapolska@ptkardio.pl.

REFERENCES

- Levine RA, Schwammenthal E. Ischemic mitral regurgitation on the threshold of a solution: from paradoxes to unifying concepts. *Circulation*. 2005; 112(5): 745–758, doi: [10.1161/CIRCULATIONAHA.104.486720](https://doi.org/10.1161/CIRCULATIONAHA.104.486720), indexed in Pubmed: 16061756.
- Ładziński S, Niedziela J, Witkowski A, et al. The influence of severe mitral regurgitation on major adverse cardiac and cerebrovascular events after myocardial infarction in 1-year follow-up: Data from PL-ACS registry. *Kardiologia Pol.* 2023; 81(6): 572–579, doi: [10.33963/KP.a2023.0064](https://doi.org/10.33963/KP.a2023.0064), indexed in Pubmed: 36929297.
- Lamas GA, Mitchell GF, Flaker GC, et al. Clinical significance of mitral regurgitation after acute myocardial infarction. Survival and Ventricular Enlargement Investigators. *Circulation*. 1997; 96(3): 827–833, doi: [10.1161/01.cir.96.3.827](https://doi.org/10.1161/01.cir.96.3.827), indexed in Pubmed: 9264489.
- Grigioni F, Enriquez-Sarano M, Zehr K, et al. Ischemic mitral regurgitation. *Circulation*. 2001; 103(13): 1759–1764, doi: [10.1161/01.cir.103.13.1759](https://doi.org/10.1161/01.cir.103.13.1759), indexed in Pubmed: 33919263.
- Nishino S, Watanabe N, Kimura T, et al. The Course of Ischemic Mitral Regurgitation in Acute Myocardial Infarction After Primary Percutaneous Coronary Intervention: From Emergency Room to Long-Term Follow-Up. *Circ Cardiovasc Imaging*. 2016; 9(8): e004841, doi: [10.1161/CIRCIMAGING.116.004841](https://doi.org/10.1161/CIRCIMAGING.116.004841), indexed in Pubmed: 27516478.
- Kang DH, Sun BJ, Kim DH, et al. Percutaneous versus surgical revascularization in patients with ischemic mitral regurgitation. *Circulation*. 2011; 124(11 Suppl): S156–S162, doi: [10.1161/CIRCULATIONAHA.110.011254](https://doi.org/10.1161/CIRCULATIONAHA.110.011254), indexed in Pubmed: 21911806.
- Mihaljevic T, Lam BK, Rajeswaran J, et al. Impact of mitral valve annuloplasty combined with revascularization in patients with functional ischemic mitral regurgitation. *J Am Coll Cardiol*. 2007; 49(22): 2191–2201, doi: [10.1016/j.jacc.2007.02.043](https://doi.org/10.1016/j.jacc.2007.02.043), indexed in Pubmed: 17543639.
- Mentias A, Raza MQ, Barakat AF, et al. Prognostic Significance of Ischemic Mitral Regurgitation on Outcomes in Acute ST-Elevation Myocardial Infarction Managed by Primary Percutaneous Coronary Intervention. *Am J Cardiol*. 2017; 119(1): 20–26, doi: [10.1016/j.amjcard.2016.09.007](https://doi.org/10.1016/j.amjcard.2016.09.007), indexed in Pubmed: 27793397.
- Yousefzai R, Bajaj N, Krishnaswamy A, et al. Outcomes of patients with ischemic mitral regurgitation undergoing percutaneous coronary intervention. *Am J Cardiol*. 2014; 114(7): 1011–1017, doi: [10.1016/j.amjcard.2014.07.012](https://doi.org/10.1016/j.amjcard.2014.07.012), indexed in Pubmed: 25118123.
- Badiwala MV, Verma S, Rao V. Surgical management of ischemic mitral regurgitation. *Circulation*. 2009; 120(13): 1287–1293, doi: [10.1161/CIRCULATIONAHA.108.836627](https://doi.org/10.1161/CIRCULATIONAHA.108.836627), indexed in Pubmed: 19786642.
- Sharma A, Agrawal S, Goel S, et al. Surgical Treatment of Ischemic Mitral Regurgitation: Valve Repair Versus Replacement. *Curr Cardiol Rep*. 2017; 19(1): 3, doi: [10.1007/s11886-017-0813-6](https://doi.org/10.1007/s11886-017-0813-6), indexed in Pubmed: 28101839.
- Ferket BS, Ailawadi G, Gelijns AC, et al. Cost-Effectiveness of Mitral Valve Repair Versus Replacement for Severe Ischemic Mitral Regurgitation: A Randomized Clinical Trial From the Cardiothoracic Surgical Trials Network. *Circ Cardiovasc Qual Outcomes*. 2018; 11(11): e004466, doi: [10.1161/CIRCOUTCOMES.117.004466](https://doi.org/10.1161/CIRCOUTCOMES.117.004466), indexed in Pubmed: 30785252.
- Estévez-Loureiro R, Arzamendi D, Freixa X, et al. Percutaneous Mitral Valve Repair for Acute Mitral Regurgitation After an Acute Myocardial Infarction. *J Am Coll Cardiol*. 2015; 66(1): 91–92, doi: [10.1016/j.jacc.2015.03.597](https://doi.org/10.1016/j.jacc.2015.03.597), indexed in Pubmed: 26139064.
- Valle J, Miyasaka R, Carroll J. Acute Mitral Regurgitation Secondary to Papillary Muscle Tear. *Circulation: Cardiovascular Interventions*. 2017; 10(6), doi: [10.1161/circinterventions.117.005050](https://doi.org/10.1161/circinterventions.117.005050).
- Alkhouli M, Wolfe S, Alqahtani F, et al. The Feasibility of Transcatheter Edge-to-Edge Repair in the Management of Acute Severe Ischemic Mitral Regurgitation. *JACC Cardiovasc Interv*. 2017; 10(5): 529–531, doi: [10.1016/j.jcin.2016.11.056](https://doi.org/10.1016/j.jcin.2016.11.056), indexed in Pubmed: 28216219.