

Acute heart failure in a patient with transposition of the great arteries after an atrial switch procedure: Causes and management of left subpulmonary ventricular dysfunction

Aleksandra Cieplucha¹, Sonia Nartowicz¹, Zofia Staniszc², Wiktoria Cieplucha², Małgorzata Pyda¹, Olga Trojnarśka¹

¹Department of Cardiology, Poznan University of Medical Sciences, Poznań, Poland

²Faculty of Medicine, Poznan University of Medical Sciences, Poznań, Poland

Correspondence to:

Aleksandra Cieplucha, MD, PhD,
1st Department of Cardiology,
Poznan University
of Medical Sciences,
Długa 1/2,
61-848 Poznań, Poland,
phone: +48 61 854 91 46,
e-mail:

aleksandra.cieplucha@skpp.edu.pl

Copyright by the Author(s), 2023

DOI: 10.33963/KPa2023.0088

Received:

November 4, 2022

Accepted:

December 1, 2022

Early publication date:

April 3, 2023

A 36-year-old man after an atrial switch procedure for transposition of great arteries as a result of which the right ventricle becomes a systemic pump presented with symptoms of heart failure decompensation. Four weeks before hospitalization, he had COVID-19. On admission, the patient reported dyspnea on mild exertion, but the prevailing symptoms were ascites and massive edema of the lower limbs suggesting left subpulmonary ventricular (subpulmLV) failure. On the echocardiogram, the subpulmLV was significantly enlarged and dominated over the systemic right ventricle (systRV) (Figure 1). Both ventricles had impaired contractile function. Magnetic resonance imaging excluded COVID-related myocarditis and visualized a thrombus in the left subpulmonary ventricle apex. Due to the presence of a thrombotic mass, oral anticoagulation (apixaban 5 mg b.i.d) was introduced. We raised suspicion of a pulmonary embolism as a contributing factor to the failing subpulmonary chamber. However, a computed tomography angiography scan was not performed due to the significantly decreased creatinine clearance. We considered the exam redundant as it would not have altered the pharmacological management.

Additionally, levosimendan was administered to improve the contractile function of both ventricles and lower the pressure in the pulmonary circulation [1]. We observed a significant improvement in the patient's clinical status and N-terminal pro-B-type natriuretic peptide concentration. The medical therapy with beta-adrenolytics, mineralocorticoid receptor antagonist, and diuretics

was continued after discharge. During the outpatient follow-up, sacubitril/valsartan (S/V) at the minimal dose of 24/26 mg (1/2 tablet b.i.d) was introduced with good tolerance. Stabilization of the hemodynamic status with a marked improvement in contractility of both ventricles was observed in the latest echocardiographic examination after 14 months of follow-up.

This case report documents for the first time the implementation of combined novel pharmacotherapy in the setting of acute heart failure due to subpulmLV decompensation. Beneficial use of levosimendan in patients with the systRV has already been documented [2], however, we found no report on long-term outcomes for such decompensated patients after receiving the novel pharmacotherapy. Levosimendan displays a positive inotropic effect through sensitizing myocytes to calcium and has a vasodilating effect through the ATP-dependent potassium channels in the vascular smooth muscles [1, 2]. These facts further justified our strategy as we suspected the pulmonary thromboembolism with raised pulmonary pressures to be the reason for decompensation.

The results of studies on the use of sacubitril/valsartan in patients with congenital heart disease are scarce. Nevertheless, Zandstar et al. [3] observed that in patients with systRV failure, S/V decreased the concentration of N-terminal pro-B-type natriuretic peptide and improved the echocardiographic parameters and clinical status. According to a meta-analysis by Zhang et al. [4], S/V demonstrated a beneficial effect in the setting of RV failure

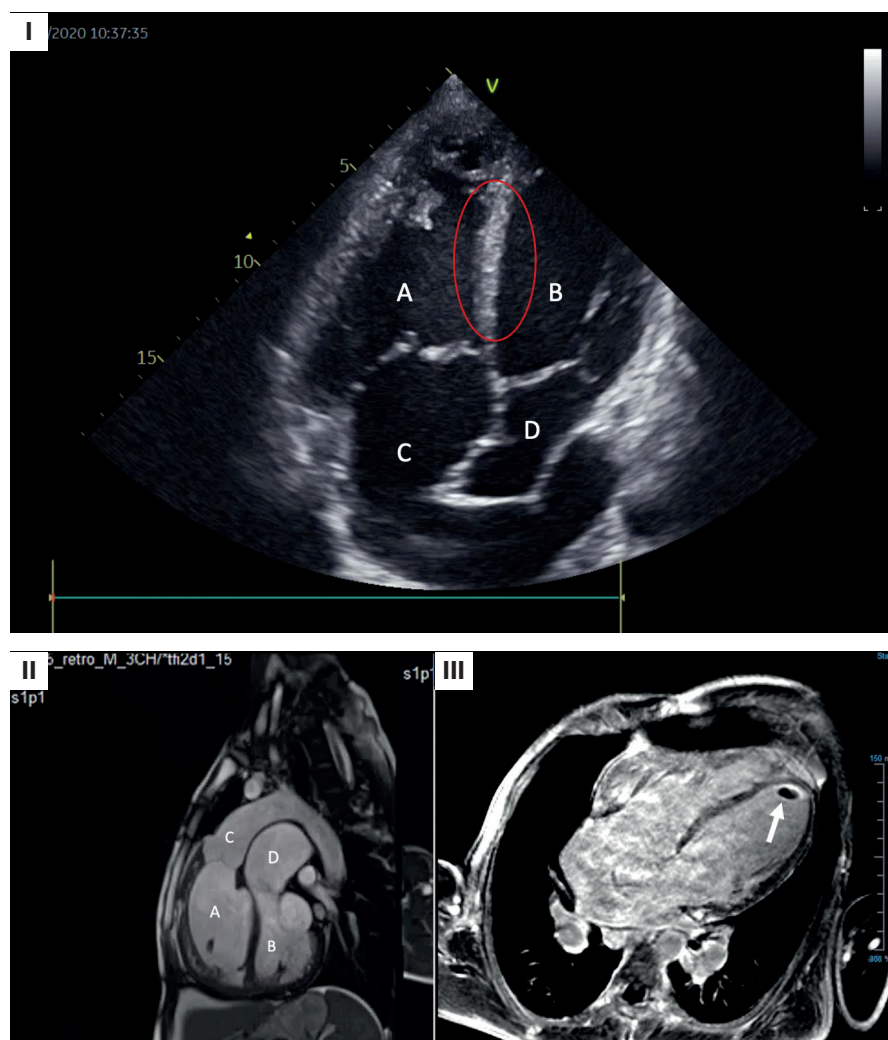


Figure 1. I. Echocardiographic image of the patient on admission. Apical four-chamber view showing the enlargement of the subpulmonary ventricle and features of increased pressure in the pulmonary circulation visualised as bulging of the interventricular septum towards the systemic chamber (marked with the red circle). **IA.** Systemic right ventricle. **IB.** Subpulmonary left ventricle. **IC.** Systemic baffle. **ID.** Pulmonary baffle. **II, III.** Cardiac magnetic resonance. **II.** Sagittal plane: **IIA.** Systemic right ventricle. **B.** Subpulmonary left ventricle. **IIC.** Aorta. **IID.** Dilated pulmonary trunk. **III.** Transverse plane; arrow indicates the thrombus in the apex of the left subpulmonary ventricle

and pulmonary hypertension. Since our patient demonstrated overt symptoms of subpulmonary ventricle failure, we decided to implement this drug.

In patients with transposition of great arteries after atrial repair, progressive failure of the systRV is a predictor of poor prognosis [5]. Nevertheless, factors that might worsen the function of the left subpulmonary ventricle should not be ignored. Modern treatment of heart failure, including levosimendan and sacubitril/valsartan, may also be effective in patients with congenital heart diseases.

Article information

Conflict of interest: None declared.

Funding: None.

Open access: This article is available in open access under Creative Commons Attribution-Non-Commercial-No Derivatives 4.0 International (CC BY-NC-ND 4.0) license, which allows downloading and sharing articles with others as long as they credit the authors and the publisher, but without permission to change them in any way or use them commercially. For commercial use, please contact the journal office at kardiologiapolska@ptkardio.pl.

REFERENCES

- Hansen MS, Andersen A, Nielsen-Kudsk JE. Levosimendan in pulmonary hypertension and right heart failure. *Pulm Circ.* 2018; 8(3): 2045894018790905, doi: [10.1177/2045894018790905](https://doi.org/10.1177/2045894018790905), indexed in Pubmed: [29979110](https://pubmed.ncbi.nlm.nih.gov/29979110/).
- Mantziari L, Kamperidis V, Giannakoulas G. Levosimendan in congenitally corrected transposition of the great arteries: a case report. *Open Cardiovasc Thorac Surg J.* 2012; 5(1): 24–26, doi: [10.2174/1876533501205010024](https://doi.org/10.2174/1876533501205010024).
- Zandstra TE, Nederend M, Jongbloed MRM, et al. Sacubitril/valsartan in the treatment of systemic right ventricular failure. *Heart.* 2021; 107(21): 1725–1730, doi: [10.1136/heartjnl-2020-318074](https://doi.org/10.1136/heartjnl-2020-318074), indexed in Pubmed: [33452121](https://pubmed.ncbi.nlm.nih.gov/33452121/).
- Zhang J, Du L, Qin X, et al. Effect of sacubitril/valsartan on the right ventricular function and pulmonary hypertension in patients with heart failure with reduced ejection fraction: a systematic review and meta-analysis of observational studies. *J Am Heart Assoc.* 2022; 11(9): e024449, doi: [10.1161/JAHA.121.024449](https://doi.org/10.1161/JAHA.121.024449), indexed in Pubmed: [35470677](https://pubmed.ncbi.nlm.nih.gov/35470677/).
- Nartowicz SA, Jakielska E, Cieplucha A, et al. Clinical factors affecting survival in patients with D-transposition of the great arteries after atrial switch repair: A meta-analysis. *Kardiol Pol.* 2023; 81(1): 38–47, doi: [10.33963/KP.a2022.0209](https://doi.org/10.33963/KP.a2022.0209), indexed in Pubmed: [36082795](https://pubmed.ncbi.nlm.nih.gov/36082795/).