

Stenting of a non-stenosed left main coronary artery in a 16-month-old infant resulting in a significant hemodynamic improvement

Artur Pawlik¹, Jacek Kołcz², Judyta Szeliga³, Stanisław Bartus^{1,4}, Sebastian Góreczny³

¹Department of Cardiology and Cardiovascular Interventions, University Hospital, Kraków, Poland

²Department of Pediatric Cardiac Surgery, University Children's Hospital, Jagiellonian University Medical College, Kraków, Poland

³Department of Pediatric Cardiology, University Children's Hospital, Jagiellonian University Medical College, Kraków, Poland

⁴Institute of Cardiology, Jagiellonian University Medical College, Kraków, Poland

Correspondence to:

Sebastian Góreczny, MD, PhD,
Department of Pediatric
Cardiology,
University Children's Hospital,
Faculty of Medicine, Jagiellonian
University Medical College,
Wielicka 265,
30-669 Kraków, Poland,
phone: +48 12 333 90 50,
e-mail:
sebastian.goreczny@uj.edu.pl

Copyright by the Author(s), 2023

DOI: 10.33963/KPa2023.0053

Received:

December 24, 2022

Accepted:

February 5, 2023

Early publication date:

February 28, 2023

A 16-month-old baby girl with suspected Alagille syndrome was referred to the pediatric cardiac surgery department due to severe left and right ventricular outflow tract obstruction.

The ascending aorta was opened using hockey-stick aortotomy longitudinally toward the non-coronary sinus. The tricuspid aortic valve was visualized. All leaflets of the valve were thickened and asymmetrical, with the left coronary leaflet severely hypoplastic and fused with the aortic wall. The entrance to the left sinus of Valsalva was severely narrowed to a diameter of 2 mm, impairing blood inflow to the left coronary artery. In addition, the larger right coronary leaflet partially overlapped the hypoplastic left leaflet, which additively impaired the inflow to the left sinus of Valsalva. The fibrous tissue narrowing the left coronary sinus was partially resected. The ascending aorta was widened with a diamond-shaped Goretex patch extending into the non-coronary sinus.

After reperfusion and rewarming, severe tachyarrhythmias and several episodes of ventricular fibrillation were ceased with electrical shocks. Due to the hemodynamic instability of the patient, mechanical support of the circulatory system was commenced.

An echocardiogram showed akinesia of the free wall of the left ventricle and the interventricular septum. Subsequent aortography showed flow through the left coronary artery impaired by the left coronary leaflet tissue (Figures 1A, B; Supplementary material, Video S1). Selective angiography of the artery

showed a normal course without narrowing (Figure 1C). The multidisciplinary Heart Team, consisting of a cardiac surgeon, pediatric and adult coronary interventional cardiologists, decided to implant a stent in the left main coronary artery and extend it to the aorta lumen to improve perfusion. An H-Stick catheter was placed in the ostium of the left coronary artery. A drug-eluting 3.5 × 8 mm Xience Pro S stent (Abbot Laboratories, Abbott Park, IL, US) was deployed in the ostium extending to the lumen of the aorta. Control aortography showed improved flow in the left coronary artery (Figure 1D; Supplementary material, Video S2). The procedure had no complications. In the post-procedural course, gradual improvement of the left ventricular systolic function and hemodynamics allowed for weaning of the mechanical circulatory support.

Percutaneous coronary artery interventions in the pediatric population are extremely rare. The absence of dedicated hardware results in many technical difficulties and potentially serious complications. Most common pediatric coronary artery interventions are performed in patients with Kawasaki syndrome, post-transplant vasculopathy, or after surgical operations involving coronary ostia. Literature regarding these procedures in infants is scarce and consists of several case reports and series suggesting acceptable long-term results with emphasis on good stent dilatation and dual antiplatelet therapy after the procedure [1, 2]. It is also crucial to consider coronary stenting in the context of the child's growth and use stents that are

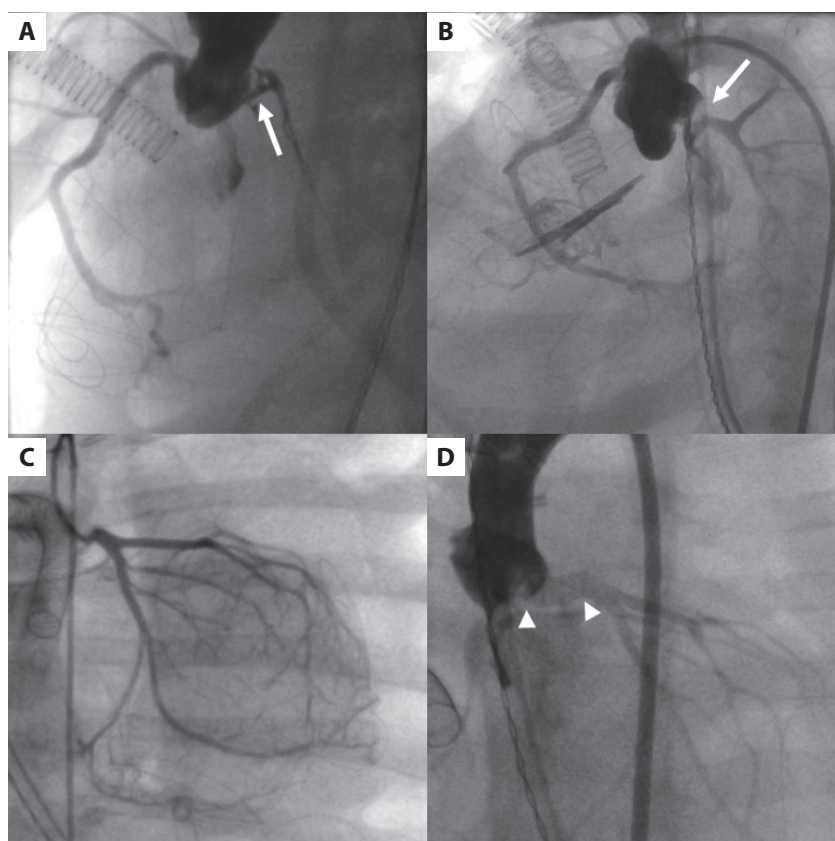


Figure 1. Stenting of a non-stenosed left coronary artery in an infant on circulatory support. **A, B.** Initial aortography exposing obstructed left coronary artery perfusion caused by the tissue flap in the ostium (white arrows). **C.** Selective angiography of the left coronary artery with a non-stenosed stem of the artery. **D.** Final aortography presenting improved blood flow of the left coronary artery with a tissue flap buried under the implanted stent (white arrowheads). The function of the aortic valve did not deteriorate on further observation

capable of being dilated in the future. In the presented procedure, the diameter of the implanted stent may be expanded up to 5.5 mm which is sufficient for most adults.

The presented case concerned a critically-ill infant who had undergone stenting of a non-stenosed left coronary artery allowing weaning from the mechanical support of the circulatory system.

Supplementary material

Supplementary material is available at https://journals.viamedica.pl/kardiologia_polska.

Article information

Acknowledgments: To Anna Grondalski from Medical University of Szczecin for editing the text.

Conflict of interest: None declared.

Funding: None.

Open access: This article is available in open access under Creative Commons Attribution-Non-Commercial-No Derivatives 4.0 International (CC BY-NC-ND 4.0) license, which allows downloading and sharing articles with others as long as they credit the authors and the publisher, but without permission to change them in any way or use them commercially. For commercial use, please contact the journal office at kardiologiapolska@ptkardio.pl.

REFERENCES

1. Bratincák A, Salkini A, El-Said HG, et al. Percutaneous stent implantation into coronary arteries in infants. *Catheter Cardiovasc Interv.* 2012; 79(2): 303–311, doi: [10.1002/ccd.23173](https://doi.org/10.1002/ccd.23173), indexed in Pubmed: [22271558](https://pubmed.ncbi.nlm.nih.gov/22271558/).
2. Callahan R, Lock JE, Shah PB, et al. Transcatheter intervention of coronary obstructions in infants, children, and young adults. *Pediatr Cardiol.* 2018; 39(7): 1299–1307, doi: [10.1007/s00246-018-1894-8](https://doi.org/10.1007/s00246-018-1894-8), indexed in Pubmed: [29744657](https://pubmed.ncbi.nlm.nih.gov/29744657/).