

# Byrd sheaths for complex inferior vena cava filter retrieval: Results of a preliminary study

Maciej Szmygin<sup>1</sup>, Wanesa Góralczyk<sup>2</sup>, Damian Wach<sup>2</sup>, Tomasz Jargiełło<sup>1</sup>, Krzysztof Pyra<sup>1</sup>

<sup>1</sup>Department of Interventional Radiology and Neuroradiology, Medical University of Lublin, Lublin, Poland

<sup>2</sup>Students' Scientific Society at the Department of Interventional Radiology and Neuroradiology, Medical University of Lublin, Lublin, Poland

## Correspondence to:

Maciej Szmygin, MD, PhD,  
Department of Interventional  
Radiology and Neuroradiology,  
Medical University of Lublin,  
Jaczewskiego 8, 20–090 Lublin,  
Poland,  
phone: +48 509 679 033,  
e-mail: mszmygin@gmail.com

Copyright by the Author(s), 2023

DOI: 10.33963/KPa2023.0041

## Received:

November 11, 2022

## Accepted:

January 15, 2023

## Early publication date:

February 11, 2023

## INTRODUCTION

Inferior vena cava filters (IVCF) are indicated as a preventive treatment of pulmonary embolism in high-risk patients (e.g., with failed or absolute contraindication to pharmacological anticoagulation, venous thromboembolism, poor cardiopulmonary reserve) [1, 2]. The introduction of retrievable IVCF and its approval for various elective indications led to a significant rise in filter placement in the early 2000s [3]. The downside of the IVCF expansion is the fact that long-indwelling filters are associated with many potential complications including both thrombotic and non-thrombotic events as well as vessel injury [4, 5]. That is why it is recommended to remove IVCFs as soon as they are no longer indicated, particularly in younger patients. All this led to a gradual decrease in filter utilization and a trend to retrieve long indwelling retrievable filters [6].

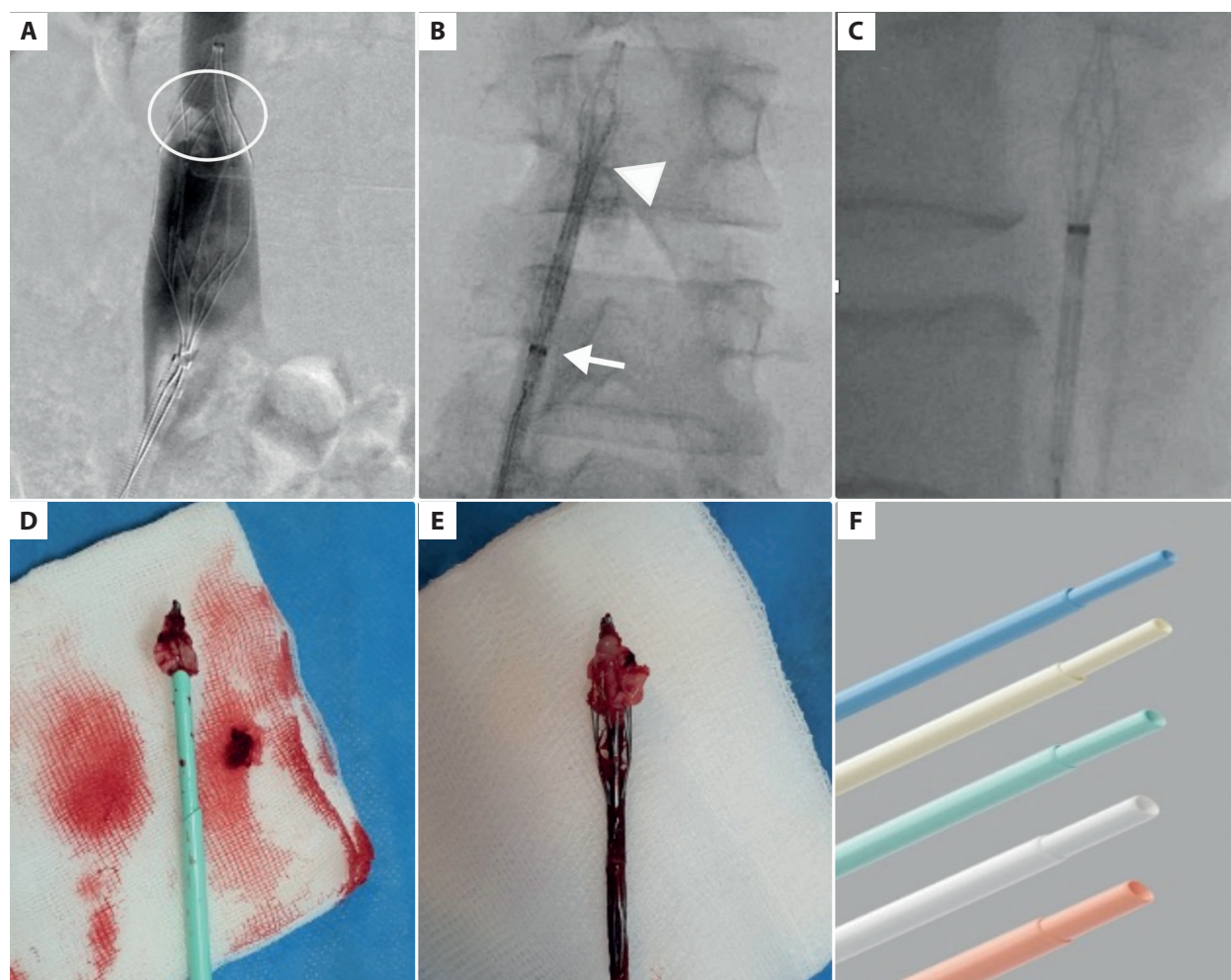
Although a majority of IVCFs can be removed without difficulty, in some cases (embedded hooks, filter penetration into the vessel wall, or severe filter tilt), the removal might be particularly challenging. In order to improve retrieval success among patients with embedded filters, several advanced methods have been proposed [7, 8]. Recently, Kuo et al. [9] published a study conducted on 500 patients which showed that the excimer laser sheath technique is safe and effective in removing almost all types and lengths of embedded IVCF. In 2022, Yu et al. [10] compared this method to forceps-assisted IVCF removal and observed that whereas the use of laser is associated with a higher retrieval rate, there are no significant differences in terms of procedural safety.

Byrd sheaths which are commonly used in pacemaker lead extraction might be an

alternative for dissecting and removing embedded IVCF, especially in countries where excimer laser sheaths are not allowed for ICVF retrieval [11]. This report aims to present our preliminary results with Byrd-assisted removal of embedded IVCF.

## METHODS

This study involved trauma patients who underwent prophylactic implantation of retrievable OptEase inferior vena cava filter (Cordis Corporation, Miami Lakes, FL, US) in the prevention of pulmonary embolism and were afterward referred for filter retrieval between 2019 and 2022. During this period, disruptions in nonemergency medical care access and delivery were observed due to the COVID-19 pandemic which resulted in an increased number of patients with prolonged indwelling IVCF. The study group comprised the patients in whom Byrd sheaths (Byrd Dilator Sheath Polypropylene, Cook Medical, Cook Inc., Bloomington, IN, US) were used to remove IVCF. In all cases, initial retrieval was attempted in local anesthesia from a femoral approach using the “snare-and-sheath” technique after cavography excluding the presence of intrafilter thrombi. A decision on Byrd dilators' application was made either after our inability to sheathe the filter after multiple attempts or the patients reporting pain due to applied force. The size of used Byrd sheaths varied from 10 F to 16 F. Byrd sheaths were gradually advanced over the guidewire to peel the adhesion tissue surrounding the IVCF. Once it was achieved, the filter was withdrawn via the femoral vein. In all cases, control cavography was performed. Procedural details, complication rates, and the overall retrieval rate were assessed. Minor



**Figure 1.** A 47-year-old female patient was admitted for IVCF retrieval 6 months after filter implantation. Initial cavography showed filter ingrowth into the caval wall (A). After several attempts with the traditional technique, the Byrd dilatator (white triangle) was introduced via the vascular sheath (white arrow) (B). Successful peeling of the adhesion tissue was performed, and the filter was slipped into the sheath (C). Adhesion tissue and the Byrd dilatator were removed (D, E). Available sizes of Byrd sheaths (F)

complications included abdominal pain and transient inferior vena cava (IVC) stenosis. Major complications were defined as IVC walls rupture or permanent vessel stenosis.

All patients gave their informed consent to participate in the study, and the institutional ethics review board approved it.

### Statistical analysis

All statistical analyses were conducted using StatSoft Statistica 13.1 package. Data were presented as mean and range for continuous variables and as counts and percentages for categorical variables.

## RESULTS AND DISCUSSION

In total, 10 trauma patients were enrolled in the study. From this group, 4 patients were female (40%), and the mean age of the patients was 42 years (ranging from 23 to 65 years; mean [standard deviation [SD], 12.6). Mean time from filter implantation to removal was 121 days (range from 31 to 260 days; SD, 70.1). The initial procedure was successful in 7 patients (70%). Three patients reported abdominal pain

and were scheduled for a secondary procedure in conscious sedation. In that group, the retrieval was successful in further 2 cases, which resulted in an overall procedural success rate of 90% (9/10 patients). In 1 case, the procedure was unsuccessful, and the patient was instructed about a lifetime anticoagulation regimen. No major complications were noted. In terms of minor complications, abdominal pain was reported in the previously mentioned 3 cases (30%), and mild IVC stenosis was found at the site of the removed filter in 2 patients (20%). In these cases, antiplatelet therapy was recommended for 3–4 weeks, and control cavography was performed after that period. No residual stenosis was observed in the follow-up examination (Figure 1).

Whereas the majority of retrievable IVCFs are cone-shaped and are removed from jugular access, the Optease is a diamond-shaped filter that is retrieved from femoral access. Because of the filter's structure and its adherence to the caval wall, it is recommended to retrieve it earlier than conical filters. According to Rimón et al., recommended retrieval times for the conical filters range from 59 to 140 days on average, whereas removal of Optease filters should be

performed within first few weeks after implantation [12]. Rosenthal et al. recommended repositioning the Optease filters to another location in the IVC after 21 days to prevent intimal growth over the filter struts if removal is not yet indicated [13]. Nonetheless, the main advantage of Optease IVCF is its ease of handling which is particularly important in trauma patients, and that is why these filters are commonly used. Considering the time limitations of Optease IVCF, our center's current removal policy is to attempt removal or repositioning within 3–4 weeks. However, as mentioned before, the COVID-19 pandemic led to significant disturbances in medical care resulting in the increase in prolonged filter dwell time. In the present study, we found that Byrd sheaths might be successfully used as an advanced filter retrieval technique also after a very long dwell time (over 8 months). This is a valuable finding, because according to Desai et al. [14], the likelihood of retrieval failure beyond 7 months is over 40% without advanced techniques. In addition to that, the rate of procedural complications is acceptably low and comparable with the results described by other authors [9, 14, 15].

We are aware that our report has several limitations. The main limitations of our study are the small sample size of enrolled patients, which limits the validity of the data, and its retrospective nature. Additionally, the absence of a control group treated with other methods might be perceived as a potential drawback.

In conclusion, this case series indicates that Byrd-assisted removal of embedded inferior vena cava filters is a feasible and safe technique that could potentially improve the IVCF removal rate and should be, therefore, considered an interesting addition to the advanced techniques' spectrum.

### Article information

**Conflict of interest:** None declared.

**Funding:** None.

**Open access:** This article is available in open access under Creative Commons Attribution-Non-Commercial-No Derivatives 4.0 International (CC BY-NC-ND 4.0) license, which allows downloading and sharing articles with others as long as they credit the authors and the publisher, but without permission to change them in any way or use them commercially. For commercial use, please contact the journal office at [kardiologiapolska@ptkardio.pl](mailto:kardiologiapolska@ptkardio.pl).

### REFERENCES

1. Kaufman JA, Kinney TB, Streiff MB, et al. Guidelines for the use of retrievable and convertible vena cava filters: report from the Society of Interventional Radiology multidisciplinary consensus conference. *J Vasc Interv Radiol.* 2006; 17(3): 449–459, doi: [10.1097/01.rvi.0000203418-39769.0d](https://doi.org/10.1097/01.rvi.0000203418-39769.0d), indexed in Pubmed: 16567669.
2. Partovi S, Davidson JC, Patel IJ. Implications and limitations of the PREPIC2 study—the interventionist's perspective. *Cardiovasc Diagn Ther.* 2016; 6(3): 259–261, doi: [10.21037/cdt.2016.01.03](https://doi.org/10.21037/cdt.2016.01.03), indexed in Pubmed: 27280089.
3. Stein PD, Matta F, Hull RD. Increasing use of vena cava filters for prevention of pulmonary embolism. *Am J Med.* 2011; 124(7): 655–661, doi: [10.1016/j.amjmed.2011.02.021](https://doi.org/10.1016/j.amjmed.2011.02.021), indexed in Pubmed: 21592452.
4. Jia Z, Wu A, Tam M, et al. Caval penetration by inferior vena cava filters: a systematic literature review of clinical significance and management. *Circulation.* 2015; 132(10): 944–952, doi: [10.1161/CIRCULATIONAHA.115.016468](https://doi.org/10.1161/CIRCULATIONAHA.115.016468), indexed in Pubmed: 26169756.
5. PREPIC Study Group. Eight-year follow-up of patients with permanent vena cava filters in the prevention of pulmonary embolism: the PREPIC (Prevention du Risque d'Embolie Pulmonaire par Interruption Cave) randomized study. *Circulation.* 2005; 112(3): 416–422, doi: [10.1161/CIRCULATIONAHA.104.512834](https://doi.org/10.1161/CIRCULATIONAHA.104.512834), indexed in Pubmed: 16009794.
6. Li X, Haddadin I, McLennan G, et al. Inferior vena cava filter – comprehensive overview of current indications, techniques, complications and retrieval rates. *Vasa.* 2020; 49(6): 449–462, doi: [10.1024/0301-1526/a000887](https://doi.org/10.1024/0301-1526/a000887), indexed in Pubmed: 32660360.
7. Kuo WT, Odegaard JI, Rosenberg JK, et al. Laser-Assisted removal of embedded vena cava filters: A 5-year first-in-human study. *Chest.* 2017; 151(2): 417–424, doi: [10.1016/j.chest.2016.09.029](https://doi.org/10.1016/j.chest.2016.09.029), indexed in Pubmed: 27729265.
8. Itagaki T, Okada A, Tabata H, et al. Successful inferior vena cava filter removal using pacemaker lead extraction methods. *J Cardiol Cases.* 2019; 19(4): 129–132, doi: [10.1016/j.jccase.2018.12.012](https://doi.org/10.1016/j.jccase.2018.12.012), indexed in Pubmed: 30996759.
9. Kuo WT, Doshi AA, Ponting JM, et al. Laser-Assisted removal of embedded vena cava filters: A first-in-human escalation trial in 500 patients refractory to high-force retrieval. *J Am Heart Assoc.* 2020; 9(24): e017916, doi: [10.1161/JAHA.119.017916](https://doi.org/10.1161/JAHA.119.017916), indexed in Pubmed: 33252283.
10. Yu Q, Tran P, Iyer D, et al. Rigid forceps and excimer laser use for complex inferior vena cava filter retrieval: a preliminary quantitative analysis of available evidence. *CVIR Endovasc.* 2022; 5(1): 33, doi: [10.1186/s42155-022-00311-4](https://doi.org/10.1186/s42155-022-00311-4), indexed in Pubmed: 35802261.
11. Anzai H, Takaesu S, Yaguchi T, et al. Bidirectional sling technique with biopsy forceps for inferior vena cava filter retrieval. *Ann Vasc Dis.* 2021; 14(3): 277–280, doi: [10.3400/avd.hdi.20-00097](https://doi.org/10.3400/avd.hdi.20-00097), indexed in Pubmed: 34630774.
12. Rimon U, Bensaid P, Golan G, et al. Optease vena cava filter optimal indwelling time and retrievability. *Cardiovasc Interv Radiol.* 2011; 34(3): 532–535, doi: [10.1007/s00270-010-9920-0](https://doi.org/10.1007/s00270-010-9920-0), indexed in Pubmed: 20556385.
13. Rosenthal D, Wellons ED, Lai KM, et al. Retrievable inferior vena cava filters: initial clinical results. *Ann Vasc Surg.* 2006; 20(1): 157–165, doi: [10.1007/s10016-005-9390-z](https://doi.org/10.1007/s10016-005-9390-z), indexed in Pubmed: 16378141.
14. Desai KR, Laws JL, Salem R, et al. Defining prolonged dwell time: when are advanced inferior vena cava filter retrieval techniques necessary? An analysis in 762 procedures. *Circ Cardiovasc Interv.* 2017; 10(6), doi: [10.1161/CIRCINTERVENTIONS.116.003957](https://doi.org/10.1161/CIRCINTERVENTIONS.116.003957), indexed in Pubmed: 28606998.
15. Al-Hakim R, Kee ST, Olinger K, et al. Inferior vena cava filter retrieval: effectiveness and complications of routine and advanced techniques. *J Vasc Interv Radiol.* 2014; 25(6): 933–9; quiz 940, doi: [10.1016/j.jvir.2014.01.019](https://doi.org/10.1016/j.jvir.2014.01.019), indexed in Pubmed: 24630748.