

Needle in a haystack: Needle wandering to the heart

Kamil Baczewski¹, Krzysztof Olszewski¹, Marek Czajkowski¹, Michał Sojka², Jacek Zawiślak³,
Klaudia Artykiewicz³, Janusz Stążka¹

¹Department of Cardiac Surgery, Medical University of Lublin, Lublin, Poland

²Department of Interventional Radiology and Neuroradiology, Medical University of Lublin, Lublin, Poland

³Department of Cardiology, Medical University of Lublin, Lublin, Poland

Correspondence to:

Kamil Baczewski, MD, PhD,
Department of Cardiac Surgery,
Medical University of Lublin,
Żwirki i Wigury 4/16
20-029 Lublin, Poland,
phone: +48 537 493 963,
e-mail:
drkamilbaczewski@gmail.com

Copyright by the Author(s), 2023

DOI: 10.33963/KPa.2022.0270

Received:

September 30, 2022

Accepted:

November 9, 2022

Early publication date:

November 28, 2022

Chest trauma can be classified as either penetrating or blunt trauma. Blunt trauma is more common, but penetrating trauma can be seriously life-threatening. Stab injuries account for 9.5% of thoracic penetrating injuries, making them the most common etiology of penetrating injuries [1]. Injuries caused by self-harm or attempted suicide are very rare. The first successful suturing of a heart wound was performed by Ludwig Rehn in 1896. This groundbreaking operation ushered in the era of cardiac surgery [2].

A 72-year-old woman was admitted to a psychiatric ward after a suicide attempt. From the medical interview, the patient stuck a sewing needle in her chest. Chest X-ray and physical examination confirmed the location of the needle in the subcutaneous tissue (Figure 1A). Due to the stable condition of the patient and the location of the foreign body, the patient was qualified for observation. After 3 days, the patient developed non-specific chest complaints. A control chest X-ray showed needle displacement from the

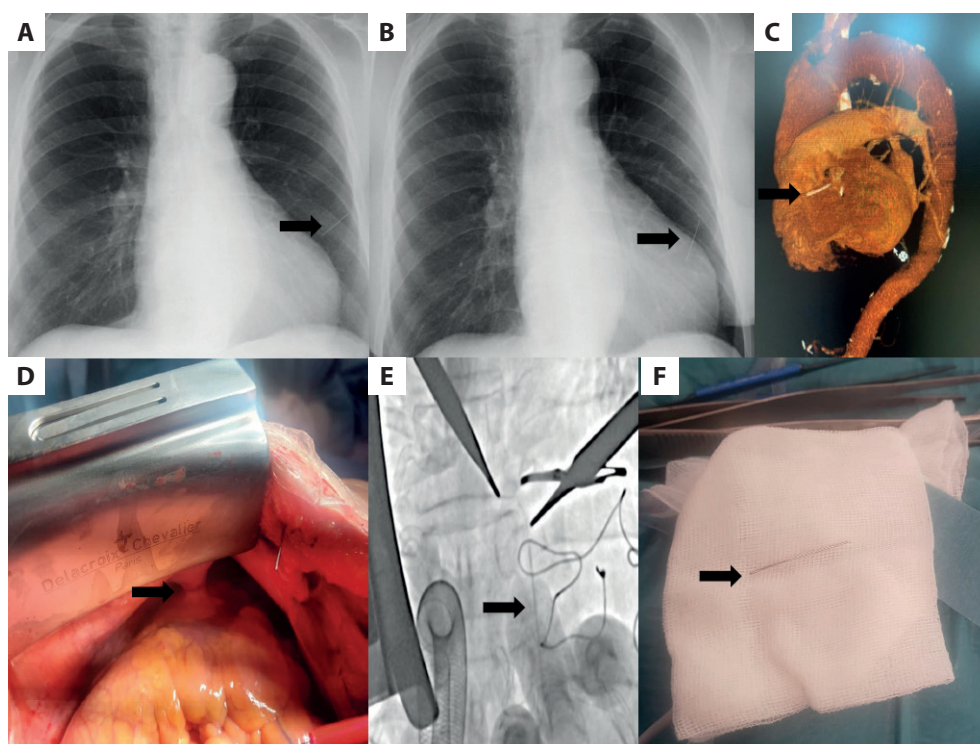


Figure 1. **A.** First chest X-ray: the needle in the subcutaneous tissue (arrow). **B.** Second chest X-ray: the needle in the pericardial sac (arrow). **C.** Computed tomography scan: the foreign body near outflow path of the right ventricle (arrow). **D.** Intraoperative image: fusion in the pericardial sac (arrow). **E.** Live X-ray image: confirmed localization of the needle (arrow). **F.** The needle after removal (arrow)

subcutaneous tissue to the pericardial sac (Figure 1B). The patient was transferred to the cardiosurgical ward to improve the diagnosis and qualify for surgical treatment. On admission, the patient was cardiovascularly stable, without tamponade. On physical examination, there was no sign of the puncture on the chest wall. Due to age, according to the European Association for Cardio-Thoracic Surgery guidelines, coronary angiography was performed before the procedure to exclude coronary artery disease. In order to confirm the localization of the foreign body, computed tomography (CT) of the chest was performed, which confirmed further displacement of the foreign body into the outflow tract of the right ventricle. Even though this is a highly arrhythmogenic area, no arrhythmias were observed during hospitalization (Figure 1C). Before surgery, the patient was consulted by an interventional radiologist. There was a risk of the lasso loop slipping off the needle (the needle material is too hard and cannot be bent or broken like stents or pacemaker wires by intravascular tools), and therefore endovascular removal was impossible. The patient was qualified for cardiac surgery in the hybrid operating room. After sternotomy, a fusion was found in the pericardial sac, probably corresponding to the point where the needle entered the heart (Figure 1D). Under

X-ray control, the foreign body was located near the outflow tract from the right ventricle (Figure 1E). After opening the right ventricle, the needle was surgically removed (Figure 1F). The right ventricle was sutured with stitches on the pads. After the operation, the patient was transferred to the intensive care unit, where she stayed for 3 days. The course of hospitalization was without complications. After psychiatric consultation, the patient was discharged home in good general condition.

Article information

Conflict of interest: None declared.

Funding: None.

Open access: This article is available in open access under Creative Commons Attribution-Non-Commercial-No Derivatives 4.0 International (CC BY-NC-ND 4.0) license, which allows downloading and sharing articles with others as long as they credit the authors and the publisher, but without permission to change them in any way or use them commercially. For commercial use, please contact the journal office at kardiologiapolska@ptkardio.pl.

REFERENCES

1. Jain A, Sekusky AL, Burn B. Penetrating chest trauma. In: StatPearls 2021.
2. Blatchford J. Ludwig Rehn: the first successful cardiorrhaphy. *Ann Thorac Surg.* 1985; 39(5): 492–495, doi: [10.1016/s0003-4975\(10\)61972-8](https://doi.org/10.1016/s0003-4975(10)61972-8), indexed in Pubmed: [3888132](https://pubmed.ncbi.nlm.nih.gov/3888132/).