

Myocardial infarction with nonobstructive coronary arteries in a woman: Takotsubo cardiomyopathy or true myocardial infarction?

Maria Łoboz-Rudnicka¹, Bartłomiej Kędzierski^{2,3}, Jagoda Młynarczyk¹, Krystian Truszkiewicz^{2,3}, Rafał Wyderka¹, Barbara Brzezińska¹, Joanna Jaroch^{1,4}

¹Department of Cardiology, Marciniak Lower Silesian Specialist Hospital — Emergency Medicine Center, Wrocław, Poland

²Department of Radiology and Imaging Diagnostics, Marciniak Lower Silesian Specialist Hospital — Emergency Medicine Center, Wrocław, Poland

³University Center for Imaging Diagnostics, University Clinical Hospital in Wrocław, Wrocław, Poland

⁴Faculty of Health Sciences, Wrocław Medical University, Wrocław, Poland

Correspondence to:

Maria Łoboz-Rudnicka, MD, PhD,
Department of Cardiology,
Marciniak Lower Silesian
Specialist Hospital – Emergency
Medicine Center,
Fieldorfa 2,
54–049 Wrocław, Poland,
phone: + 48 71 306 47 02,
e-mail: marialoboz@o2.pl
Copyright by the Author(s),
2022

DOI: 10.33963/KPa2022.0176

Received:

June 1, 2022

Accepted:

September 8, 2022

Early publication date:

September 27, 2022

Myocardial infarction with nonobstructive coronary arteries (MINOCA) is a working diagnosis for patients with a manifestation of myocardial infarction, no significant coronary stenosis on angiography, and no other specific pathology responsible for acute presentation [1]. Patients with MINOCA constitute a diagnostic and therapeutic challenge in everyday practice. Diagnostic algorithms recommend several tests, including cardiac magnetic resonance (CMR) [1]. Recent studies underscore the important role of early CMR (median: 3 days from index event), which allows for establishing the diagnosis in 77% of patients, with Takotsubo cardiomyopathy (TC; 33%), myocardial infarction (22%), and myocarditis (17%) as most frequent pathologies [2]. We present this case to underscore the role of (1) early CMR in the diagnostic algorithm of MINOCA; (2) ischemic cause of MINOCA in women.

A 52-year-old hypertensive woman presented to the emergency department with 24-hour recurrent chest pain. The electrocardiogram showed abnormalities typical of inferior ST-segment elevation myocardial infarction. Coronary angiography revealed minimal luminal irregularities (Supplementary material, *Videos S1–S6*). In the laboratory tests, the troponin T and CK-MB (creatine kinase-muscle/brain) levels were elevated (695 pg/ml, 44.6 U/l), while other parameters were within the normal range. Echocardiography showed akinetic apex and apical segments of the left ventricle with mildly reduced left ventricular

ejection fraction (LVEF) — 45%. The patient reported emotional stress in the previous weeks. Given female sex, history of emotional stress, no obstructive coronary stenosis on angiography, and the echocardiographic presentation, the initial diagnosis of TC was established. The control echocardiography performed on day 4 showed improvement in LVEF (52%) with partial resolution of wall motion abnormalities, which was another argument for the diagnosis of TC. To confirm the initial diagnosis, CMR was performed on day 4.

CMR revealed preserved LVEF (50%) and akinesis of apical inferior segment and adjacent fragment of apical septal segment of the left ventricle. Within the akinetic segments, edema on T2-weighted imaging with fat suppression and subendocardial lesion in late gadolinium enhancement sequences were detected (**Figure 1A–D**). Stress CMR with regadenoson showed subendocardial ischemia (**Figure 1E** and Supplementary material, *Video S7*). Ultimately, the diagnosis was changed into myocardial infarction. Twelve-month dual antiplatelet therapy (aspirin and clopidogrel) along with a statin, beta-adrenergic receptor blocker, and angiotensin-converting enzyme inhibitor were recommended, and the patient was referred for cardiac rehabilitation. The control MR performed 12 weeks after the index event confirmed the presence of post-myocardial scar within the apical inferior and apical septal segments (**Figure 1F**).

In our case, early CMR allowed for establishment of proper diagnosis and implemen-

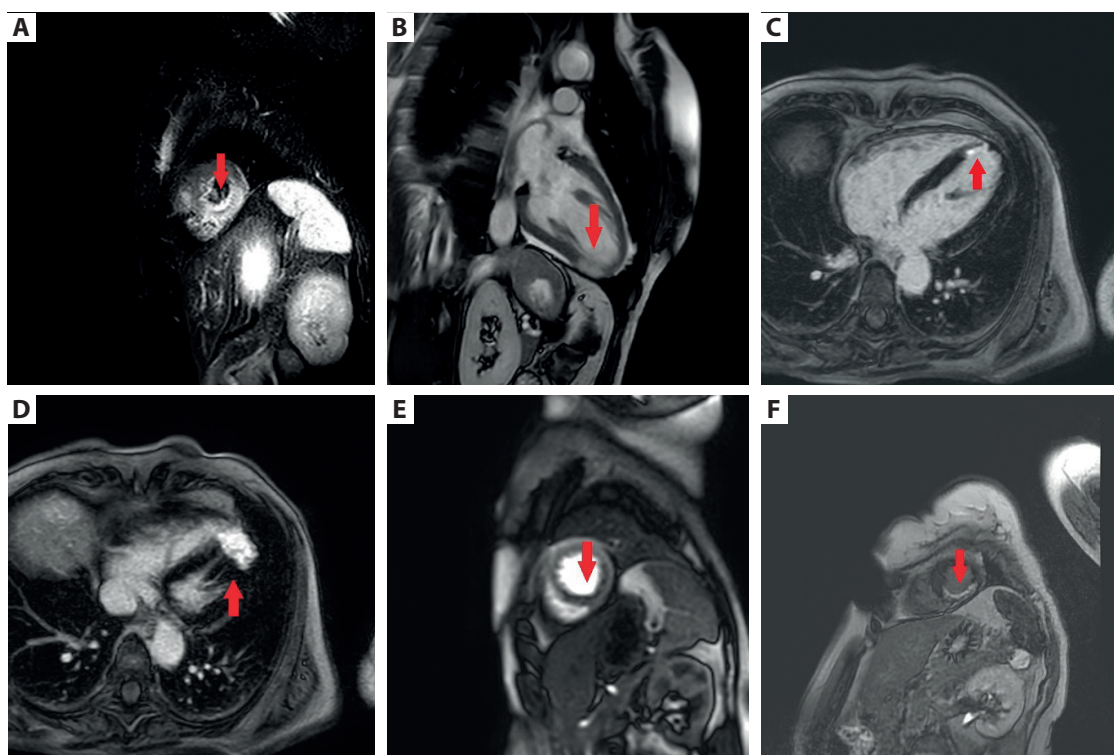


Figure 1. A–E. Initial examination. **A.** T2-STIR image, short axis view: transmuralsignal hyperintensity (myocardial edema) in apical inferior and adjacent fragment of the apical septal segment of the left ventricle (the arrow). **B.** sBTF cine imaging, 2-chamber view: transmuralsignal hyperintensity (myocardial edema) in the apical inferior segment of the left ventricle (the arrow). **C.** 4-chamber view: subendocardial distribution of late gadolinium enhancement (LGE) within the apical septal segment (the arrow). **D.** 4-chamber view: LGE within the apical inferior and apical septal segment (the arrow). **E.** Stress CMR with regadenoson, short-axis view: impaired subendocardial perfusion within the apical inferior and apical septal segment. Follow-up examination (the arrow). **F.** Follow-up examination, short axis view: subendocardial LGE within the apical inferior and apical septal segments of the left ventricle (post-myocardial scar; the arrow)

tation of targeted therapy and rehabilitation. It is estimated that more than one-third of MINOCA patients do not receive proper pharmacotherapy [3]. Our patient at first presented as typical TC, and her sex and history of emotional stress were major arguments for that. Female sex is a strong predictor of TC, accounting for the majority of points in the InterTAK score. However, some studies show that it is myocardial infarction, not TC, which constitutes the most frequent pathology in middle-aged women with MINOCA [4]. Another challenging problem is possible co-occurrence of myocardial infarction and TC, which has previously been described in the literature [5]. Therefore, each patient with MINOCA requires multimodality assessment, including early CMR and advanced coronary techniques (not performed in our case because of the presumption of TC).

Supplementary material

Supplementary material is available at https://journals.viamedica.pl/kardiologia_polska

Article information

Conflict of interest: None declared.

Funding: None.

Open access: This article is available in open access under Creative Commons Attribution-Non-Commercial-No Derivatives 4.0 Interna-

tional (CC BY-NC-ND 4.0) license, allowing to download articles and share them with others as long as they credit the authors and the publisher, but without permission to change them in any way or use them commercially. For commercial use, please contact the journal office at kardiologiapolska@ptkardio.pl.

REFERENCES

1. Agewall S, Beltrame JF, Reynolds HR, et al. ESC working group position paper on myocardial infarction with non-obstructive coronary arteries. *Eur Heart J.* 2017; 38(3): 143–153, doi: [10.1093/eurheartj/ehw149](https://doi.org/10.1093/eurheartj/ehw149), indexed in Pubmed: [28158518](https://pubmed.ncbi.nlm.nih.gov/28158518/).
2. Sörensson P, Ekenbäck C, Lundin M, et al. Early comprehensive cardiovascular magnetic resonance imaging in patients with myocardial infarction with nonobstructive coronary arteries. *JACC Cardiovasc Imaging.* 2021; 14(9): 1774–1783, doi: [10.1016/j.jcmg.2021.02.021](https://doi.org/10.1016/j.jcmg.2021.02.021), indexed in Pubmed: [33865778](https://pubmed.ncbi.nlm.nih.gov/33865778/).
3. Pitts R, Daugherty SL, Tang F, et al. Optimal secondary prevention medication use in acute myocardial infarction patients with nonobstructive coronary artery disease is modified by management strategy: insights from the TRIUMPH Registry. *Clin Cardiol.* 2017; 40(6): 347–355, doi: [10.1002/clc.22686](https://doi.org/10.1002/clc.22686), indexed in Pubmed: [28387960](https://pubmed.ncbi.nlm.nih.gov/28387960/).
4. Reynolds HR, Kwong RY, Maehara A, et al. Coronary optical coherence tomography and cardiac magnetic resonance imaging to determine underlying causes of myocardial infarction with nonobstructive coronary arteries in women. *Circulation.* 2021; 143(7): 624–640, doi: [10.1161/CIRCULATIONAHA.120.052008](https://doi.org/10.1161/CIRCULATIONAHA.120.052008), indexed in Pubmed: [33191769](https://pubmed.ncbi.nlm.nih.gov/33191769/).
5. Konishi T, Funayama N, Yamamoto T, et al. Acute anterior myocardial infarction complicated by takotsubo syndrome: the value of multimodality imaging. *Kardiol Pol.* 2020; 78(10): 1055–1056, doi: [10.33963/KP.15492](https://doi.org/10.33963/KP.15492), indexed in Pubmed: [32633477](https://pubmed.ncbi.nlm.nih.gov/32633477/).