

When Takayasu mimics pulmonary hypertension — severe pulmonary artery stenosis — what to do?

Mateusz Polak, Marek Grabka, Wojciech Wróbel, Iwona Woźniak-Skowarska, Katarzyna Mizia-Stec

1st Department of Cardiology, School of Medicine in Katowice, Medical University of Silesia, Katowice, Poland

Correspondence to:

Prof. Katarzyna Mizia-Stec,
MD, PhD,
1st Department of
Cardiology, School of
Medicine in Katowice,
Medical University of Silesia,
Ziołowa 47,
40–635 Katowice, Poland,
phone: +48 32 359 88 90,
e-mail:
kmiziaszec@gmail.com

Copyright by the Author(s),
2021

Kardiologia Polska. 2021;
79 (9): 1046–1047;
DOI: 10.33963/KPa2021.0059

Received:

June 13, 2021

Revision accepted:

July 8, 2021

Published online:

July 8, 2021

A 27-year-old female, without a history of cardiac diseases, with increasing fatigue and dyspnea, up to class IV of New York Heart Association (NYHA) during the previous two weeks, was admitted to the cardiology department with suspicion of pulmonary arterial hypertension (PAH).

On admission, the patient presented resting dyspnea, tachycardia 120 bpm, and blood pressure 100/60 mm Hg. Capillary blood oxygen saturation was 80%. A loud systolic murmur was present over the entire chest. Physical examination did not reveal peripheral edema nor features of venous thromboembolism in the lower extremities.

Laboratory tests revealed amino-terminal pro-brain natriuretic peptide of 10745 pg/ml ($n = 0–125$ pg/ml), increased inflammatory parameters (C-reactive protein 25 mg/l; white blood cells $13 \times 10^3/\mu\text{l}$), serum concentration of IgG4 of 60 mg/dl. Echocardiography showed the overload of the right ventricle, tricuspid annulus dilatation with torrential regurgitation. Calculated systolic pulmonary artery pressure was 110 mm Hg. Computed tomography angiography (angio-CT) scan revealed inflammatory infiltration of the pulmonary trunk, involving the pulmonary arteries and causing critical stenoses (Figure 1A–B). No embolic material was found on the scan.

Based on clinical and angiographic criteria proposed by the Japanese Research Committee on Vasculitis Syndromes [1], the initial diagnosis of Takayasu arteritis (TA) was stated. These criteria included: (1) angiographic evidence of narrowing or occlusion of the aorta or large arteries on CT or magnetic resonance imaging; (2) early age of onset; (3) presence of inflammatory markers; and (4) exclusion of atherosclerosis, other inflammatory diseases, or congenital vascular abnormalities.

The patient received 15 mg of prednisone per day and two intravenous infusions of 400 mg cyclophosphamide, achieving resolution of resting dyspnea. During the next 6 months, the patient received a total dose of 4.8 g cyclophosphamide and achieved total remission of clinical symptoms. Control angio-CT scan showed substantial regression of stenosis (Figure 1C–D). Figure 1E shows control parameters. Further hospitalizations were planned to perform imaging examinations and evaluate the effects of the treatment.

TA is a large-vessel vasculitis affecting the aorta and its primary branches: subclavian artery (33.7%), the renal artery (25.3%), and the common carotid artery (21.7%); the pulmonary artery comprised only 0.8%. Inflammatory processes in the acute phase cause thickening of the arterial wall. The chronic phase causes vascular fibrosis, stenosis, and occlusion, resulting in congestive heart failure and pulmonary hypertension [1].

We present a rare case of TA involving pulmonary arteries that clinically mimicked signs of severe PAH. Clinical presentation: age, sex, symptoms, amino-terminal pro-brain natriuretic peptide (NT-proBNP) level, and echocardiographic signs suggested PAH. Detailed echocardiographic assessment and the CT-scan allowed to reveal that the PAH-like features of right ventricular overload were due to severe pulmonary arteries stenosis. In the differential diagnosis, it was essential to exclude another inflammatory artery stenosis, mainly giant cell arteritis (GCA). While TA is seen in young females, GCA affects older patients. In GCA, inflammation processes often involve the external carotid artery, which is not seen in TA. Arterial wall thickening can be due to retroperitoneal fibrosis and therefore mimics TA, but TA lacks peritoneal diffusion [2]. IgG4 related

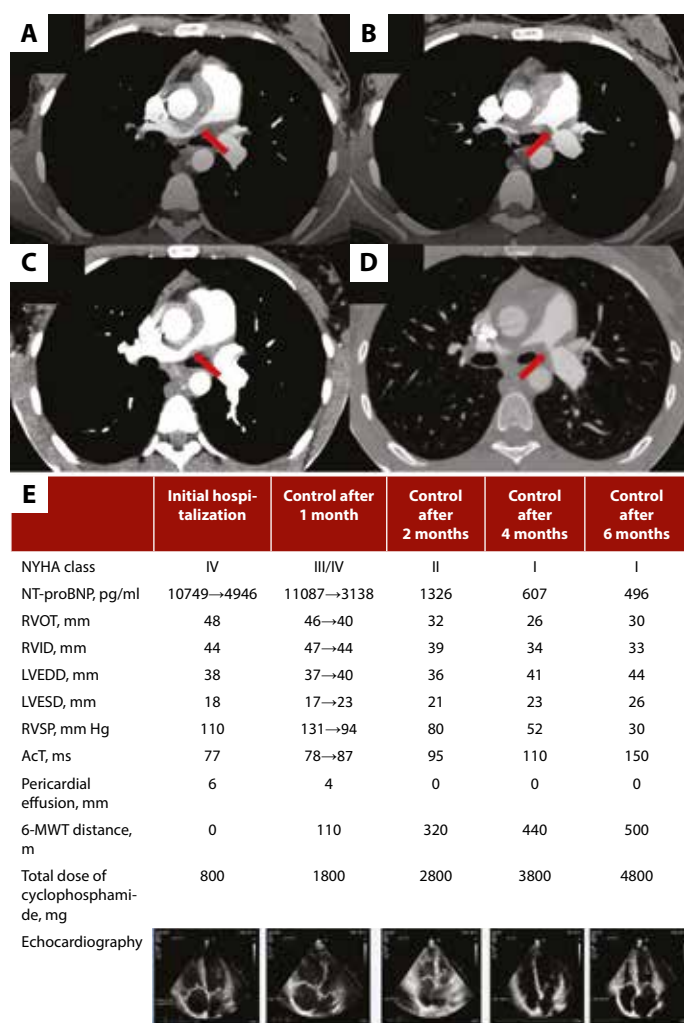


Figure 1. Contrast-enhanced computed tomography (CT). The initial angio-CT scan showed critical stenosis in pulmonary arteries, causing 99% narrowing of the lumen of the right pulmonary artery (RPA) (A, red arrow) and 95% of the left pulmonary artery (LPA) (B, red arrow). Control angio-CT scan after 6 months showed substantial regression of stenosis in both RPA (C, red arrow) and LPA (D, red arrow). E. Clinical, laboratory, and echocardiography parameters according to the total dose of cyclophosphamide in subsequent hospitalizations

Abbreviations: 6-MWT, 6-minute walking test; AcT, acceleration time; LVEDD, left ventricular end-diastolic diameter; LVESD, left ventricular end-systolic diameter; NT-proBNP, amino-terminal pro-brain natriuretic peptide; NYHA, New York Heart Association class; RVIT, right ventricular inflow tract; RVOT, right ventricular outflow tract; RVSP, right ventricular systolic pressure

disease was also taken into consideration. With a serum concentration of IgG4 of 60 mg/dl, it was unlikely (96% negative predictive value) [3].

The first line of treatment for TA is glucocorticoids. Half of the patients require second-line agents: cyclophosphamide, methotrexate, or biologic drugs [4]. Endovascular or surgical interventions in artery stenosis may be necessary once irreversible stenosis starts to develop. Since the rates of complications are the highest in patients with acute inflammatory lesions, interventional therapy should be avoided during the acute phase of the disease [5].

Article information

Conflict of interest: None declared.

Open access: This article is available in open access under Creative Commons Attribution-Non-Commercial-No Derivatives 4.0 International (CC BY-NC-ND 4.0) license, allowing to download articles and share them with others as long as they credit the authors and the publisher, but without permission to change them in any way or use them commercially. For commercial use, please contact the journal office at kardiologiapolska@ptkardio.pl.

How to cite: Polak M, Grabka M, Wróbel W, et al. When Takayasu mimics pulmonary hypertension — severe pulmonary artery stenosis — what to do? *Kardiol Pol.* 2021; 79(9): 1046–1047, doi: 10.33963/KP.a2021.0059.

REFERENCES

- Keser G, Aksu K, Direskeneli H. Takayasu arteritis: an update. *Turk J Med Sci.* 2018; 48(4): 681–697, doi: 10.3906/sag-1804-136, indexed in Pubmed: 30114347.
- Zhang YH, Song WM, Wu M, et al. Initial isolated Takayasu's arteritis of bilateral pulmonary artery branches. *Rev Bras Reumatol.* 2017; 57(6): 626–629, doi: 10.1016/j.rbr.2015.10.002, indexed in Pubmed: 26920538.
- Carruthers MN, Khosroshahi A, Augustin T, et al. The diagnostic utility of serum IgG4 concentrations in IgG4-related disease. *Ann Rheum Dis.* 2015; 74(1): 14–18, doi: 10.1136/annrheumdis-2013-204907, indexed in Pubmed: 24651618.
- Bartczak-Rutkowska A, Trojnarowska O, Cieplucha A, et al. Enlarging aneurysm of the ascending aorta in a pregnant woman with Takayasu arteritis. *Kardiol Pol.* 2020; 78(1): 82–83, doi: 10.33963/KP.15059, indexed in Pubmed: 31724561.
- Duan Y, Zhou X, Su H, et al. Balloon angioplasty or stent implantation for pulmonary vein stenosis caused by fibrosing mediastinitis: a systematic review. *Cardiovasc Diagn Ther.* 2019; 9(5): 520–528, doi: 10.21037/cdt.2019.09.14.