

Transcatheter closure of patent foramen ovale for the secondary prevention of decompression illness in professional divers: a single-centre experience with long-term follow-up

Jan Henzel¹, Piotr N. Rudziński¹, Mariusz Kłopotowski², Marek Konka³, Zofia Dzielińska¹, Marcin Demkow¹

¹Department of Coronary Artery Disease and Structural Heart Disease, Institute of Cardiology, Warsaw, Poland

²Department of Interventional Cardiology and Angiology, Institute of Cardiology, Warsaw, Poland

³Department of Congenital Cardiac Defects, Institute of Cardiology, Warsaw, Poland

Abstract

Background: Patent foramen ovale (PFO) with occasional right-to-left shunting is associated with an increased risk of decompression illness (DCI). Divers with a history of repetitive or severe DCI and diagnosed with PFO should be considered for transcatheter closure if they wish to continue with unrestricted diving.

Aim: To summarise our centre's experience in transcatheter PFO closure in professional divers with a history of DCI.

Methods: A follow-up of 11 consecutive divers (nine males, two females) in whom device PFO closure was performed between 2001 and 2015 was carried out by phone contact. Available medical records and diving logbooks were reviewed to determine individual DCI symptomatology, indications to the procedure, and to evaluate modifications in the diving practice.

Results: Each patient experienced at least one event of DCI before the procedure, and eight patients experienced more than one event. Total number of reported events was 62. The vast majority of events (97%) followed dives consistent with safe decompression policies. The median follow-up was 91 (minimum nine, maximum 172) months. No complications of the intervention were observed. All patients returned to unrestricted, deep diving, performing a total of 3610 dives with the median number of 225 dives (lower quartile value: 82.5 dives, upper quartile value: 725 dives). The majority of subjects dived as deep as they did before the intervention, or deeper, achieving mean maximum depth of 93.8 ± 35.6 m (vs. 89.7 ± 25.9 m before the intervention, $p = 0.71$). No episodes of DCI were reported during the follow-up period.

Conclusions: Transcatheter closure of PFO appears to be reasonably effective in secondary prevention of DCI associated with intra-cardiac shunting.

Key words: decompression illness, diving, patent foramen ovale (PFO), transcatheter closure

Kardiol Pol 2018; 76, 1: 153–157

INTRODUCTION

Decompression illness (DCI) encloses a variety of symptoms exerted by gas bubbles formed in the human body upon ascent and surfacing. As a result of changes in the ambient pressure, natural gas reservoirs such as fatty tissue, joint surfaces, skin pores, lungs, spine, inner ear, and sinuses liberate bubbles that increase in volume during the ascent, in accordance with Boyle's law. In some cases, the effect is exerted locally, limited to the nucleation sites and the adjacent tissues. A group of

DCI manifestations, however, is regarded as secondary to right-to-left shunting, when venous gas bubbles arterialise, i.e. manage to penetrate into the systemic circulation bypassing the pulmonary bed. A shunt may be present at the level of the pulmonary vessels or within the heart. Patent foramen ovale (PFO), a persistent communication in the interatrial septum, constitutes a possible pathway for the intracardiac shunting.

An association between certain forms of neurological or cutaneous manifestations of DCI and PFO has been estab-

Address for correspondence:

Jan Henzel, MD, Department of Coronary Artery Disease and Structural Heart Disease, Institute of Cardiology, ul. Alpejska 42, 04–628, Warszawa, Poland, e-mail: jhenzel@ikard.pl

Received: 01.06.2017

Accepted: 29.08.2017

Available as AoP: 20.09.2017

Kardiologia Polska Copyright © Polskie Towarzystwo Kardiologiczne 2018

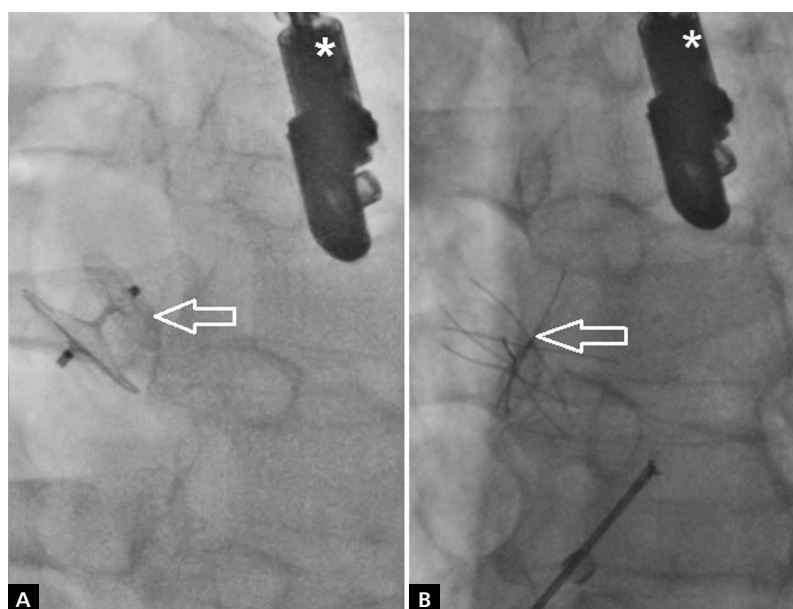


Figure 1. A. Angiography. Patent foramen ovale (PFO) closed with Amplatzer PFO Occluder, St. Jude Medical, 25 mm (arrow); **B.** Angiography. PFO closed with CARDIA PFO device, 30 mm (arrow); transoesophageal echocardiography probe was marked with an asterisk (*) in panel A and panel B

lished [1–6]. If bends occur after dives that were not provocative (commonly referred to as ‘undeserved’ DCI) [7] or have a tendency to recur, percutaneous closure of PFO should be considered to eliminate the probable precipitating factor.

This study aimed to summarise our experience in the field of device PFO closure in divers with the history of DCI. We carried out a long-term follow-up of all professional divers treated in our institution over the period 2001–2015. Detailed data on the symptoms of DCI were obtained. Individual indications to the procedure were carefully analysed in each subject. We also sought to evaluate the modifications in their diving practice and, most importantly, to determine the recurrence of DCI after the intervention.

METHODS

Eleven procedures of transcatheter PFO closure for the secondary prevention of DCI were performed in the Institute of Cardiology in Warsaw between 2001 and 2015. The presence of PFO with right-to-left shunting was diagnosed with contrast transoesophageal echocardiography (TEE) and the Valsalva manoeuvre, and confirmed during the intervention. All patients had significant right-to-left shunting during the manoeuvre (> 30 contrast bubbles). Each procedure was performed under general anaesthesia via femoral venous access. In 10 patients, PFO was closed with 25-mm Amplatzer™ PFO Occluder, St. Jude Medical, Inc. (Fig. 1A), and in one patient with 30-mm CARDIA PFO device, Cardia, Inc. (Fig. 1B).

Transthoracic echocardiography (TTE) was performed in all subjects within 24 h of the procedure, to confirm the

correct position of the occluder. Further follow-up visits at our site were accomplished in three subjects; two of them underwent repeat bubble contrast TEE examination, one of them — a TTE. Another five patients were consulted by their local cardiologists (all with TTE examinations). Three patients neglected the follow-up visits that they had been advised after the intervention.

All subjects (nine males, two females) were interviewed by phone in November 2015 using a dedicated questionnaire. Medical records and diving logbooks were reviewed to obtain accurate data.

The study was approved by the Local Bioethics Committee at the Institute of Cardiology in Warsaw, Poland (IK-NP-0021-72/1581/16).

RESULTS

Median follow-up was 91 (minimum nine, maximum 172) months. Average patient age at the day of procedure was 39 ± 6 years. All subjects were professional divers. Their diving practice included commercial underwater work, military expeditions, and/or dive instructing. Moreover, all subjects were dedicated to a number of recreational diving activities in their leisure time.

Arterial hypertension and asthma were the most prevalent co-morbidities, present in four and one patient(s), respectively. Four patients reported a history of smoking, and three patients suffered from migraine, one of those having attacks with aura.

Each patient experienced at least one event of DCI before the procedure, and eight patients experienced more

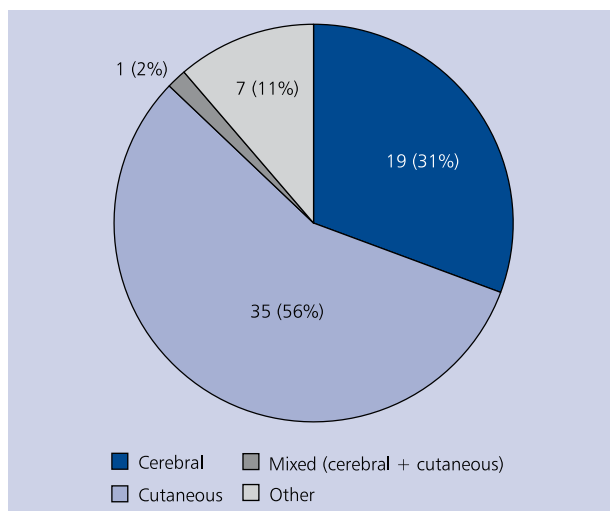


Figure 2. Forms of decompression illness events in the investigated group

than one event. The total number of reported events was 62, and the mean number of bends per patient was 5.6. The vast majority of events (97%) followed dives consistent with safe decompression policies, but three of these events (5%) were preceded by long, exhausting cave explorations that could be considered provocative.

Out of the 62 reported events, 19 (31%) occurred with various symptoms of cerebral DCI, whereas 35 (56%) were with cutaneous manifestations (Fig. 2). One (2%) episode was of mixed character. Among the cerebral symptoms, vertigo and dizziness prevailed. Syncope, hemiparesis and hemisensory loss were also frequently reported (for the full list of symptoms see Table 1). None of the patients developed permanent neurological deficit. No ischaemic foci in the central nervous system were captured by the neuroimaging techniques, performed in all subjects who presented with cerebral symptoms. The remaining seven (11%) events were manifested predominantly with musculoskeletal complaints, such as shoulder pain or painful limb oedema. None of the patients in our cohort experienced symptoms suggestive of spinal cord involvement (for example impaired bowel or bladder control); however, we cannot exclude that the reported cases of hemisensory loss or musculoskeletal complaints might have occurred with some spinal component.

In summary, each patient experienced at least one cerebral or one cutaneous event of DCI, which was regarded as the indication to the transcatheter PFO closure.

The onset of symptoms varied in time from shortly after surfacing to over 6 h. Four patients reported a quick onset (up to 30 min), another four patients reported the onset at 30–90 min, and two patients — at more than 90 min. One patient experienced events of both early and late onset. Un-

Table 1. Symptoms of decompression illness in the investigated group.

Symptom	Number of patients (n = 11)
Vertigo, dizziness	6
Skin rash	4
Musculoskeletal pain	4
Syncope	3
Hemiparesis	3
Hemisensory loss	3
Visual disturbances	2
Vomiting	2
Hearing impairment	2
Dyspnoea	2
Pruritus	1
Limb oedema	1
Anisocoria	1

fortunately, due to the applied methodology, the exact time was difficult to determine retrospectively, and the obtained data suggest some approximation.

After the procedure, no short-term complications including malposition and/or embolisation of the device were observed; significant residual leak was not found in any case. All patients returned to unrestricted, deep diving, performing a total of 3610 dives, according to the data declared in the phone survey. The median number of dives was 225 (lower quartile value: 82.5, upper quartile value: 725). To avoid possible bias, one subject was excluded from this part of the analysis because he was a skilled underwater worker whose diving practice involved the saturation technique (working dives lasting several days with one, extended decompression). This man declared to have spent about 10,000 h underwater after the procedure (see Table 2, position 1). What is important to underline, he was the only subject in our cohort who declared diving using this technique.

The median time period between the intervention and the next dive was four months (minimum five days, maximum one year). The majority of subjects (seven out of 11) managed to dive as deep as they did before the procedure, or deeper. No statistically significant difference between the maximum depths achieved before and after the intervention was observed (89.7 ± 25.9 vs. 93.8 ± 35.6 m, $p = 0.71$). Further details on the group characteristics are provided in Table 2.

Questions on the diving practice following the intervention were asked. Four patients changed their diving habits: three claimed to extend decompression stops, and one gave up long, exhausting cave explorations. Of note, each patient from this subgroup had experienced at least one episode of cerebral or cutaneous DCI after a completely safe ascent.

Table 2. Group characteristics

No.	Sex	Age [years]	No. of events before intervention	Observation time [months]	Occluder implanted	Time from intervention to next diving	No. of dives after intervention	Max. depth before intervention [m]	Max. depth after intervention [m]
1	Male	41	2	172	APFO 25	5 days	10,000*	70	160
2	Female	36	1	121	APFO 25	7 days	100	110	70
3	Male	35	3	115	APFO 25	9 months	300	55	60
4	Male	32	1	101	APFO 25	6 months	700	115	120
5	Male	44	1	99	CARDIA PFO 30	3 months	800	60	40
6	Female	35	18	91	APFO 25	1 year	30	100	70
7	Male	44	7	60	APFO 25	3 months	350	75	90
8	Male	40	3	60	APFO 25	4 months	150	80	102
9	Male	49	20	58	APFO 25	1 month	1,000	140	140
10	Male	30	3	40	APFO 25	4 months	150	80	100
11	Male	47	3	9	APFO 25	6 months	30	102	80

The asterisk (*) refers to the subject diving with saturation technique; the number represents total time from compression to complete decompression (in hours); APFO 25 — Amplatzer PFO Occluder 25 mm; CARDIA PFO 30 — CARDIA PFO Occluder 30 mm

Another four patients decided to dive shallower than they did before the procedure; those subjects achieved maximum depths of 40–80 m, which is still considered deep [8]. Only two patients gave up diving, both for reasons other than health issues (personal reasons and a psychological barrier). Prior to making this decision, they performed 100 and 30 dives, respectively (see Table 2, positions 2 and 6).

No episodes of DCI were observed after the intervention. Among the patients who had the TTE examination performed in the follow-up, no sonographic features of late complications, such as PFO recanalisation or occluder malposition, were revealed.

DISCUSSION

Along with the popularisation of diving activities, there is a growing interest in the association of DCI and PFO. PFO is present in 25–30% of the general population [9], and even though it is believed to increase the risk of DCI by about 2.5–5 fold [10, 11], the prevalence of the latter remains extremely low. Bove and Moon [12] have estimated the risk of an incident of DCI correlated with PFO by between 0.002% and 0.03% of dives.

Nevertheless, it should be highlighted that only a very small subset of divers with PFO will experience DCI, and therefore baseline PFO screening is not recommended as a standard procedure. Diagnostics should be reserved for suggestive cases. The most up-to-date guidelines define a number of such circumstances, as follows: a history of DCI with cerebral, spinal, vestibulocochlear or cutaneous manifestations, a history of migraine with aura, a history of cryptogenic stroke, and a history of PFO or atrial septal defect in a first-degree relative [13]. The

Undersea and Hyperbaric Medical Society (UHMS) states that PFO testing may be considered after severe or repetitive DCI [14]. In turn, as per Health and Safety Executive (HSE) recommendations addressed to professional divers, investigation for PFO should be performed in individuals who experienced neurological, cutaneous, or cardiorespiratory forms of decompression illness, particularly if they suffered from migraine with aura or if the diving profile was not contributory ('undeserved' DCI) [15].

In the case of a positive finding, transcatheter closure of PFO should be considered if the patient is unwilling to stop diving and/or if the profile of dives cannot be changed. In this study, we analysed professional divers who predominantly followed safe decompression rules (as few as 8% of events occurred after dives that could be regarded as provocative), and who were strongly determined to continue diving. Our results seem to support the hypothesis that device closure appears a reasonably effective strategy in such individuals.

In our cohort, each subject experienced at least one episode of cerebral or cutaneous DCI, none of which recurred after the intervention. Interestingly, seven events of different character, possibly independent of right-to-left shunting (i.e. non-cerebral, non-skin DCI) have also been reported, and these did not recur after the procedure either. It may be hypothesised that these complaints were not related to DCI and just coincided with it. In fact, shoulder pain reported by one patient developed relatively late (2–6 h after surfacing). Because the usual peak time for bubble liberation is assessed as 30–60 min post dive, late symptoms are unlikely to be related with a shunt [5]. Unfortunately, exact verification of the reported complaints is not possible without a neurological examination, which is a limitation of this study.

Another shortcoming is the accurate assessment of the residual shunt in just two of 11 subjects. According to the 'Joint position statement on PFO and diving' [13], a repeat bubble contrast echocardiogram is required to confirm the shunt closure before returning to diving. These guidelines, however, date back to 2015, when the last procedure in our cohort was already performed.

Luckily, no complications of the procedure were observed in the investigated group. Nevertheless, potential threats such as cardiac tamponade (occurring in 0.4–0.7%) [16, 17], major bleeding (occurring in 0.4%) [16], or device embolisation (occurring in 0.7%) [17] must be borne in mind when considering the intervention. Interestingly, if these rates are compared with the estimated risk of DCI attributed to PFO as shown previously [12], the benefit should justify the risk after about 100–200 dives, which is an obtainable feat in subjects diving regularly (see Table 2, column 7). In any case, device closure should be performed in an experienced centre with cardiac surgery back-up to minimise the risk of potential complications.

CONCLUSIONS

1. In divers with the history of DCI, PFO may be responsible for gas bubble arterialisation, and accurate diagnostics should be carried out in selected patients.
2. Transcatheter closure of PFO appears to be reasonably effective in secondary prevention of DCI associated with intra-cardiac shunting.
3. In subjects with a history of DCI and a strong desire to continue diving, transcatheter closure of PFO may enable the return to deep, unrestricted diving.

Acknowledgements

The authors would like to express their deep gratitude to Dr. Andrzej Kurowski, MD PhD for his contribution to the transcatheter interventions performed in patients enrolled in this study.

Conflict of interest: Marek Konka: proctoring for St. Jude Medical until 2016; Marcin Demkow: proctoring for St. Jude Medical.

References

1. Cantais E, Louge P, Suppini A, et al. Right-to-left shunt and risk of decompression illness with cochleovestibular and cerebral symptoms in divers: case control study in 101 consecutive dive accidents. *Crit Care Med*. 2003; 31(1): 84–88, doi: [10.1097/01.CCM.0000038040.42972.81](https://doi.org/10.1097/01.CCM.0000038040.42972.81), indexed in Pubmed: [12544998](https://pubmed.ncbi.nlm.nih.gov/12544998/).
2. Germonpré P, Dendale P, Unger P, et al. Patent foramen ovale and decompression sickness in sports divers. *J Appl Physiol*. 1998; 84(5): 1622–1626, indexed in Pubmed: [9572808](https://pubmed.ncbi.nlm.nih.gov/9572808/).
3. Germonpre P, Balestra C, Obeid G, et al. Cutis Marmorata skin decompression sickness is a manifestation of brainstem bubble embolization, not of local skin bubbles. *Med Hypotheses*. 2015; 85(6): 863–869, doi: [10.1016/j.mehy.2015.09.022](https://doi.org/10.1016/j.mehy.2015.09.022), indexed in Pubmed: [26432631](https://pubmed.ncbi.nlm.nih.gov/26432631/).
4. Wilmshurst PT, Byrne JC, Webb-Peploe MM. Relation between interatrial shunts and decompression sickness in divers. *Diving Hyperb Med*. 2015; 45: 129–131.
5. Wilmshurst PT. Cutis marmorata and cerebral arterial gas embolism. *Diving Hyperb Med*. 2015; 45(4): 261, indexed in Pubmed: [26687315](https://pubmed.ncbi.nlm.nih.gov/26687315/).
6. Wilmshurst PT. The role of persistent foramen ovale and other shunts in decompression illness. *Diving Hyperb Med*. 2015; 45(2): 98–104, indexed in Pubmed: [26165532](https://pubmed.ncbi.nlm.nih.gov/26165532/).
7. Vann RD, Butler FK, Mitchell SJ, et al. Decompression illness. *Lancet*. 2011; 377(9760): 153–164, doi: [10.1016/S0140-6736\(10\)61085-9](https://doi.org/10.1016/S0140-6736(10)61085-9), indexed in Pubmed: [21215883](https://pubmed.ncbi.nlm.nih.gov/21215883/).
8. Schwerzmann M, Seiler C. Recreational scuba diving, patent foramen ovale and their associated risks. *Swiss Med Wkly*. 2001; 131(25-26): 365–374, doi: [2001/25/smw-09706](https://doi.org/2001/25/smw-09706), indexed in Pubmed: [11524902](https://pubmed.ncbi.nlm.nih.gov/11524902/).
9. Hagen PT, Scholz DG, Edwards WD. Incidence and size of patent foramen ovale during the first 10 decades of life: an autopsy study of 965 normal hearts. *Mayo Clin Proc*. 1984; 59(1): 17–20, indexed in Pubmed: [6694427](https://pubmed.ncbi.nlm.nih.gov/6694427/).
10. Bove AA. Risk of decompression sickness with patent foramen ovale. *Undersea Hyperb Med*. 1998; 25: 175–178.
11. Torti SR, Billinger M, Schwerzmann M, et al. Risk of decompression illness among 230 divers in relation to the presence and size of patent foramen ovale. *Eur Heart J*. 2004; 25(12): 1014–1020, doi: [10.1016/j.ehj.2004.04.028](https://doi.org/10.1016/j.ehj.2004.04.028), indexed in Pubmed: [15191771](https://pubmed.ncbi.nlm.nih.gov/15191771/).
12. Bove AA, Moon RE. Patent foramen ovale – is it important to divers? www.diversalertnetwork/medical/articles/Patent_Forum_Ovale_Is_It_Important_To_Divers.
13. Smart D, Mitchell S, Wilmshurst PT, et al. Joint position statement on persistent foramen ovale (PFO) and diving. *Diving Hyperb Med*. 2015; 45: 129–131.
14. Undersea and Hyperbaric Medical Society. UHMS best practice guidelines: prevention and treatment of decompression sickness and arterial gas embolism. http://membership.uhms.org/resource/resmgr/dcsandage_prevandmgt_uhms-fi.pdf.
15. The medical examination and assessment of divers (MAI). <http://www.hse.gov.uk/pubns/ma1.pdf>.
16. Carroll JD, Saver JL, Thaler DE, et al. Closure of patent foramen ovale versus medical therapy after cryptogenic stroke. *N Engl J Med*. 2013; 368(12): 1092–1100, doi: [10.1056/NEJMoa1301440](https://doi.org/10.1056/NEJMoa1301440), indexed in Pubmed: [23514286](https://pubmed.ncbi.nlm.nih.gov/23514286/).
17. National Institute for Health and Care Excellence. NICE interventional procedure guidance – percutaneous closure of patent foramen ovale for the secondary prevention of recurrent paradoxical embolism in divers. <http://guidance.nice.org.uk/IPG371> (IPG371 December 2010).

Cite this article as: Henzel J, Rudziński PN, Kłopotowski M, et al. Transcatheter closure of patent foramen ovale for the secondary prevention of decompression illness in professional divers: a single-centre experience with long-term follow-up. *Kardiol Pol*. 2018; 76(1): 153–157, doi: [10.5603/KPa.2017.0182](https://doi.org/10.5603/KPa.2017.0182).